

## COURSE GUIDE

### NSC 216 HUMAN ANATOMY III

**Course Team** (Course Writers)  
Dr. Adewole O.S. MBBS, PhD, (Associate Professor).  
Dr. Abiodun A. O. MBBS, FWCS, M.Sc. (Senior Lecturer)  
Dr. Ayannuga A. A. MBBS, Ph.D (Senior Lecturer)  
Dr. Adeyemi D.A. PhD (Senior Lecturer)  
Dr. Ojo S. K. MBChB, MSc (Lecturer II);  
Dr. Arayombo B. E. MBChB, MSc (Lecturer II)  
Department of Anatomy and Cell Biology, College of Health Sciences,  
Obafemi Awolowo University, Ile-Ife, Nigeria  
Course Facilitators:  
  
Dr O.O. Irinoye and Dr E.O Oladogba (Course Editors)  
Professor Mba Okoronkwo OON (Programme Leader)  
Dr S S Bello MBBS, PhD (Course Reviewer)  
Department of Anatomy, FBMS, College of Health Sciences, Usmanu Danfodiyo University, Sokoto, Nigeria



**NATIONAL OPEN UNIVERSITY OF NIGERIA**

© 2021 by NOUN Press  
National Open University of Nigeria  
Headquarters  
University Village  
Plot 91, Cadastral Zone  
Nnamdi Azikiwe Expressway  
Jabi, Abuja

Lagos Office  
14/16 Ahmadu Bello Way  
Victoria Island, Lagos  
e-mail: [centralinfo@nou.edu.ng](mailto:centralinfo@nou.edu.ng)  
URL: [www.nou.edu.ng](http://www.nou.edu.ng)

All rights reserved. No part of this book may be reproduced, in any form or by any means, without exclusive permission in writing from the publisher.

Published by:

Printed by NOUN Press [np@nou.edu.ng](mailto:np@nou.edu.ng)

ISBN:

<b>CONTENTS</b>	<b>PAGE</b>
General Introduction.....	iv
Course Aims.....	iv
Course Objectives.....	iv
Working through the Course.....	iv
Course Materials.....	v
Study Units.....	v
Reference Textbooks.....	v
Equipment and Software Needed to Access Course.....	vii
Number and Places of Meeting.....	vii
Discussion Forum.....	vii
Course Evaluation.....	viii
Grading Criteria.....	viii
Grading Scale.....	viii
Schedule of Assignments with Dates.....	ix
Course Overview.....	ix
How to get the most from this Course.....	ix

## **GENERAL INTRODUCTION**

Congratulation on successful completion of the first semester courses, NSC 215, Human Anatomy I and NSC 221, the precursors of the current course. Welcome to the second semester course in Human Anatomy, NSC 216 – Human Anatomy III. This is a second semester course and a continuation of Human Anatomy I (NSC 215) where you have increased/improved your knowledge about the basic body structures and their organizations. You also covered the protective covering of all the body organs as well as the supporting systems. This second part will cover other internal organs that are important to maintenance of life. As indicated in NSC 205, caring always require sound understanding of the normal structure of the body organs as to know what such manifest could be wrong and how. Basic assessments done before planning general and nursing care usually consider the various organs that function within systems and as interrelated systems. You will be required to be able to describe the various organs and discuss the clinical correlates of the knowledge of the body parts. You will enjoy drawing and labelling, as well as seeing some of these organs in real life. You will also see the variations in normal and diseased organs as you are encouraged to participate in all laboratory assignments.

## **COURSE AIM**

The aim of this course is further your understanding of the structural make up of four of the life supporting systems as such prepares you to apply your knowledge in planning to meet the care needs of your body and that of your clients as such may relate to normal and abnormal changes in the various organs that make up the systems.

## **COURSE OBJECTIVES**

At the completion of this course, you should be able to:

- i. Discuss the structure, relations, embryology and histology of the organs in the following systems:
  - a. The cardiovascular system
  - b. The respiratory
  - c. The digestive system

## **WORKING THROUGH THIS COURSE**

The course will be delivered adopting the blended learning mode, 70% of online but interactive sessions and 30% of face-to-face during laboratory sessions. You are expected to register for this course online before you can have access to all the materials and have access to the

class sessions online. You will have the hard and soft copies of course materials, you will also have online interactive sessions, face-to-face sessions with instructors during practical sessions in the laboratory. The interactive online activities will be available to you on the course link on the Website of NOUN. There are activities and assignments online for every unit every week. It is important that you visit the course sites weekly and do all assignments to meet deadlines and to contribute to the topical issues that would be raised for everyone's contribution. You will be expected to read every module along with all assigned readings to prepare you to have meaningful contributions to all sessions and to complete all activities. It is important that you attempt all the Self-Assessment Questions (SAQ) at the end of every unit to help your understanding of the contents and to help you prepare for the in-course tests and the final examination. You will also be expected to keep a portfolio where you keep all your completed assignments.

## STUDY UNITS

This course comprises 3 Modules and 10 units. They are structured as presented:

### **Module 1    Cardiovascular System**

- Unit 1        Heart and Blood Vessels
- Unit 2        Blood
- Unit 3        Lymphatic System

### **Module 2    Respiratory System**

- Unit 1        Anatomy of the lungs
- Unit 2        Developmental anatomy of the lungs
- Unit 3        Anatomy of the diaphragm and mediastinum

### **Module 3    Digestive system**

- Unit 1        Anatomy of the Stomach
- Unit 2        Anatomy of the Small Intestine
- Unit 3        Anatomy of the Large Intestine
- Unit 4        Other Accessory Organs of Digestion

## REFERENCE TEXTBOOKS

Sadler T.W (2012), Langman's Medical Embryology 12th edition.

Philip Tate (2012) Seeley's Principles of Anatomy & Physiology 2nd edition.

Katherine M. A. Rogers and William N. Scott (2011) Nurses! Test yourself in anatomy and physiology

Kent M. Van De Graff, R.Ward Rhees, Sidney Palmer (2013) Schaum's Outline of Human Anatomy and Physiology 4th edition.

Kathryn A. Booth, Terri. D. Wyman (2008) Anatomy, physiology, and pathophysiology for allied health

Keith L Moore, Persuade T.V.N (2018), The Developing Human Clinically Oriented Embryology 11th Edition Lippincott Williams & Wilkins.

## **COURSE REQUIREMENTS AND EXPECTATIONS OF YOU**

Attendance of 95% of all interactive sessions, submission of all assignments to meet deadlines; participation in all CMA, attendance of all laboratory sessions with evidence as provided in the log book, submission of reports from all laboratory practical sessions and attendance of the final course examination. You are also expected to:

1. Be versatile in basic computer skills
2. Participate in all laboratories practical up to 90% of the time
3. Submit personal reports from laboratory practical sessions on schedule
4. Log in to the class online discussion board at least once a week and contribute to ongoing discussions.
5. Contribute actively to group seminar presentations.

## **EQUIPMENT AND SOFTWARE NEEDED TO ACCESS COURSE**

You will be expected to have the following tools:

1. A computer (laptop or desktop or a tablet)
2. Internet access, preferably broadband rather than dial-up access
3. MS Office software – Word PROCESSOR, Powerpoint, Spreadsheet
4. Browser – Preferably Internet Explorer, Moxilla Firefox
5. Adobe Acrobat Reader

## **NUMBER AND PLACES OF MEETING (ONLINE, FACE-TO-FACE, LABORATORY PRACTICALS)**

The details of these will be provided to you at the time of commencement of this course

## **DISCUSSION FORUM**

There will be an online discussion forum and topics for discussion will be available for your contributions. It is mandatory that you participate in every discussion every week as will be moderated by your facilitator. Your participation links you, your face, your ideas and views to that of every member of the class and earns you some mark

## COURSE EVALUATION

There are two forms of evaluation of the progress you are making in this course. The first are the series of activities, assignments and end of unit, computer or tutor marked assignments, and laboratory practical sessions and report that constitute the continuous assessment that all carry 30% of the total mark. The second is a written examination with multiple choice, short answers and essay questions that take 70% of the total mark that you will do on completion of the course.

Students evaluation: The students will be assessed and evaluated based on the following criteria

- **In-Course Examination:** In-course examination will come up in the middle of the semester. These would come in form of Computer Marked Assignment. This will be in addition to one compulsory Tutor Marked Assignment (TMA's) and three Computer Marked Assignment that comes after the modules.
- **Laboratory practical:** Attendance, record of participation and other assignments will be graded and added to the other scores from other forms of examinations.
- **Final Examination:** The final written examination will come up at the end of the semester comprising essay and objective questions covering all the contents covered in the course. The final examination will amount to 60% of the total grade for the course.

## LEARNER-FACILITATOR EVALUATION OF THE COURSE

This will be done through group review, written assessment of learning (theory and laboratory practical) by you and the facilitators.

## GRADING CRITERIA

Grades will be based on the following Percentages

Tutor Marked Individual Assignments	10%	} 30%
Computer marked Assignment	10%	
Group assignment	5%	
Discussion Topic participation	5%	
Laboratory practical		} 10%
End of Course examination		70%



## **GRADING SCALE**

A = 70-100

B = 60 - 69

C = 50 - 59

F = < 49

## **SCHEDULE OF ASSIGNMENTS WITH DATES**

Every Unit has activity that must be done by you as spelt out in your course materials. In addition to this, specific assignment will also be provided for each module by the facilitator.

## **SPECIFIC READING ASSIGNMENTS**

To be provided by each module

## **COURSE OVERVIEW**

Human Anatomy (III) is the second of three courses that covers the major organs that are responsible for life. In this course, four main systems that are responsible for the maintenance of the body will be covered. The structures and locations of the various organs that make each of the systems will be studied. These are the cardiovascular, respiratory and digestive systems.

The course has the theory and laboratory components that spread over 15 weeks. The course is presented in Modules with small units. Each unit is presented to follow the same pattern that guides your learning. Each module and unit have the learning objectives that helps you track what to learn and what you should be able to do after completion. Small units of contents will be presented every week with guidelines of what you should do to enhance knowledge retention as had been laid out in the course materials. Practical sessions will be negotiated online with you as desirable with information about venue, date and title of practical session.

## **HOW TO GET THE MOST FROM THIS COURSE**

1. Read and understand the context of this course by reading through this course guide paying attention to details. You must know the requirements before you will do well.
2. Develop a study plan for yourself.
3. Follow instructions about registration and master expectations in terms of reading, participation in discussion forum, end of unit

and module assignments, laboratory practical and other directives given by the course coordinator, facilitators and tutors.

4. Read your course texts and other reference textbooks.
5. Listen to audio files, watch the video clips and consult websites when given.
6. Participate actively in online discussion forum and make sure you are in touch with your study group and your course coordinator.
7. Submit your assignments as at when due.
8. Work ahead of the interactive sessions.
9. Work through your assignments when returned to you and do not wait until when examination is approaching before resolving any challenge you have with any unit or any topic.
10. Keep in touch with your study centre, the NOUN, School of Health Sciences websites as information will be provided continuously on these sites.
11. Be optimistic about doing well.



**MAIN  
COURSE**

<b>CONTENT</b>		<b>PAGE</b>
<b>Module 1</b>	<b>Cardiovascular System.....</b>	<b>1</b>
Unit 1	Heart and Blood Vessels.....	1
Unit 2	Blood .....	36
Unit 3	Lymphatic System.....	53
<b>Module 2</b>	<b>Respiratory System.....</b>	<b>63</b>
Unit 1	Anatomy of the lungs .....	63
Unit 2	Developmental anatomy of the lungs.....	79
Unit 3	Anatomy of the diaphragm and Mediastinum.....	90
<b>Module 3</b>	<b>Digestive system.....</b>	<b>97</b>
Unit 1	Anatomy of the Stomach.....	97
Unit 2	Anatomy of the Small Intestine.....	112
Unit 3	Anatomy of the Large Intestine.....	126
Unit 4	Other Accessory Organs of Digestion.....	139

## **MODULE 1      CARDIOVASULAR SYSTEM**

### **Introduction**

Most buildings in this century have a water pump system installed which comprises the pumping machine, the pipes that distribute water to the different parts of the building and the control valves that regulates the flow. So, you can liken the water pump system to the cardiovascular system with the pipes being the vessels, the pumping machine being the heart and the valves, well, being the valves. The heart is a biological pump that works with miles of blood vessels to supply nutrients, oxygen and also take wastes away to other systems for disposal. In this module, we would cover the structures of the various organs that make up the cardiovascular system.

### **Module Objectives**

At the end of this module, you should be able to:

- i. Discuss the structures of the various organs that make up the cardiovascular system

### **CONTENT**

Unit 1	Heart and Blood Vessels
Unit 2	Blood
Unit 3	Lymphatic System

## **UNIT 1      THE HEART AND BLOOD VESSELS**

### **CONTENT**

1.0	Introduction
2.0	Objectives
3.0	Main Content
3.1	Pericardium
3.2	Gross anatomy of the heart
3.3	Developmental and microanatomy of the heart
3.4	Developmental and microanatomy of the great vessels
4.0	Conclusion
5.0	Summary
6.0	Tutor Marked Assignments
7.0	References

## 1.0 INTRODUCTION

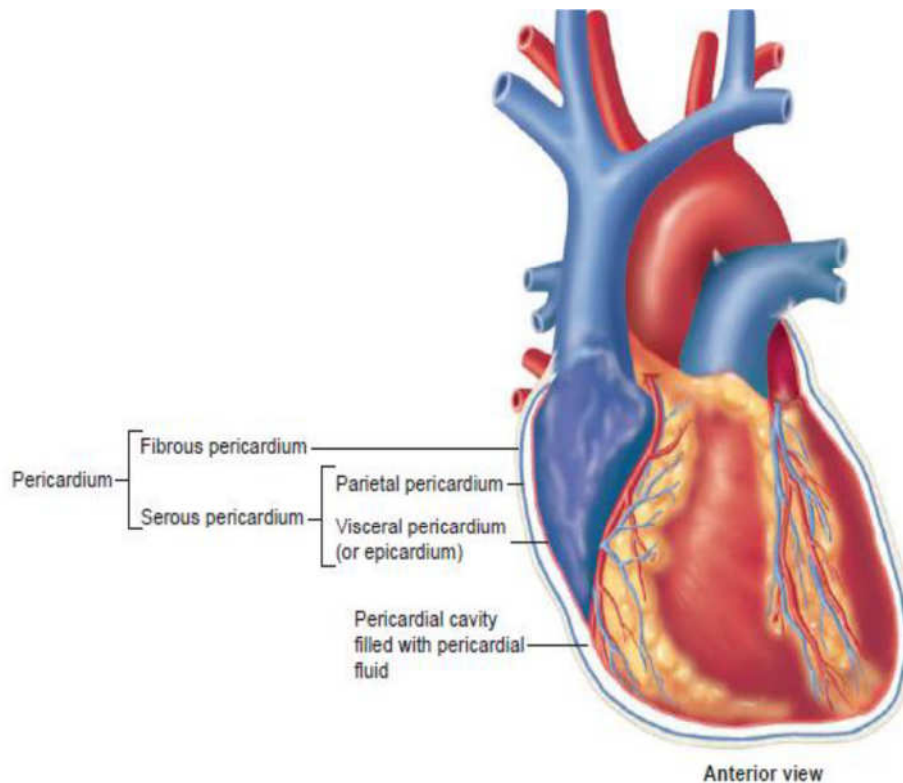
People always talk about the heart as the seat of control of emotions. At one stage or the other in your life, you must have fallen in love or had a broken heart. People often refer to the heart as if it were the seat of certain strong emotions. A very determined person may be described as having “a lot of heart”, and a person who has been disappointed romantically can be described as having a “broken heart”. A popular holiday in February not only dramatically distorts the heart’s anatomy but also attaches romantic emotions to it. One important reference, however about the heart is that “without a functioning heart, there is no life”. The heart is a muscular organ that is essential for life because it pumps blood through the body. Emotions are a product of brain function, not heart function but without the heart performing its functions efficiently, brain cells die within a short time! In this unit your knowledge of the structures and the organs in relations to the heart will be explored.

## 2.0 OBJECTIVES

At the end of this unit, you should be able to

- Describe the location, size and shape of the heart
- Highlight the functions of the heart
- List the parts and functions of the pericardium
- Contrast the three *layers of the heart wall* with respect to structure and function
- With the aid of a well labeled diagram, describe the position of the heart
- With the aid of a well labeled diagram, describe the pathway for the flow of blood through the heart chambers and large vessels associated with the heart
- Describe the vasculature of the heart with the aid of a diagram
- Describe structural variations in some abnormalities of the heart and the vessels.
- Explain what happens in pericardial effusion and pericarditis

### 3.1 The Pericardium



The pericardium is a protective sheath that encloses the heart, it has two parts: the fibrous pericardium and the serous pericardium.

**Figure 1.1: The Heart and the Coverings**

#### Fibrous pericardium

The pericardium has an outer single-layered fibrous sac that encloses the heart and the roots of the great vessels, fusing with the adventitia of these vessels. Its broad base overlies the central tendon of the diaphragm, with which it is inseparably blended, both being derived from the septum transversum.

The phrenic nerves lie on the surface of the fibrous pericardium and the mediastinal pleura is adherent to it, wherever the two membranes are in contact with each other. The fibrous pericardium is connected to the back of the sternum by weak sternopericardial ligaments.

#### Serous pericardium

A serous layer lines the inside of the fibrous pericardium, where it is reflected around the roots of the great vessels to cover the entire surface of the heart, where it forms the **epicardium**.

Between these parietal and visceral layers there are **two sinuses: the transverse sinus and the oblique sinus** of the pericardium.

The transverse sinus is a passage above the heart, between the ascending aorta and pulmonary trunk in front and the superior vena cava, left atrium and pulmonary veins behind. The oblique sinus is a space behind the heart, between the left atrium in front and the fibrous pericardium behind, posterior to which lies the oesophagus. A hand passed from below easily enters the oblique sinus, but the fingertips can only pass up as far as a double fold of serous pericardium that separates the oblique and transverse sinuses from each other.

It is through the transverse sinus that a temporary ligature is passed to occlude pulmonary trunk and aorta during pulmonary embolectomy and cardiac operations.

### **Nerve supply**

The fibrous pericardium is supplied by the phrenic nerve. The parietal layer of serous pericardium that lines it is similarly innervated, but the visceral layer on the heart surface is insensitive. Pain from the heart (angina) originates in the muscle or the vessels and is transmitted by sympathetic nerves. The pain of pericarditis originates in the parietal layer only, and is transmitted by the phrenic nerve.

### **Blood supply**

Pericardial blood supply is derived from the internal thoracic artery, its pericardiophrenic and musculophrenic branches, bronchial arteries and the thoracic aorta. The veins drain into the azygos system.

### **Pericardial drainage**

A needle inserted in the angle between the xiphoid process and the left seventh costal cartilage and directed upwards at an angle of 45, towards the left shoulder, passes through the central tendon of the diaphragm into the pericardial cavity. The creation of a small pericardial window surgically through the same route, or through the anterior end of the fourth intercostal space, provides more effective drainage.





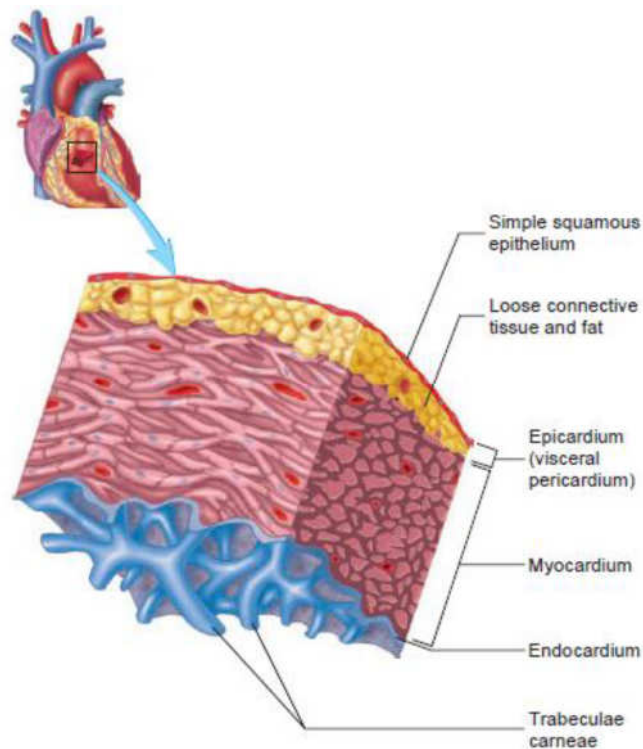
### Chambers of the heart

The heart has **four chambers**: right and left atria and right and left ventricles. The atria are receiving chambers that pump blood into the ventricles (the discharging chambers). The synchronous pumping actions of the heart's two atrioventricular (AV) pumps (right and left chambers) constitute the cardiac cycle. The cycle begins with a period of ventricular elongation and filling (diastole) and ends with a period of ventricular shortening and emptying (systole).

Two heart sounds are heard with a stethoscope: a lub (1st) sound as the blood is transferred from the atria into the ventricles and a dub (2nd) sound as the ventricles expel blood from the heart. The heart sounds are produced by the snapping shut of the one-way valves that normally keep blood from flowing backward during contractions of the heart.

The wall of each heart chamber consists of three layers, from superficial to deep:

- Endocardium, a thin internal layer (endothelium and subendothelial connective tissue) or lining membrane of the heart that also covers its valves.
- Myocardium, a thick, helical middle layer composed of cardiac muscle.
- Epicardium, a thin external layer (mesothelium) formed by the visceral layer of serous pericardium.

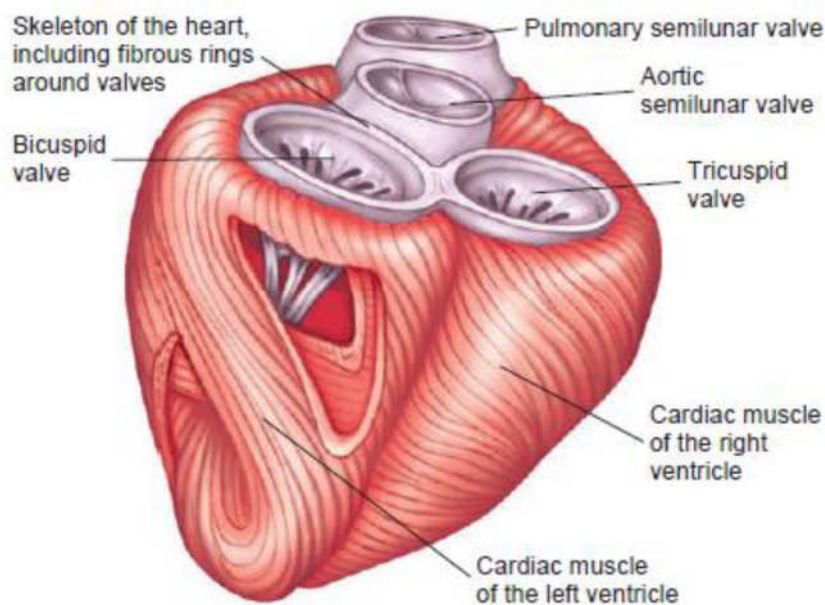


**Fig. 1.3: Wall of the heart**

## Contraction of the heart

The walls of the heart consist mostly of myocardium, especially in the ventricles. When the ventricles contract, they produce a wringing motion because of the double helical orientation of the cardiac muscle fibers. This motion initially ejects the blood from the ventricles as the outer (basal) spiral contracts, first narrowing and then shortening the heart, reducing the volume of the ventricular chambers. Continued sequential contraction of the inner (apical) spiral elongates the heart, followed by widening as the myocardium briefly relaxes, increasing the volume of the chambers to draw blood from the atria.

The muscle fibers are anchored to the fibrous skeleton of the heart. This is a complex framework of dense collagen forming four fibrous rings (L. anulifibrosi) that surround the orifices of the valves, a right and left fibrous trigone (formed by connections between rings), and the membranous parts of the interatrial and interventricular septa.



**Fig.1.4:** The Musculation and Valves of the Heart

The fibrous skeleton of the heart:

- i. Keeps the orifices of the AV and semilunar valves patent and prevents them from being overly distended by an increased volume of blood pumping through them.
- ii. Provides attachments for the leaflets and cusps of the valves.
- iii. Provides attachment for the myocardium, which, when uncoiled, forms a continuous ventricular myocardial band that originates

primarily from the fibrous ring of the pulmonary valve and inserts primarily into the fibrous ring of the aortic valve.

- iv. Forms an electrical insulator, by separating the myenterically conducted impulses of the atria and ventricles so that they contract independently and by surrounding and providing passage for the initial part of the AV bundle of the conducting system of the heart (discussed later in this chapter).

### **Demarcations**

Externally, the atria are demarcated from the ventricles by the coronary sulcus (atrioventricular groove), and the right and left ventricles are demarcated from each other by anterior and posterior interventricular (IV) sulci (grooves). The heart appears trapezoidal from an anterior or posterior view, but in three dimensions it is shaped like a tipped-over pyramid with its apex (directed anteriorly and to the left), a base (opposite the apex, facing mostly posteriorly), and four sides.

**The apex of the heart:**

- Is formed by the inferolateral part of the left ventricle.
- Lies posterior to the left 5th intercostal space in adults, usually approximately 9 cm (a hand's breadth) from the median plane.
- Remains motionless throughout the cardiac cycle.
- Is where the sounds of mitral valve closure are maximal (apex beat); the apex underlies the site where the heartbeat may be auscultated on the thoracic wall.

**The base of the heart:**

- Is the heart's posterior aspect (opposite the apex).
- Is formed mainly by the left atrium, with a lesser contribution by the right atrium.
- Faces posteriorly toward the bodies of vertebrae T6-T9 and is separated from them by the pericardium, oblique pericardial sinus, esophagus, and aorta.
- Extends superiorly to the bifurcation of the pulmonary trunk and inferiorly to the coronary sulcus.
- Receives the pulmonary veins on the right and left sides of its left atrial portion and the superior and inferior venae cavae at the superior and inferior ends of its right atrial portion.

**The four surfaces of the heart are the:**

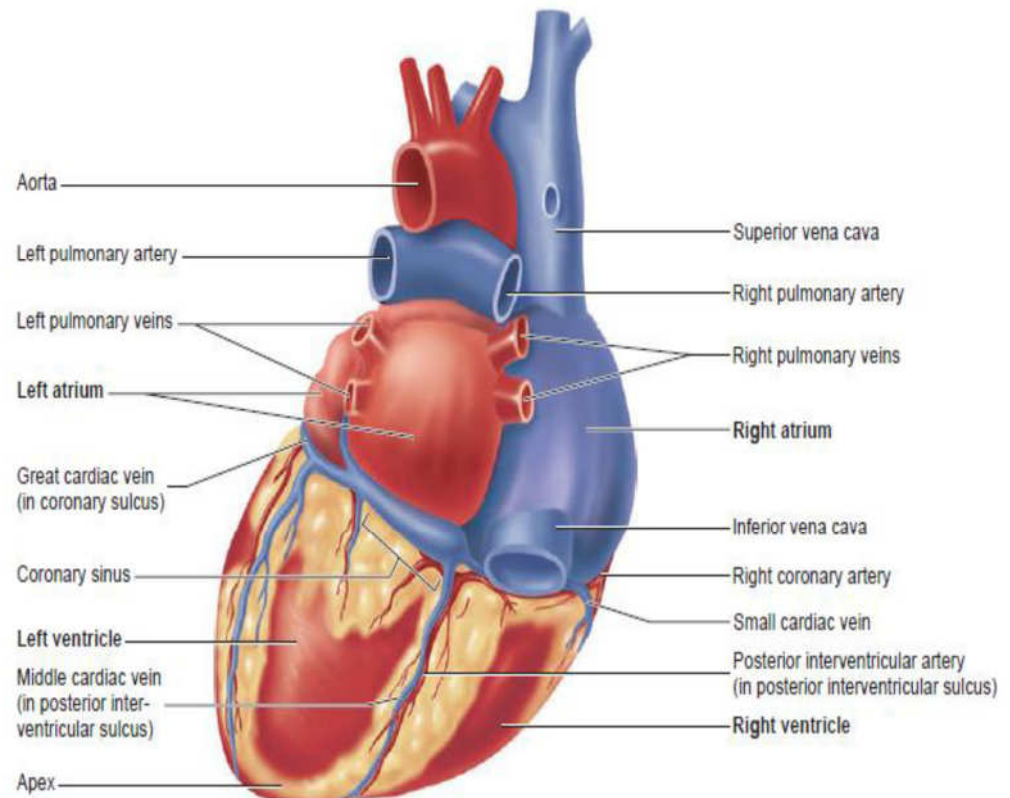
- Anterior (sternocostal) surface, formed mainly by the right ventricle.
- Diaphragmatic (inferior) surface, formed mainly by the left ventricle and partly by the right ventricle; it is related mainly to the central tendon of the diaphragm.
- Right pulmonary surface, formed mainly by the right atrium.
- Left pulmonary surface, formed mainly by the left ventricle; it forms the cardiac impression in the left lung.  
The heart appears trapezoidal in both anterior and posterior views.

**The four borders of the heart are the:**

- Right border (slightly convex), formed by the right atrium and extending between the SVC and the IVC.
- Inferior border (nearly horizontal), formed mainly by the right ventricle and slightly by the left ventricle.

- Left border (oblique, nearly vertical), formed mainly by the left ventricle and slightly by the left auricle.
- Superior border formed by the right and left atria and auricles in an anterior view; the ascending aorta and pulmonary trunk emerge from this border and the SVC enters its right side. Posterior to the aorta and pulmonary trunk and anterior to the SVC, this border forms the inferior boundary of the transverse pericardial sinus.

The pulmonary trunk, approximately 5 cm long and 3 cm wide, is the arterial continuation of the right ventricle and divides into right and left pulmonary arteries. The pulmonary trunk and arteries conduct low-oxygen blood to the lungs for oxygenation.



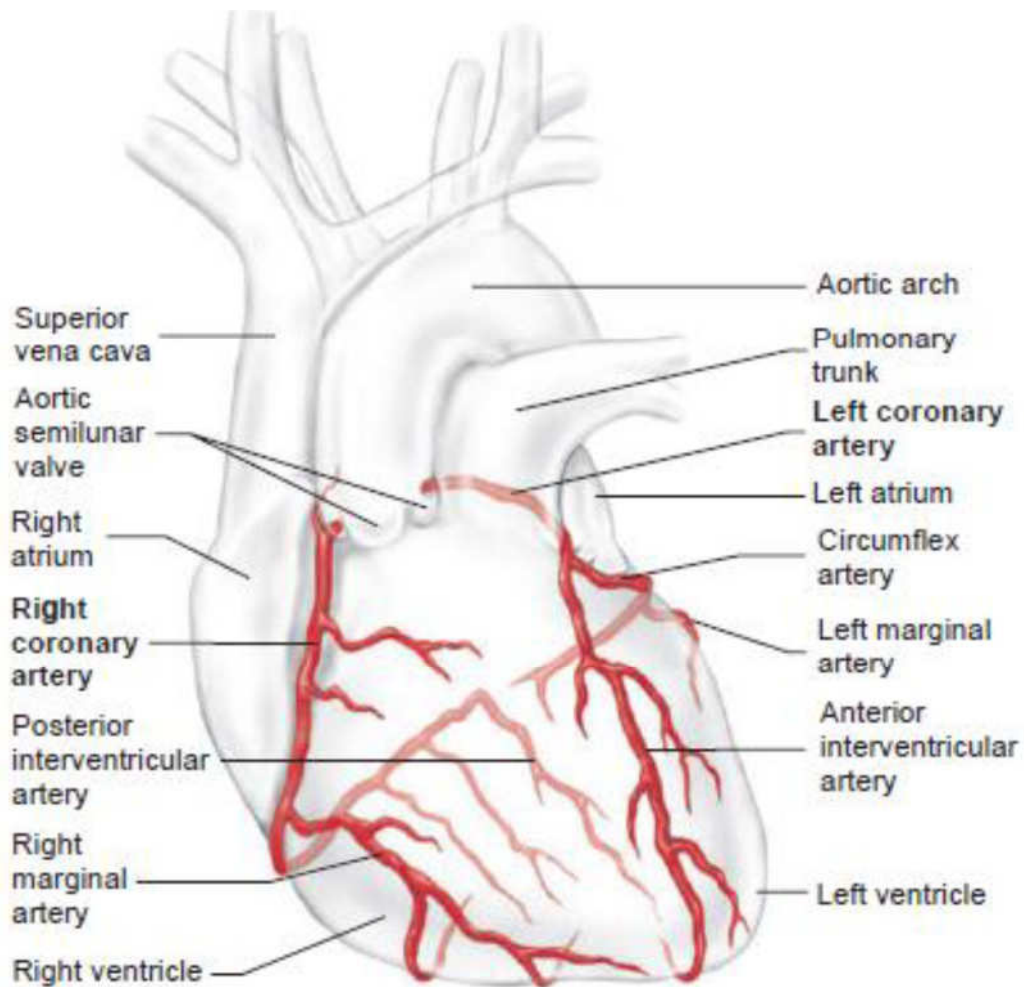
**Figure 1.5: The Posterior View of the Heart**

### Vasculature of heart

The blood vessels of the heart comprise the coronary arteries and cardiac veins, which carry blood to and from most of the myocardium. The endocardium and some subendocardial tissue located immediately external to the endocardium receive oxygen and nutrients by diffusion or microvasculature directly from the chambers of the heart. The blood vessels of the heart, normally embedded in fat, course across the surface of the heart just deep to the epicardium. Occasionally, parts of the vessels become embedded within the myocardium. The blood vessels of the heart are affected by both sympathetic and parasympathetic innervation.

### Arterial supply of heart.

The coronary arteries, the first branches of the aorta, supply the myocardium and epicardium. The right and left coronary arteries arise from the corresponding aortic sinuses at the proximal part of the ascending aorta, just superior to the aortic valve, and pass around opposite sides of the pulmonary trunk. The coronary arteries supply both the atria and the ventricles; however, the atrial branches are usually small and not readily apparent in the cadaveric heart. The ventricular distribution of each coronary artery is not sharply demarcated.



**Figure 1.6: The Blood Supply of the Heart**

The right coronary artery (RCA) arises from the right aortic sinus of the ascending aorta and passes to the right side of the pulmonary trunk, running in the coronary sulcus. Near its origin, the RCA usually gives off an ascending sinuatrial nodal branch, which supplies the SA node. The RCA then descends in the coronary sulcus and gives off the right marginal branch, which supplies the right border of the heart as it runs toward (but does not reach) the apex of the heart. After giving off this

branch, the RCA turns to the left and continues in the coronary sulcus to the posterior aspect of the heart. At the posterior aspect of the crux (L. cross) of the heart—the junction of the interatrial and interventricular (IV) septa between the four heart chambers—the RCA gives rise to the atrioventricular nodal branch, which supplies the AV node. The SA and AV nodes are part of the conducting system of the heart.

**Typically, the RCA supplies:**

- The right atrium.
- Most of right ventricle.
- Part of the left ventricle (the diaphragmatic surface).
- Part of the IV septum, usually the posterior third.
- The SA node (in approximately 60% of people).
- The AV node (in approximately 80% of people).

**The left coronary artery (LCA)** arises from the left aortic sinus of the ascending aorta, passes between the left auricle and the left side of the pulmonary trunk, and runs in the coronary sulcus. In approximately 40% of people, the SA nodal branch arises from the circumflex branch of the LCA and ascends on the posterior surface of the left atrium to the SA node. As it enters the coronary sulcus, at the superior end of the anterior IV groove, the LCA divides into two branches, the anterior IV branch (clinicians continue to use LAD, the abbreviation for the former term—left anterior descending artery) and the circumflex branch.

The anterior IV branch passes along the IV groove to the apex of the heart. Here it turns around the inferior border of the heart and commonly anastomoses with the posterior IV branch of the right coronary artery. The anterior IV branch supplies adjacent parts of both ventricles and, via IV septal branches, the anterior two thirds of the IVS. In many people, the anterior IV branch gives rise to a lateral branch (diagonal artery), which descends on the anterior surface of the heart.

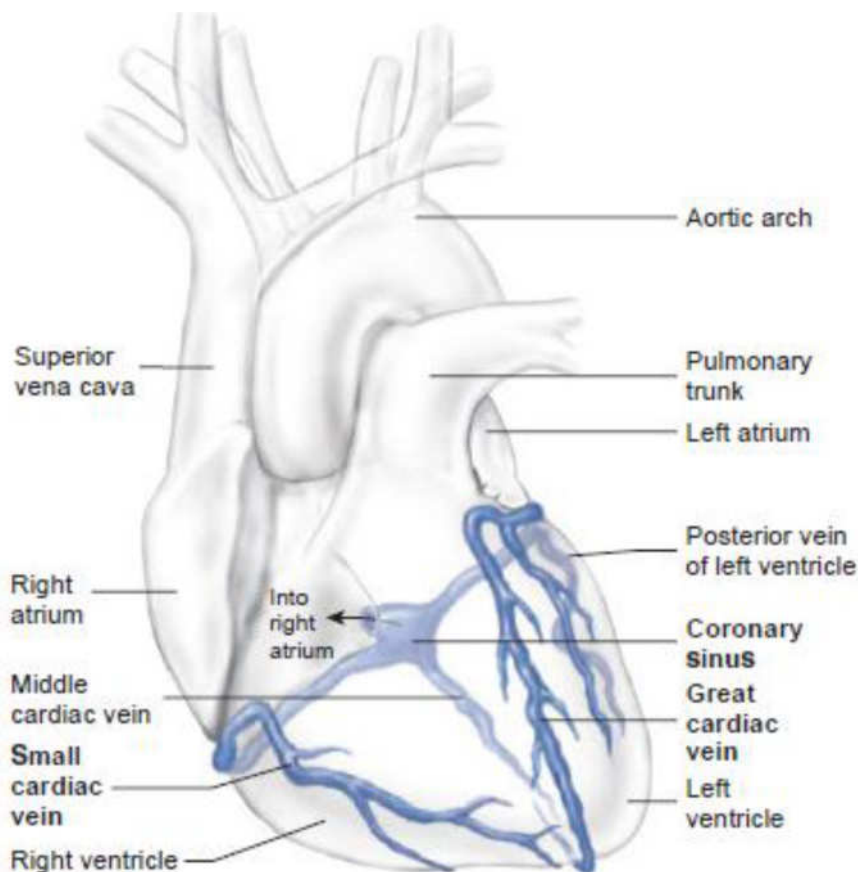
The smaller circumflex branch of the LCA follows the coronary sulcus around the left border of the heart to the posterior surface of the heart. The left marginal branch of the circumflex branch follows the left margin of the heart and supplies the left ventricle. Most commonly, the circumflex branch of the LCA terminates in the coronary sulcus on the posterior aspect of the heart before reaching the crux of the heart, but in approximately one third of hearts it continues to supply a branch that runs in or adjacent to the posterior IV groove.

### Typically, the LCA supplies:

- i. The left atrium.
- ii. Most of the left ventricle.
- iii. Part of the right ventricle.
- iv. Most of the IVS (usually its anterior two thirds), including the AV bundle of the conducting system of the heart, through its perforating IV septal branches.
- v. The SA node (in approximately 40% of people).

### Venous drainage of the heart

The heart is drained mainly by veins that empty into the coronary sinus and partly by small veins that empty into the right atrium. The coronary sinus, the main vein of the heart, is a wide venous channel that runs from left to right in the posterior part of the coronary sulcus. The coronary sinus receives the great cardiac vein at its left end and the middle cardiac vein and small cardiac veins at its right end. The left posterior ventricular vein and left marginal vein also open into the coronary sinus.



**Figure 1.7: Venous Drainage of the Heart**



The great cardiac vein is the main tributary of the coronary sinus. Its first part, the anterior interventricular vein, begins near the apex of the heart and ascends with the anterior IV branch of the LCA. At the coronary sulcus it turns left, and its second part runs around the left side of the heart with the circumflex branch of the LCA to reach the coronary sinus. (An unusual situation is occurring here: Blood is flowing in the same direction within a paired artery and vein!) The great cardiac vein drains the areas of the heart supplied by the LCA.

The middle cardiac vein (posterior IV vein) accompanies the posterior interventricular branch (usually arising from the RCA). A small cardiac vein accompanies the right marginal branch of the RCA. Thus these two veins drain most of the areas commonly supplied by the RCA. The oblique vein of the left atrium (of Marshall) is a small vessel, relatively unimportant postnatally, that descends over the posterior wall of the left atrium and merges with the great cardiac vein to form the coronary sinus (defining the beginning of the sinus). The oblique vein is the remnant of the embryonic left SVC, which usually atrophies during the fetal period, but occasionally persists in adults, replacing or augmenting the right SVC.

Some cardiac veins do not drain via the coronary sinus. Several small anterior cardiac veins begin over the anterior surface of the right ventricle, cross over the coronary sulcus, and usually end directly in the right atrium; sometimes they enter the small cardiac vein. The smallest cardiac veins (*L. venae cordis minima*) are minute vessels that begin in the capillary beds of the myocardium and open directly into the chambers of the heart, chiefly the atria. Although called veins, they are valveless communications with the capillary beds of the myocardium and may carry blood from the heart chambers to the myocardium.

### **Lymphatic drainage of the heart.**

Lymphatic vessels in the myocardium and subendocardial connective tissue pass to the subepicardial lymphatic plexus. Vessels from this plexus pass to the coronary sulcus and follow the coronary arteries. A single lymphatic vessel, formed by the union of various lymphatic vessels from the heart, ascends between the pulmonary trunk and left atrium and ends in the inferior tracheobronchial lymph nodes, usually on the right side.

### **Innervation of the heart.**

The heart is supplied by autonomic nerve fibers from the cardiac plexus, which is often quite artificially divided into superficial and deep portions. This nerve network is most commonly described as lying on

the anterior surface of the bifurcation of the trachea (a respiratory structure), since it is most commonly observed in dissection after removal of the ascending aorta and the bifurcation of the pulmonary trunk. However, its primary relationship is to the posterior aspect of the latter two structures, especially the ascending aorta. The cardiac plexus is formed of both sympathetic and parasympathetic fibers en route to the heart, as well as visceral afferent fibers conveying reflexive and nociceptive fibers from the heart. Fibers extend from the plexus along and to the coronary vessels and to components of the conducting system, particularly the SA node.

The sympathetic supply is from presynaptic fibers, with cell bodies in the intermediolateral cell columns (IMLs) of the superior five or six thoracic segments of the spinal cord, and postsynaptic sympathetic fibers, with cell bodies in the cervical and superior thoracic paravertebral ganglia of the sympathetic trunks. The postsynaptic fibers traverse cardiopulmonary splanchnic nerves and the cardiac plexus to end in the SA and AV nodes and in relation to the terminations of parasympathetic fibers on the coronary arteries. Sympathetic stimulation causes increased heart rate, impulse conduction, force of contraction, and, at the same time, increased blood flow through the coronary vessels to support the increased activity. Adrenergic stimulation of the SA node and conducting tissue increases the rate of depolarization of the pacemaker cells while increasing atrioventricular conduction.

### **3.3 Developmental and microanatomy of the heart**

**The cardiovascular system is functionally important in development.**

This statement may seem like a no-brainer, but it isn't. Most cells and organs in an embryo do very little except grow and differentiate—the brain, lungs, liver, digestive system, gonads, and kidneys all fall into this category. But the cardiovascular system has to do real work early on. The reason is that once the embryo has gotten thicker than 200 to 400 microns, the diffusion of nutrients, oxygen, and carbon dioxide is inadequate to service an inner mass of very metabolically active cells. A circulatory system is needed to keep these cells from dying, and it needs to do it by the middle of the fourth week of gestation (circa embryonic day 24). And this system has to work continuously while undergoing some serious remodeling.

#### **Remodelling of the Cardiovascular System with Development**

The cardiovascular system is radically remodeled several times during development. The system is revamped at least four times.

- It starts out as an approximately bilateral system of contractile blood vessels. Parts coalesce at midline to form a single channel or central pump.
- Parts of the contents regress in the embryo, including some early renal structures (the mesonephros). As a result entire systems of veins (and some embryonic arteries) also regress. Virtually the entire posterior cardinal venous system gets re-absorbed (see below).
- The heart gets split into two pumps. The right side basically pumps blood straight into the descending aorta (through the ductus arteriosus shunt). The left side pumps blood into the rapidly growing cranium and brain.
- At birth the whole pattern of circulation has to be modified radically in a matter of minutes. The main objectives are to shut down the chorionic/placental circulation and open up the pulmonary circulation. There are several subsidiary changes.

**The cardiovascular system is not just made up of splanchnic mesoderm.**

The heart also gets a critical influx of cells from the neural crest. These crest cells contribute to the formation of the endocardial cushions, which in turn are critical in converting a simple one-chamber pump into a complex two-chambered heart with sophisticated valves. They may be called "neural" crest, but these cells have an almost miraculous ability to make different types of tissues (cranial skeleton, adrenals, neurons, glia, even muscles in the ciliary body).

**The cells that give rise to the heart (and liver) are initially in front of the neural plate and around the sides of the foregut**

There is a big block of splanchnic mesoderm in front of the CNS and in front of the oropharyngeal opening (or membrane). The CNS grows forward over this mesenchymal mesoderm, and the mesoderm rotates down toward the yolk sac. The end result is that the heart, which is part of this mesoderm, gets tucked into the embryo's "neck." Just behind the heart is more of this big block of mesoderm, now called the transverse septum. It becomes the liver and the diaphragm.

**Three systems of veins disgorge blood into the sinus venosus.**

- **The vitelline system from the yolk sac:** This system is a nursery for blood cells. You think of a yolk sac as being part of a feeding system for an embryo. It lost that function when placental mammals invented our placentas. But, the vitelline system is still associated with the gut. In fact, the portal vein is one important adult derivative of a plexus vitelline veins that surround the duodenum (by the way, the duo+denum is two+ten fingers in length, and "vitelline" means glassy, and gets this name from the shiny appearance of the membrane.)
- **The umbilical system:** Originally, there are two umbilical veins that return recharged blood from the chorionic plexi of the placenta. We owe our oversized human brains to these veins (and the placenta). Most of the right umbilical vein regresses. The left umbilical vein takes a short cut through the liver (the ductus venosus), and the oxygenated blood is delivered into the inferior vena cava and then into the sinus venosus/right atrium. As you would expect, most of this umbilical system is useless after birth. See the List of Derivatives if you want the details.
- **The cardinal system:** It is messy. Here is the main story—The anterior cardinals (or precardinals) drain the brain. The blood gets dumped into the common cardinal veins, and these common cardinals empty into the sinus venosus. If you had to guess at this point, you would probably guess that these guys turn into parts of the internal jugular veins and the superior vena cava of adults.

You would be right. The lower part of the left anterior cardinal vein actually regresses, but before it does that, a new conduit is needed to carry blood from the left side of our embryo's cranium back to the heart. That is where the left brachiocephalic vein comes in. It is a left-to-right venous shunt that only develops secondarily. Now for the posterior cardinals: These veins service the "mesonephros." Never heard of it. That's because it regresses pretty quickly (except for a few leftovers in the testes). So when the mesonephros regresses so do most parts of the posterior cardinal veins. The rostral-most part on the right side turns into the root of the azygos vein (the part that's attached to the superior vena cava). The inferior vena cava comes from bits and pieces of the 2nd and 3rd generation versions of the cardinal system. These 2nd and 3rd generation systems are called the sub- and supra-cardinals. The subcardinals drain the kidneys and gonads, and the more dorsally situated supracardinals drain the body wall.

**The heart starts out with its venous side (sinus venosus and atrium) located caudally.**

From an adult perspective, we think of the atria as being on top. It doesn't start that way, however. The venous side of the heart is initially situated next to the transverse septum. The three systems of veins, reviewed above, penetrate the septum transversum to enter the sinus venosus. But over a 3-4 day period the heart rotates rolls in the sagittal plane. The result is that the sinus venosus and common atrium are now located dorsal (deep) to the common ventricle.

**The heart and arterial trunk are split into the adult compartments by six growing walls of tissue (septae).**

- **Septum primum:** This first septum grows down the middle of the common atrium and eventually fuses with tissues that surround the narrow lumen between the atrium and ventricle (there is only one atrium and one ventricle at this point in the 5th week of gestation).
- **Septum secundum:** This slow growing second atrial septum grows parallel to the 1st septum, but is delayed by a couple of weeks. It is a more robust wall. Both the 1st and 2nd septums (septae) have big holes in them. To make it rough on you the hole in the first septum is called the second hole, or for formal types, the foramen secundum. The hole in the second septum is called the foramen ovale. I'll come back to the function role of these holes.
- **AV septum/endocardial cushion:** The endocardial cushions give rise to most of the cardiac skeleton that splits the atrial and ventricular sides of the heart. The cushions also build mitral and tricuspid valves.
- **Interventricular septum, muscular part:** A septum can also form when a central region grows particularly slowly. The surrounding tissue can bulge outward and fuse. This may be the mode by which the interventricular septum forms.
- **Interventricular septum, membranous part:** Maybe you have felt this part of the septum in the Gross Lab, tucked out of sight in the aortic vestibule, maybe not. When this membrane forms from a motley crew of cells from the endocardial cushions and the bulbar ridges, the heart is finally four-chambered.
- **Aortico-pulmonary septa, bulbar ridges:** There is no pulmonary trunk at early stages, just one big common arterial outflow, called the truncus arteriosus, that delivers all blood to an aortic sac. So how does this truncus arteriosus get split into an

ascending aorta and a pulmonary trunk? That is the job of the bulbar ridges. These ridges grow into the truncus from either side and fuse in the middle. They spiral neatly down the truncus until they reach the ventricle(s). Magic happens, and the aortic half hooks up to the left ventricle; the pulmonary trunk hooks up to the right ventricle. This last step occurs at the same time that the membranous part of the interventricular foramen is forming. A process as complex as this can screw up. Imagine if that partitioning of the truncus into the two divisions isn't 50-50 but say, 20-80. The bore of the pulmonary trunk may be too small and that of the aorta too wide. If that happens you often end up with a constellation of four (or five) related abnormalities in a neonate: stenosis (turbulent and noisy flow of blood in a narrow pulmonary trunk) often with cyanosis a failure of the membranous part of the ventricular septum to form fully—in other words, a ventricular septal defect the opening of the aorta straddles both ventricles (overriding aorta) an enlarged right ventricle (it is working harder to eject blood into the narrow lumen of the pulmonary trunk)

### 3.4 Microanatomy of the great vessels

The cardiovascular system may be divided into four major components: the heart, the macrocirculation, the microcirculation and the lymph vascular system. Essentially, the macrocirculation comprises all vessels, both arteries and veins that would be visible to the eye. The vessels of the macrocirculation supply and drain a network of fine vessels interposed between them, the capillaries. This network is also called the capillary bed. **Water and other components of the blood plasma which exude from the blood vessels form the interstitial fluid, which is returned to the circulation by the lymph vascular system.**

#### General Structure of Blood Vessels

You have already seen blood vessels of various sizes and types in preparations available in other laboratory sessions, and you should be aware that the histological appearances of vessels of different sizes (arterioles vs. arteries) and different types (arteries vs. veins) are different from each other. (if you have not seen these in the laboratory, try and do so. These differences are the result of quantitative variations of a common structural pattern that can be seen in all blood vessels with the exception of capillaries, i.e. the division of the walls of the blood vessels into three layers or tunics.

#### The Tunica intima

Tunica intima limits the vessel wall towards the lumen of the vessel and comprises its endothelial lining (typically simple, squamous) and associated connective tissue. Beneath the connective tissue, we find the

internal elastic lamina, which delimits the tunica intima from the Tunica media.

### The Tunica media

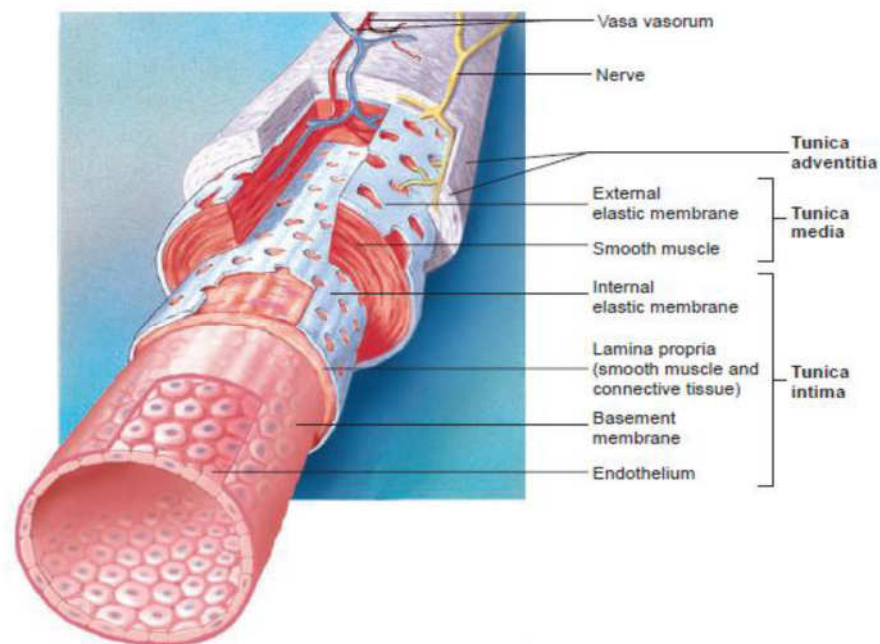
The Tunica media is formed by a layer of circumferential smooth muscle and variable amounts of connective tissue. A second layer of elastic fibers, the external elastic lamina, is located beneath the smooth muscle. It delimits the tunica media from the tunica adventitia, which consist of mainly of connective tissues fibers.

### Tunica adventitia

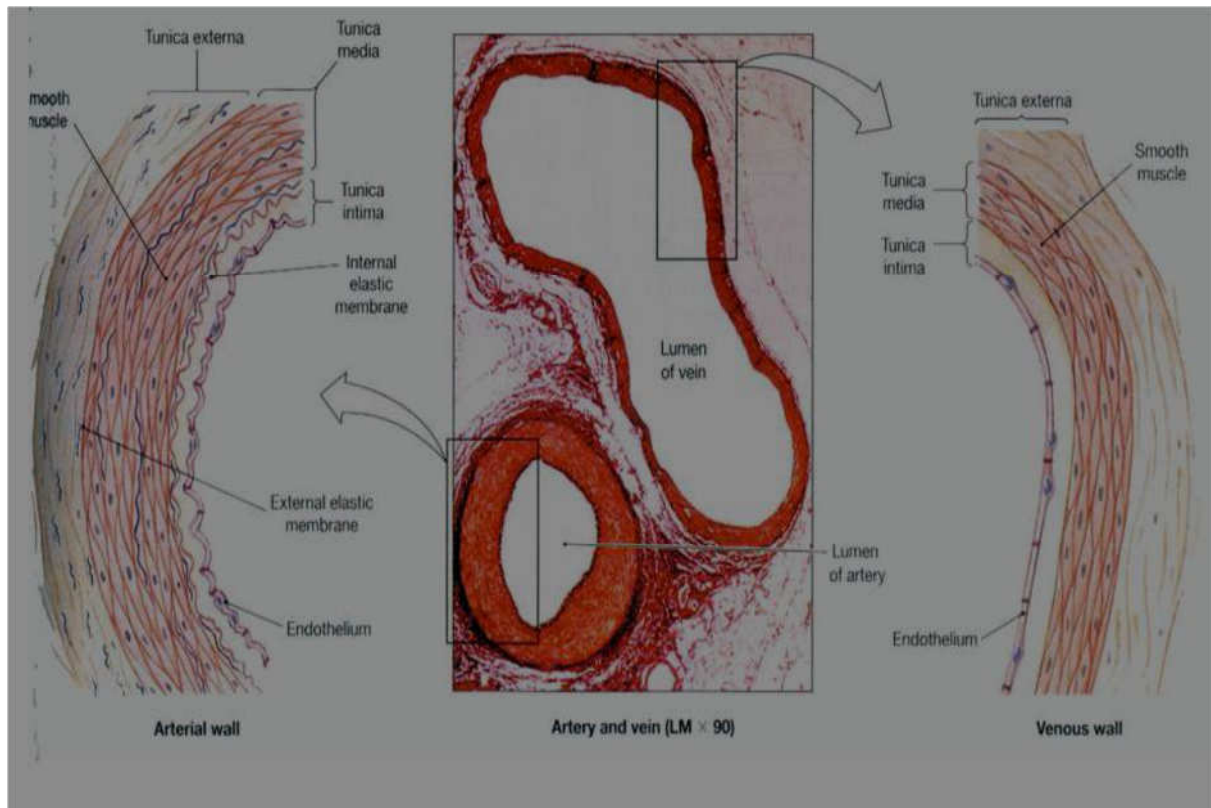
The tunica adventitia blends with the connective tissue surrounding the vessel. The definition of the outer limit of the tunica adventitia is therefore somewhat arbitrary.

### Vasa Vasorum

A blood vessel that supplies the vessel that supplies blood to the wall of the vessel. it supplies nutrients to the blood vessel.



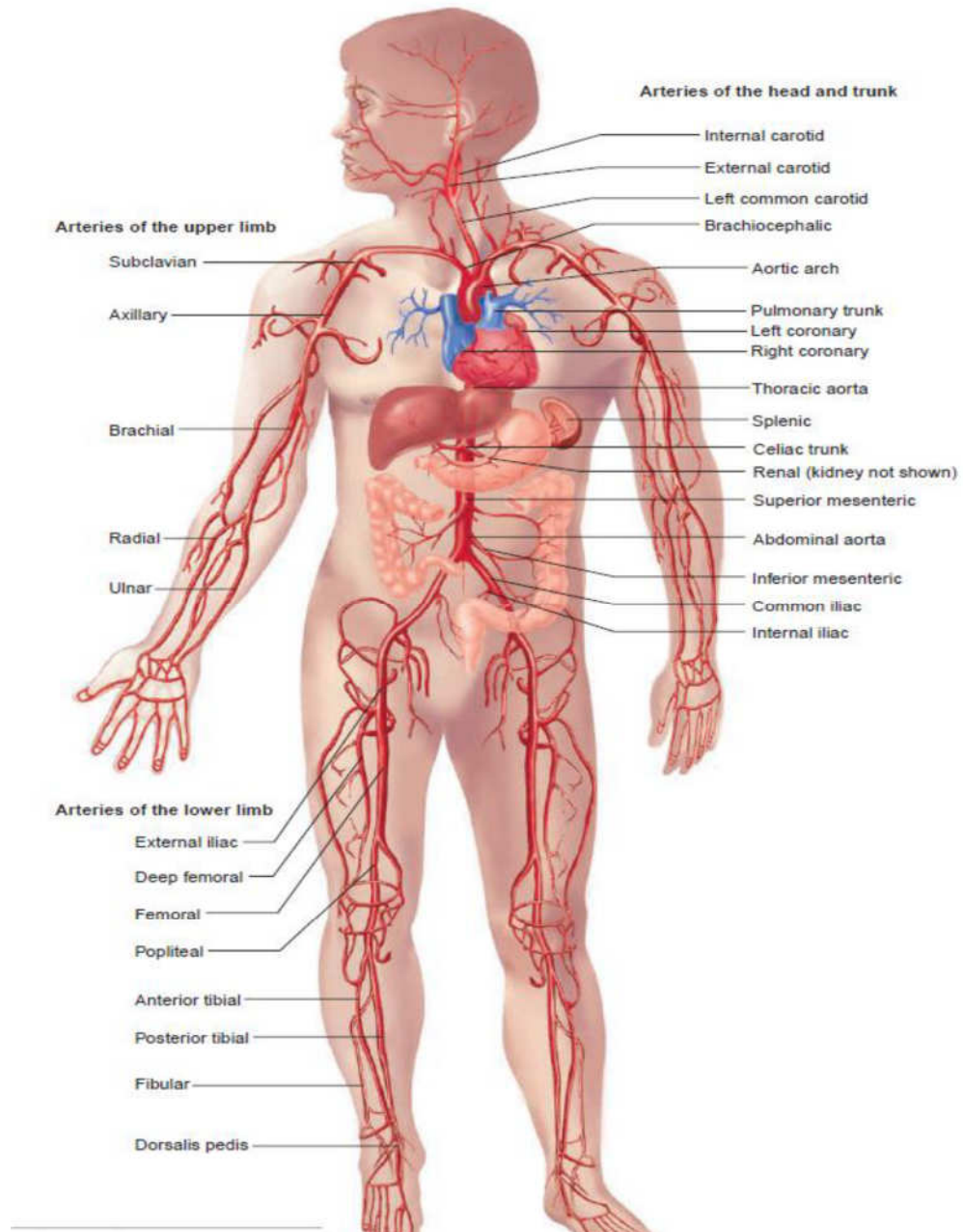
**Fig. 1.8:** Histology of a blood vessel. (showing layers of the blood vessel wall including the intima, media and adventitia)



**Fig. 1.9:**



## VARIATIONS OF VESSEL WALL STRUCTURES Arteries



**Fig. 1.10:**

All arterial vessels originate from either the pulmonary trunk (from the right ventricle) or the aorta (from the left ventricle). Specializations of the walls of arteries relate mainly to two factors: the pressure pulses generated during contractions of the heart (systole) and the regulation of blood supply to the target tissues of the arteries. The tunica media is the main site of histological specialisations in the walls of arteries.

Vessels close to the heart (aorta, pulmonary trunk and the larger arteries that originate from them) are elastic arteries.

### **Elastic arteries**

The tunica intima of elastic arteries is thicker than in other arteries. A layer of loose connective tissue beneath the endothelium (subendothelial connective tissue) allows the tunica intima to move independently from other layers as the elastic arteries distend with the increase in systolic blood pressure. Distension of the walls is facilitated by concentric fenestrated lamellae of elastic fibres in a thick tunica media. In adult humans, about 50 elastic lamellae are found in the tunica media of the aorta. The energy stored in the elastic fibres of the tunica media allows elastic arteries to function as a "pressure reservoir" which forwards blood during ventricular relaxation (diastole). Smooth muscle cells and collagen fibres are present between the layers of elastic fibres. Both fibre types are produced by the smooth muscle cells. Each elastic lamella forms together with interlamellar fibres and cells to form a lamellar unit. The external elastic lamina is difficult to discern from other layers of elastic fibres in the tunica media. The tunica adventitia appears thinner than the tunica media and contains collagen fibres and the cell types typically present in connective tissue.

The walls of these large arteries are so thick that their peripheral parts cannot derive enough oxygen and nutrients from the blood of the vessel that they form. Larger vessels are therefore accompanied by smaller blood vessels which supply the tunica adventitia and, in the largest vessels, the outer part of the tunica media of the vessel wall. The vessels are called vasa vasorum. In macroscopic preparations vasa vasorum are visible as fine dark lines on the surface of the larger arteries.

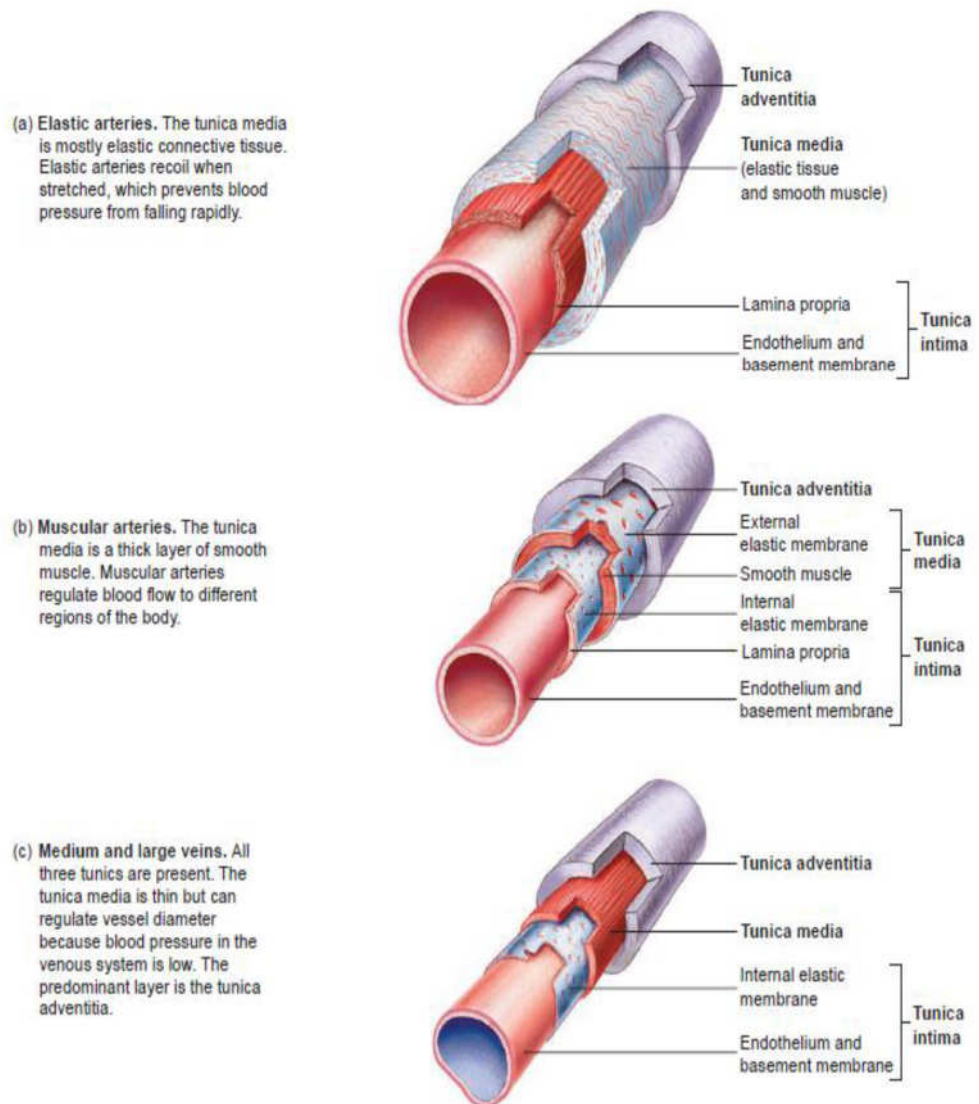
The diameter of individual arteries decreases as we follow them further into the periphery. However, their total diameter increases, which leads to a fall in blood pressure. Also, the properties of the elastic arteries have to some extent evened out differences in diastolic and systolic blood pressure. The amount of elastic fibres in the tunica media decreases with these physiological changes. We now find a type of arteries which are termed muscular arteries.

### **Muscular arteries**

The tunica intima is thinner than in elastic arteries. Subendothelial connective tissue other than the internal elastic lamina is often difficult to discern. The internal elastic lamina forms a well-defined layer. The tunica media is dominated by numerous concentric layers of smooth

muscle cells. Fine elastic fibres and a few collagen fibres are also present. The external elastic lamina can be clearly distinguished although it may be incomplete in places. The thickness and appearance of the tunica adventitia is variable.

The basic structure of the walls of arteries does not change much as we come to the next type of arterial vessels. Size is used to differentiate them from muscular arteries.



**Fig.1.11:**

### Arterioles

Arterioles are arterial vessels with a diameter below 0.1 - 0.5 mm (different values in different textbooks). Endothelial cells are smaller than in larger arteries, and the nucleus and surrounding cytoplasm may 'bulge' slightly into the lumen of the arteriole. The endothelium still rests on an internal elastic lamina, which may be incomplete and which is not always well-defined in histological sections. The tunica media consists

of 1-3 concentric layers of smooth muscle cells. It is difficult to identify an external elastic lamina or to distinguish the tunica adventitia from the connective tissue surrounding the vessel. The smooth muscle of arterioles and, to some extent, the smooth muscle of small muscular arteries regulate the blood flow to their target tissues. Arterioles receive both sympathetic and parasympathetic innervation. The final branching of the arterioles finally gives rise to the capillary network (microcirculation).

## Capillaries

The sum of the diameters of all capillaries is significantly larger than that of the aorta (by about three orders of magnitude), which results in decreases in blood pressure and flow rate. Also, capillaries are very small vessels. Their diameter ranges from 4-15  $\mu\text{m}$ . The wall of a segment of capillary may be formed by a single endothelial cell. This results in a very large surface to volume ratio. The low rate of blood flow and large surface area facilitate the functions of capillaries in

- i. providing nutrients and oxygen to the surrounding tissue, in
- ii. the absorption of nutrients, waste products and carbon dioxide, and in
- iii. the excretion of waste products from the body.

These functions are also facilitated by a very simple organization of the wall of capillaries. Only the tunica intima is present, which typically only consists of the endothelium, its basal lamina and an incomplete layer of cells surrounding the capillary, the pericytes. Pericytes have contractile properties and can regulate blood flow in capillaries. In the course of vascular remodelling and repair, they can also differentiate into endothelial and smooth muscle cells.

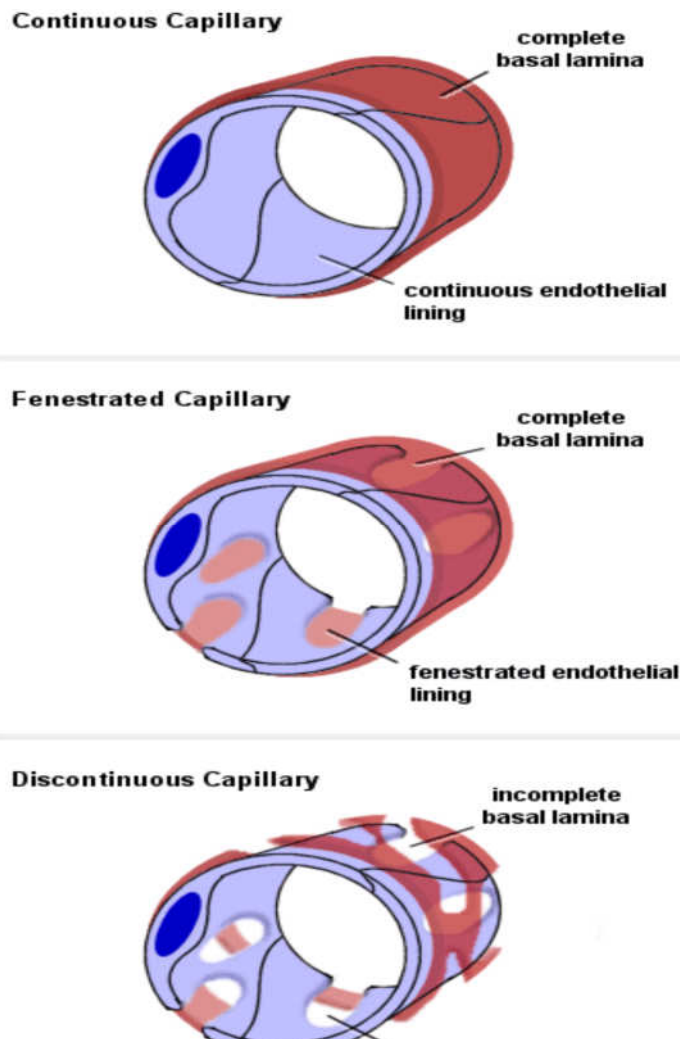
Three types of capillaries can be distinguished based on features of the endothelium.

**Continuous capillaries** - are formed by "continuous" endothelial cells and basal lamina. The endothelial cell and the basal lamina do not form openings, which would allow substances to pass the capillary wall without passing through both the endothelial cell and the basal lamina. Both endothelial cells and the basal lamina can act as selective filters in continuous capillaries.

**Fenestrated capillaries** -endothelial cell body forms small openings called fenestrations, which allow components of the blood and interstitial fluid to bypass the endothelial cells on their way to or from the tissue surrounding the capillary. The fenestrations may represent or

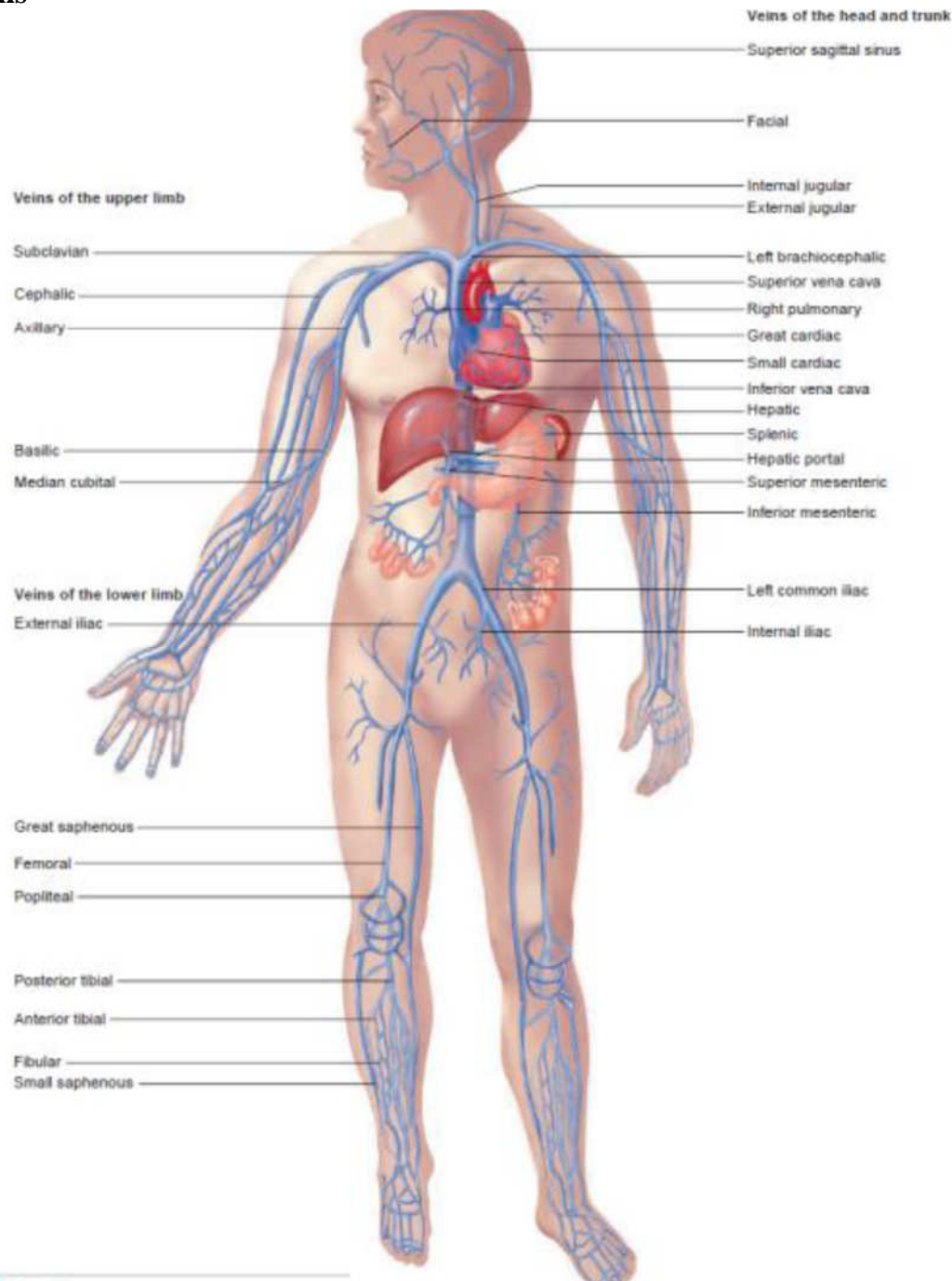
arise from pinocytotic vesicles which open onto both the luminal and basal surfaces of the cell. The extent of the fenestration may depend on the physiological state of the surrounding tissue, i.e. fenestration may increase or decrease as a function of the need to absorb or secrete. The endothelial cells are surrounded by a continuous basal lamina, which can act as a selective filter.

**Discontinuous capillaries-** are formed by fenestrated endothelial cells, which may not even form a complete layer of cells. The basal lamina is also incomplete. Discontinuous capillaries form large irregularly shaped vessels, sinusoids or sinusoid capillaries. They are found where a very free exchange of substances or even cells between bloodstream and organ is advantageous



**Fig. 1.12:**

## Veins



**Fig. 1.13:**

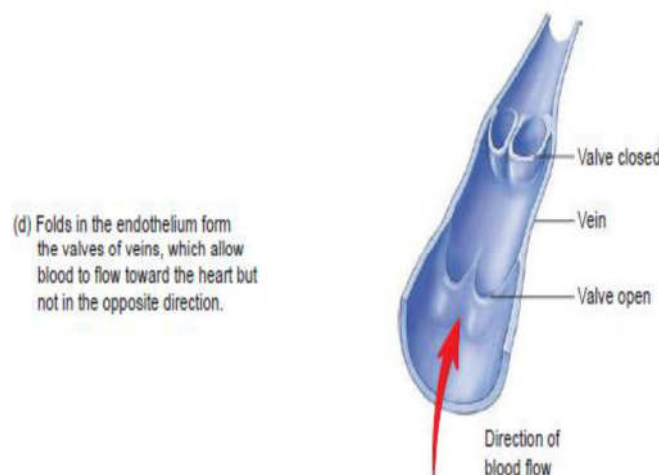
The walls of veins are thinner than the walls of arteries, while their diameter is larger. In contrast to arteries, the layering in the wall of veins is not very distinct. The tunica intima is very thin. Only the largest veins contain an appreciable amount of subendothelial connective tissue. Internal and external elastic laminae are absent or very thin. The tunica media appears thinner than the tunica adventitia, and the two layers tend to blend into each other. The appearance of the wall of veins also depends on their location. The walls of veins in the lower parts of the

body are typically thicker than those of the upper parts of the body, and the walls of veins which are embedded in tissues that may provide some structural support are thinner than the walls of unsupported veins. Venous vessels originate from the capillary network which coalesce into the smallest venous vessels called the venules.

### Venules

They are larger than capillaries. Small venules are surrounded by pericytes (A few smooth muscle cells may surround larger venules). The venules merge to form small to medium-sized veins which contain bands of smooth muscle in the tunica media. The tunica adventitia is well developed. In some veins (e.g. the veins of the pampiniform plexus in the spermatic cord) the tunica adventitia contains longitudinally oriented bundles of smooth muscle.

Aside from most veins in the head and neck, small to medium-sized veins are also characterised by the presence of valves. The valves are formed by loose, pocket-shaped folds of the tunica intima, which extend into the lumen of the vein. The opening of the pocket will point into the direction of blood flow towards the heart. One to three (usually two) pockets form the valve. Blood flowing towards heart will pass the pockets. If the flow reverses, blood will fill the pockets which will occlude the lumen of the vein and prevent the return of blood into the part of the vein preceding the valve. The ability of the valves to prevent backflow depends to some extent on the state of contraction (tone) of the smooth muscle in the wall of the vein.



**Fig. 1.14:**

The largest veins of the abdomen and thorax do contain some subendothelial connective tissue in the tunica intima, but both it and the tunica media are still comparatively thin. Collagen and elastic fibres are present in the tunica media. The tunica adventitia is very wide, and it

usually contains bundles of longitudinal smooth muscle. The transition from the tunica adventitia to the surrounding connective tissue is gradual. Valves are absent. Vasa vasorum are more frequent in the walls of large veins than in that of the corresponding arteries - probably because of the lower oxygen tension in the blood contained within them.

### **Additional Specialisations of Vessels**

Small arteries and veins often form anastomosing networks, which provides routes for alternative blood supply and drainage if one of the vessels should become occluded because of pathological or normal physiological circumstances. Some arteries are however the only supply of blood to their target tissues. These arteries are called end arteries. Tissues which are supplied by end arteries die if the arteries become occluded.

The segments of the kidney and the heads of the gastrocnemius muscle are examples of tissues supplied by end arteries.

Arteries and veins may also form arteriovenous shunts, which can shunt the blood flow that otherwise would enter the capillary network between the vessels. These shunts usually contain specialisations of the smooth muscle in the region of the shunt. Arteriovenous shunts are frequently seen in the blood supply of distal parts of the limbs and the nose (thermoregulation) and in the blood supply of endocrine organs.

### **Lymphatic system**

Parts of the blood plasma will exude from the blood vessels into the surrounding tissues because of transport across the endothelium or because of blood pressure and the fenestration of some capillaries (this process is partly counteracted by the higher osmotic pressure of the blood). The fluid entering tissues from capillaries adds to the interstitial fluid normally found in the tissue. The surplus of liquid needs to be returned to the circulation. Lymph vessels are dedicated to this unidirectional flow of liquid, the lymph. Three types of lymph vessels can be distinguished based on their size and morphology.

**Lymph capillaries** are somewhat larger than blood capillaries and very irregularly shaped. They begin as blind-ending tubes in connective tissue. The basal lamina is almost completely absent and the endothelial cells do not form tight junctions, which facilitates the entry of liquids into the lymph capillary. Temporary openings in the endothelial lining of the lymph capillaries also allow the entry of larger particles into the lymph capillaries (lipid droplets, which are absorbed from the lumen of the gut do not enter blood capillaries, but enter the circulation via lymph

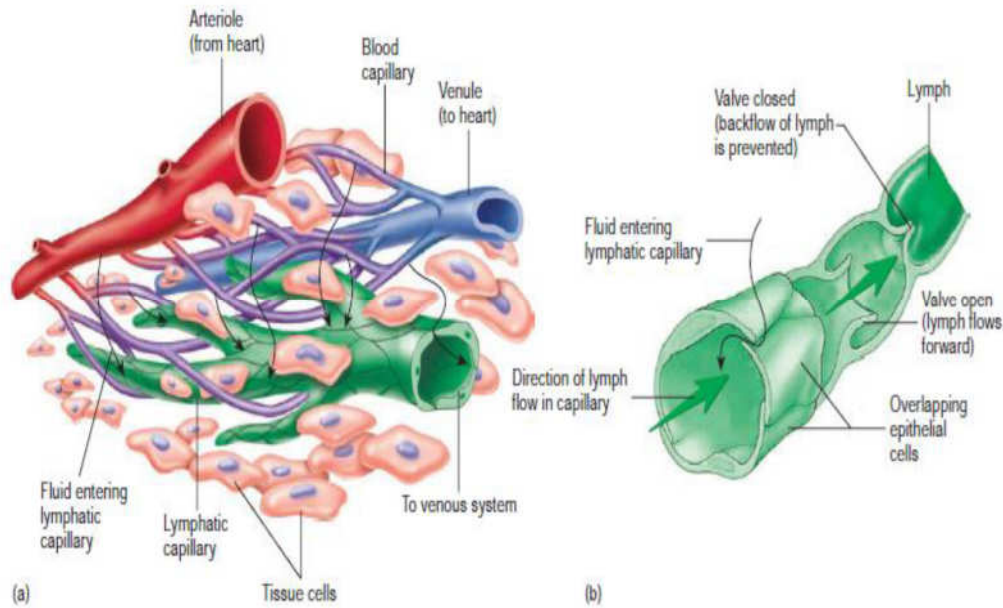


vessels which are found in the villi of the ileum and jejunum). Lymph capillaries merge to form **Lymph collecting vessels** which are larger and form valves but otherwise appear similar to lymph capillaries. The lymph is moved by the compression of the lymph vessels by surrounding tissues. The direction of lymph flow is determined by the valves. Lymph vessels empty intermittently into lymph nodes from which the lymph continues in efferent lymph vessels.

Only very little lymph is returned from the limbs if they are immobilized, which illustrates the importance of muscular action in lymph transport. This is also the reason for immobilizing limbs that are either infected or that have been bitten by venomous Australians. The effect can also be observed after long intercontinental flight when you may feel that your shoes and socks are just about one number too small. Finally, impeded lymph drainage is one of the problems associated with surgery which requires the removal of lymph nodes and which thereby interrupts the lymph collecting vessels. Eventually the lymph collecting vessels merge to form Lymph ducts.

**Lymph ducts** which contain one or two layers of smooth muscle cells in their wall (some textbooks call this layer the tunica media of lymph vessels). They also have valves. The walls of the lymph ducts are less flexible in the region of the attachment of the valves to the wall of the duct, which may give a beaded appearance to the lymph ducts. Peristaltic contractions of the smooth muscle contribute to the movement of lymph towards the heart in addition to the compression of the ducts by surrounding tissues.

The largest lymph duct of the body, the thoracic duct, drains lymph from the lower half and upper left quadrant of the body and empties the lymph into the circulation by merging with the vascular system close to the junction of the left internal jugular and subclavian veins. That it is the largest lymph duct does not mean that it is a large vessel when compared to the large arteries and veins. It actually is not much larger (about 5mm in diameter) than one of the superficial forearm veins.



**Fig. 1.15:**

## 4.0 CONCLUSION

The heart and the great vessels have different structures that have features that can support the functions that each of the organs perform. The organs are seen from the perspectives of the microscopic and macroscopic features and deviations in any part or form always have negative consequences that manifest in disease states.

## 5.0 SUMMARY

In this unit, you have learnt about following:

- i. The structure and functions of the pericardium
- ii. The structure, position and function of the heart and the great vessels
- iii. Developmental and microanatomy of the heart and great vessels

### Clinical correlates

#### i. Stroke or Cerebrovascular Accident

Thrombi (clots) form on the walls of the left atrium in certain types of heart disease. If these thrombi detach, or pieces break off from them, they pass into the systemic circulation and occlude peripheral arteries. Occlusion of an artery supplying the brain results in a stroke or cerebrovascular accident (CVA), which may affect vision, cognition, or the motor function of parts of the body previously controlled by the now-damaged (ischemic) area of the brain.

**ii. Valvular Heart Disease**

Disorders involving the valves of the heart disturb the pumping efficiency of the heart. Valvular heart disease produces either stenosis (narrowing) or insufficiency. Stenosis is the failure of a valve to open fully, slowing blood flow from a chamber. Insufficiency or regurgitation, on the other hand, is failure of the valve to close completely, usually owing to nodule formation on (or scarring and contraction of) the cusps so that the edges do not meet or align. This allows a variable amount of blood (depending on the severity) to flow back into the chamber it was just ejected from. Both stenosis and insufficiency result in an increased workload for the heart. Because valvular diseases are mechanical problems, damaged or defective cardiac valves can be replaced surgically in a procedure called valvuloplasty. Most commonly, artificial valve prostheses made of synthetic materials are used in these valve-replacement procedures, but xenografted valves (valves transplanted from other species, such as pigs) are also used.

**iii. Pulmonary valve stenosis**

In pulmonary valve stenosis, the valve cusps are fused, forming a dome with a narrow central opening. In infundibular pulmonary stenosis, the conus arteriosus is underdeveloped. Both types of pulmonary stenoses produce a restriction of right ventricular outflow and may occur together. The degree of hypertrophy of the right ventricle is variable.

**iv. Pulmonary valve incompetence**

If the free margins (lunules) of the cusps of a semilunar valve thicken and become inflexible or are damaged by disease, the valve will not close completely. An incompetent pulmonary valve results in a backrush of blood under high pressure into the right ventricle during diastole. Pulmonic regurgitation may be heard through a stethoscope as a heart murmur, an abnormal sound from the heart, produced in this case by damage to the cusps of the pulmonary valve.

**v. Aortic valve stenosis**

Case Study: Mrs Adu is a 62-year-old woman who had rheumatic fever when she was 12 years old. She has had a heart murmur since then. Mrs Adu went to her doctor, complaining of fatigue; dizziness, especially on rising from a sitting or lying position; and pain in her chest when she exercises. Her doctor listened to Mrs Adu's heart sounds and determined she has a systolic murmur. Her blood pressure (90/65 mm Hg) and heart rate (55 beats/min) were lower than normal. Mrs Adu's doctor referred

her to a cardiologist, who did additional tests. An electrocardiogram indicated she has left ventricular hypertrophy, and imaging techniques confirmed the left ventricular hypertrophy and a stenosed aortic semilunar valve. The cardiologist explained to Mrs Adu that the rheumatic fever she had as a child damaged her aortic semilunar valve and that the valve's condition had gradually become worse. The cardiologist recommended surgical replacement of her aortic semilunar valve or she will likely develop heart failure.

Aortic valve stenosis is the most frequent valve abnormality. For those born in the early and mid-20th century, rheumatic fever was a common cause but now accounts for <10% of cases of aortic stenosis. The great majority of aortic stenoses is a result of degenerative calcification and comes to clinical attention in the 6th decade of life or later. Aortic stenosis causes extra work for the heart, resulting in left ventricular hypertrophy.

#### **vi. Aortic valve insufficiency**

Insufficiency of the aortic valve results in aortic regurgitation (backrush of blood into the left ventricle), producing a heart murmur and a collapsing pulse (forcible impulse that rapidly diminishes).

#### **vii. Echocardiography**

Echocardiography (ultrasonic cardiography) is a method of graphically recording the position and motion of the heart by the echo obtained from beams of ultrasonic waves directed through the thoracic wall. This technique may detect as little as 20 mL of fluid in the pericardial cavity, such as that resulting from pericardial effusion. Doppler echocardiography is a technique that demonstrates and records the flow of blood through the heart and great vessels by Doppler ultrasonography, making it especially useful in the diagnosis and analysis of problems with blood flow through the heart, such as septal defects, and in delineating valvular stenosis and regurgitation, especially on the left side of the heart.

#### **viii. Coronary atherosclerosis**

The atherosclerotic process, characterized by lipid deposits in the intima (lining layer) of the coronary arteries, begins during early adulthood and slowly results in stenosis of the lumina of the arteries. As coronary atherosclerosis progresses, the collateral channels connecting one coronary artery with the other expand, which may initially permit adequate perfusion of the heart during relative inactivity. Despite this compensatory mechanism, the myocardium may not receive enough

oxygen when the heart needs to perform increased amounts of work. Strenuous exercise, for example, increases the heart's activity and its need for oxygen. Insufficiency of blood supply to the heart (myocardial ischemia) may result in MI.

#### **ix. Slowly progressive coronary artery disease**

In slow occlusion of a coronary artery, the collateral circulation has time to increase so that adequate perfusion of the myocardium can occur when a potentially ischemic event occurs. Consequently, MI may not result. On sudden blockage of a large coronary branch, some infarction is probably inevitable, but the extent of the area damaged depends on the degree of development of collateral anastomotic channels. If large branches of both coronary arteries are partially obstructed, an extracardiac collateral circulation may be used to supply blood to the heart. These collaterals connect the coronary arteries with the vasa vasorum (small arteries) in the tunica adventitia of the aorta and pulmonary arteries and with branches of the internal thoracic, bronchial, and phrenic arteries. Clinical studies show that anastomoses cannot provide collateral routes quickly enough to prevent the effects of sudden coronary artery occlusion. The functional value of these anastomoses thus appears to be more effective in slowly progressive CAD in individuals that are physically active.

#### **x. Transplantation**

The patient's heart is removed by incisions through the aorta, pulmonary trunk and both atria. The incision line through the right atrium leaves the two venae cavae, the posterior wall of the atrium and the region of the SA node in situ. The posterior part of the left atrium with the four pulmonary vein orifices is also left intact. The donor heart is trimmed through the atria to match up with the remains of the patient's atria, although the lower end of the donor superior vena cava remains attached to the right atrium so that the donor heart retains its own SA node. For combined heart-lung transplantation, the donor block is removed through the trachea, right atrium and aorta, and sutured to the recipient in that order.

## **6.0 TUTOR MARKED ASSIGNMENTS**

### **6.1 Activity (Note that all activities should be added to your portfolio)**

Using the knowledge acquired in this unit, check the heart sounds of 10 persons, with the consent of such persons, take snapshot of photographs of you while checking the heart sound. You can check the heart sounds

of your family members, friends and clients but with their consents. In your personal atlas, draw well labeled structures of the heart, an artery and a vein. In the laboratory and the clinics, demonstrate how to check heart sounds with your clinical instructors/preceptors.

## **6.2 Please answer the following questions**

- Describe in your own words the cardiac cycle.
- With regard to structure and functions, discuss the valves of the heart.
- Where will you position your stethoscope to hear heart sounds and why?

## **7.0 REFERENCES AND OTHER RESOURCES**

Hutchinson, M., Mallat, J., Marieb, E.N., Wilhelm P.B. (2007). A Brief Atlas of the Human Body. San Francisco: Pearson Education Inc.

Katherine M. A. Rogers and William N. Scott (2011) Nurses! Test Yourself in Anatomy and Physiology

Kathryn A. Booth, Terri. D. Wyman (2008) Anatomy, Physiology, and Pathophysiology for Allied Health

Keith L Moore, Persuade T.V.N (2018), The Developing Human Clinically Oriented Embryology 11th Edition Lippincott Williams & Wilkins

Kent M. Van De Graff, R.Ward Rhee, Sidney Palmer (2010) Schaum's Outline of human Anatomy and Physiology 3rd edition.

Philip Tate (2012) Seeley's Principles of Anatomy & Physiology 2nd ed.

Sadler T.W (2012), Langman's Medical Embryology 12th edition.

Seeley's Principles of Anatomy & Physiology, Second edition Published by McGraw-Hill, a business unit of The McGraw-Hill Companies, Inc., 1221 Avenue of the Americas, New York, NY 10020. Copyright c 2012- Chapter 17&18

## UNIT 2 BLOOD

### CONTENT

- 1.0 Introduction
- 2.0 Objectives
- 3.0 Main Content
  - 3.1 Functions of blood
  - 3.2 Composition of blood
  - 3.3 Plasma
  - 3.4 Formed elements
  - 3.5 Bleeding control
  - 3.6 Blood typing
- 4.0 Conclusion
- 5.0 Summary
- 6.0 Tutor Marked Assignments
- 7.0 References and other resources

### 1.0 INTRODUCTION

Diverse cultures have differing beliefs about the magical qualities of blood. I am sure that your culture has at least one that comes to mind right now, can you remember? For example, in some cultures, anyone born into royalty is referred to as “blue bloods”. While growing up as a child, I was taught a song that simply put says “blood is life” and anything without blood is without life. As I grew up I realized that some living things don’t have blood. Blood is essential to life and it can reveal so much about what is going on in our body systems. The scientific study of blood is as fascinating as it is important in your career as a nurse. Diseases of and in the blood are threats to life of patients and could pose as life threatening to care givers if not handled with care applying safety precautions. In this unit you will learn more about the structural make-up of the blood.

### 2.0 OBJECTIVES

- At the end of this unit, you should able to:
- Discuss the structural make-up of the blood
- Discuss the composition of blood
- Describe the formed elements
- State the major functions of the formed elements in blood
- Describe the components of plasma
- Discuss the process of haematopoiesis with the aid of a diagram
- Explain how the structure of the blood facilitate the control of bleeding.

### 3.0 MAIN CONTENT

#### 3.1 Functions of blood

The total blood volume in the average adult is about 4–5 L in females and 5–6 L in males. Blood makes up about 8% of the total weight of the body. An average-sized adult contains approximately 5 litres of blood. However, blood volume varies from person to person depending on the person's size, the amount of adipose tissue, and the concentrations of certain ions in the blood.

The heart pumps blood through blood vessels, which extend throughout the body. Blood helps maintain homeostasis in several ways:

- *Transport of gases, nutrients, and waste products.* Oxygen enters blood in the lungs and is carried to cells. Carbon dioxide, produced by cells, is carried in the blood to the lungs, from which it is expelled. The blood transports ingested nutrients, ions, and water from the digestive tract to cells, and the blood transports the waste products of cells to the kidneys for elimination.
- *Transport of processed molecules.* Many substances are produced in one part of the body and transported in the blood to another part, where they are modified. For example, the precursor to vitamin D is produced in the skin (see chapter 5) and transported by the blood to the liver and then to the kidneys for processing into active vitamin D. Active vitamin D is transported in the blood to the small intestines, where it promotes the uptake of calcium. Another example is lactic acid produced by skeletal muscles during anaerobic respiration. The blood carries lactic acid to the liver, where it is converted into glucose.
- *Transport of regulatory molecules.* The blood carries many of the hormones and enzymes that regulate body processes from one part of the body to another.
- *Regulation of pH and osmosis.* Buffers, which help keep the blood's pH within its normal limits of 7.35–7.45, are in the blood. The osmotic composition of blood is also critical for maintaining normal fluid and ion balance.
- *Maintenance of body temperature.* Blood is involved with body temperature regulation because warm blood is transported from the interior to the surface of the body, where heat is released from the blood.
- *Protection against foreign substances.* The cells and chemicals of the blood make up an important part of the immune system, protecting against foreign substances, such as microorganisms and toxins.

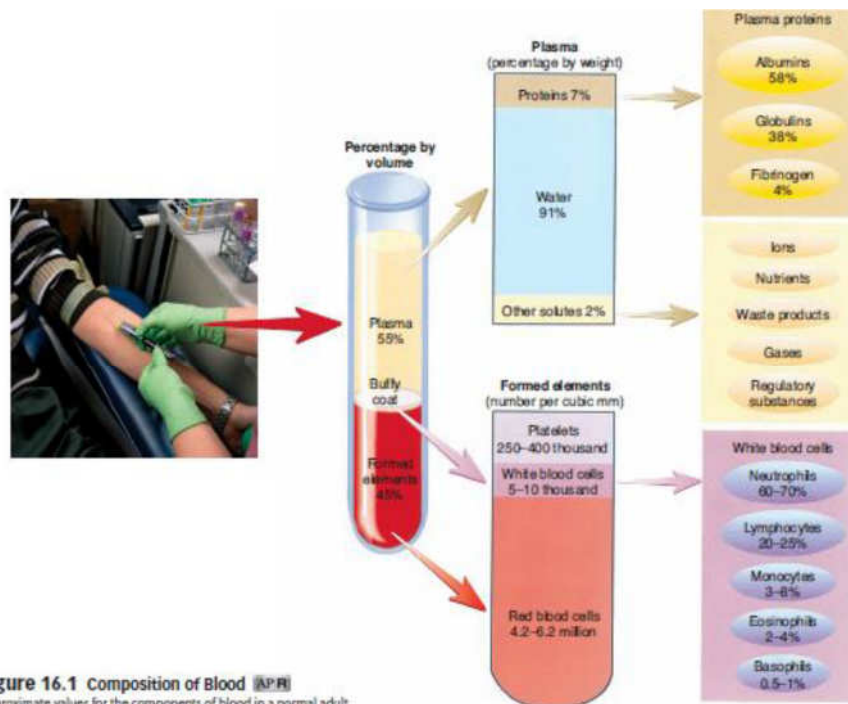


- **Clot formation.** Blood clotting protects against excessive blood loss when blood vessels are damaged. When tissues are damaged, the blood clot that forms is also the first step in tissue repair and the restoration of normal function.

### 3.2 Composition of blood

Blood is a type of connective tissue consisting of cells and cell fragments surrounded by a liquid matrix. The cells and cell fragments are the **formed elements**, and the liquid is the **plasma**. The formed elements make up about 45%, and plasma makes up about 55% of the total blood volume.

The percentage of red blood cells in a sample of blood is referred to as **hematocrit**. A healthy person normally has a hematocrit level of about 45%. Most of the cells are red blood cells, and only about 1% are white blood cells and platelets. The rest of blood (approximately 55%) is plasma.



**Figure 16.1** Composition of Blood (AP®)  
Approximate values for the components of blood in a normal adult.

### Fig. 2.1:

### 3.3 Plasma

Plasma is a pale yellow fluid that consists of about 91% water; 7% proteins; and 2% other substances, such as ions, nutrients, gases, and waste products. Plasma proteins include albumin, globulins, and fibrinogen. **Albumin** makes up 58% of the plasma proteins. Although the osmotic pressure of blood results primarily from sodium chloride,

albumin makes an important contribution. The water balance between blood and tissues is determined by the movement of water into and out of the blood by osmosis. **Globulins** account for 38% of the plasma proteins. Some globulins, such as antibodies and complement, are part of the immune system. Other globulins and albumin function as transport molecules because they bind to molecules, such as hormones, and carry them in the blood throughout the body. Some globulins are clotting factors, which are necessary for the formation of blood clots. **Fibrinogen** is a clotting factor that constitutes 4% of plasma proteins. Activation of clotting factors results in the conversion of fibrinogen into **fibrin**, a threadlike protein that forms blood clots. **Serum** is plasma without the clotting factors. Nutrients in plasma include amino acids, glucose, nucleotides, and lipids that have all been absorbed from the digestive tract. Because lipids are not water soluble and because plasma is mostly water, lipids must combine with molecules called **lipoproteins** to be transported. The different types of lipoproteins are **chylomicrons**, very low density lipoproteins (VLDL), low-density lipoproteins (LDL), and high-density lipoproteins (HDL).

Plasma Components	Functions and Examples
Water	Acts as a solvent and suspending medium for blood components
Proteins	Maintain osmotic pressure (albumin), destroy foreign substances (antibodies and complement), transport molecules (albumin, globulins), and form clots (fibrinogen)
Ions	Involved in osmotic pressure (sodium and chloride ions), membrane potentials (sodium and potassium ions), and acid-base balance (hydrogen, hydroxide, and bicarbonate ions)
Nutrients	Source of energy and "building blocks" of more complex molecules (glucose, amino acids, triglycerides)
Gases	Involved in aerobic respiration (oxygen and carbon dioxide)
Waste products	Break down products of protein metabolism (urea and ammonia salts), red blood cells (bilirubin), and anaerobic respiration (lactic acid)
Regulatory substances	Catalyze chemical reactions (enzymes) and stimulate or inhibit many body functions (hormones)

### 3.4 Formed elements

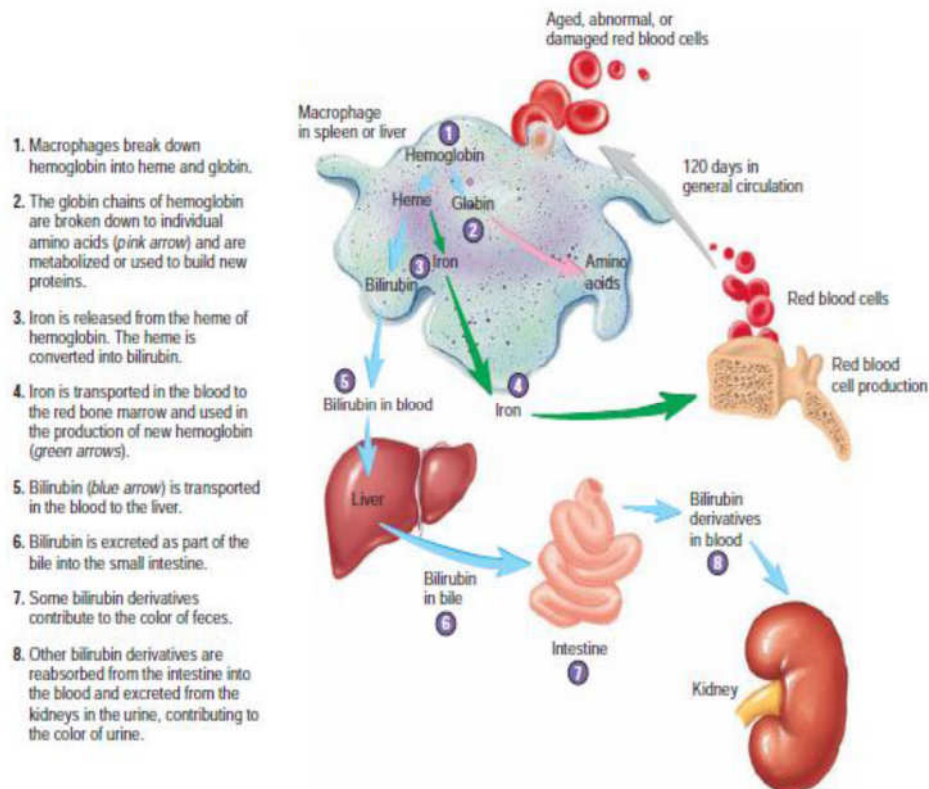
About 95% of the volume of the formed elements consists of **red blood cells (RBCs)**, or **erythrocytes**. Red blood cells transport oxygen and carbon dioxide. Most of the remaining 5% of the volume of the formed elements consists of **white blood cells (WBCs)**, or **leukocytes**. There are five types of white blood cells, which are involved in immunity. **Platelets** or **thrombocytes** are tiny cell fragments making a negligible contribution to plasma volume. Platelets are involved in blood clotting. Red blood cells are 700 times more numerous than white blood cells and 17 times more numerous than platelets.

## Red Blood Cells

Red blood cells, called **erythrocytes**, are biconcave-shaped cells that are small enough to pass through capillaries. Mature red blood cells do not contain nuclei because they must lose their nuclei in order to make room for a pigment called hemoglobin. Hemoglobin's function is to carry oxygen. Hemoglobin that carries oxygen is called **oxyhemoglobin** and is bright red in colour; hemoglobin carries carbodioxide is called **deoxyhemoglobin** and has a darker red color.

A red blood cell count is the number of red blood cells in one cubic millimeter of blood (a cubic millimeter of blood is roughly 20 drops of blood). This count is normally between 4 million and 6.5 million red blood cells. Because the function of a red blood cell is to transport oxygen throughout the body, low count reflects a decreased ability to carry oxygen. This condition is known as **anaemia**.

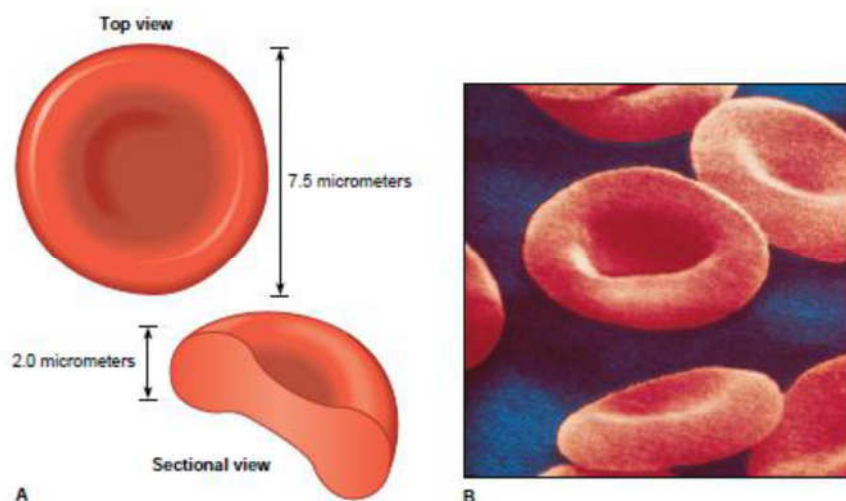
When red blood cells age, macrophages in the liver and spleen destroy them. When a red blood cell is destroyed, a pigment called **biliverdin** is released from the cell. The liver usually converts biliverdin into an orange-colored pigment called **bilirubin**.



**Fig. 2.2:**

Bilirubin is used to make bile, which is needed for the digestion of fats. However, sometimes bilirubin is not used to make bile; instead, it persists in the bloodstream. This causes a person's skin to appear yellowish, which is a condition known as **jaundice**. During development, red blood cells are made in the fetal yolk sac, the liver, and the spleen. However, once a baby is born, most red blood cells are produced in red bone marrow by cells called **hemocytoblasts**. The average life span of a red blood cell is only about 120 days, so red bone marrow is constantly making new cells. The hormone **erythropoietin** is responsible for regulating the production of red blood cells. This hormone is produced by the kidneys and stimulates the red bone marrow to produce new red blood cells. The kidneys release this hormone when oxygen concentrations in the blood get low.

Vitamin B12 and folic acid are two dietary factors that affect red blood cell production. These vitamins are necessary for DNA synthesis, so any actively dividing tissue such as red bone marrow is affected when DNA cannot be produced. Iron is also necessary to make haemoglobin. Too few red blood cells or too little haemoglobin can result in anaemia.



**Fig. 2.3:**

### **Leukocytes (white blood cells)**

The leukocytes, also called *white blood cells*, are the *mobile units* of the body's protective system. They are formed partially in the bone marrow (*granulocytes* and *monocytes* and a few *lymphocytes*) and partially in the lymph tissue (*lymphocytes* and *plasma cells*). After formation, they are transported in the blood to different parts of the body where they are needed. The real value of the white blood cells is that most of them are specifically transported to areas of serious infection and inflammation, thereby providing a rapid and potent defense against infectious agents. As we see later, the granulocytes and monocytes have a special ability to "seek out and destroy" a foreign invader.

White blood cells, which are called **leukocytes**, are divided into two categories: granulocytes and agranulocytes. **Granulocytes** have granules in their cytoplasm and include neutrophils, eosinophils, and basophils. **Agranulocytes** do not have granules in their cytoplasm and include monocytes and lymphocytes.

**Neutrophils** account for about 55% of all white blood cells. They are important for destroying bacteria, viruses, and toxins in the blood. **Eosinophils** account for about 3% of all white blood cells and are effective in getting rid of parasitic infections such as worms. Eosinophils also help control inflammation and allergic reactions. **Basophils** account for less than 1% of all white blood cells. They release substances such as histamine and heparin, which promote inflammation.

**Monocytes** account for about 8% of all white blood cells. They are important for destroying bacteria, viruses, and toxins in the blood. **Lymphocytes** account for about 33% of all white blood cells and provide immunity for the body. A white blood cell count is the number of white blood cells in 1 cubic millimetre of blood. This count is normally between 5000 and 10,000 cells. A white blood cell count above normal is termed **leukocytosis**. This condition often results from bacterial infections. A white blood cell count below normal is called **leukopenia**, which is caused by some viral infections and various other conditions. The white blood cells formed in the bone marrow are stored within the marrow until they are needed in the circulatory system. Then, when the need arises, various factors cause them to be released (these factors are discussed later). Normally, about three times as many white blood cells are stored in the marrow as circulate in the entire blood. This represents about a 6-day supply of these cells.

A differential white blood cell count lists the percentages of the different types of leukocytes in a sample of blood. This is a useful test because the numbers of different white blood cells change in certain diseases. For example, neutrophil numbers increase at the beginning of a bacterial infection but monocyte numbers will not increase until about two weeks after a bacterial infection.

Eosinophil numbers increase during worm infections. In AIDS, lymphocyte numbers fall. Some white blood cells stay in the bloodstream to fight infections while others leave the bloodstream by squeezing through blood vessel walls to reach other tissues. The squeezing of a cell through a blood vessel wall is called **diapedesis**.

### **Neutrophils and macrophages defend against infections**

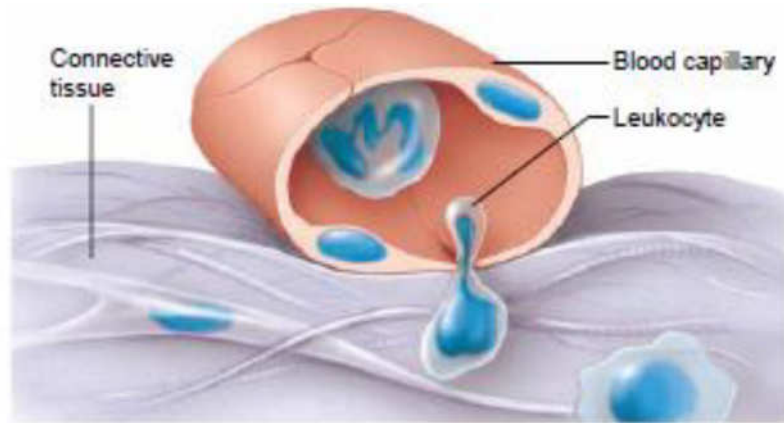
Mainly the neutrophils and tissue macrophages attack and destroy invading bacteria, viruses, and other injurious agents. The neutrophils are mature cells that can attack and destroy bacteria even in the circulating blood. Conversely, the tissue macrophages begin life as blood monocytes, which are immature cells while still in the blood and have little ability to fight infectious agents at that time. However, once they enter the tissues, they begin to swell—sometimes increasing their diameters as much as fivefold—to as great as 60 to 80 micrometers, a size that can barely be seen with the naked eye. These cells are now called *macrophages*, and they are extremely capable of combating disease agents in the tissues.

### **White Blood Cells Enter the Tissue Spaces by Diapedesis.**

Neutrophils and monocytes can squeeze through the pores of the blood capillaries by *diapedesis*. Though a pore is much smaller than a cell, a small portion of the cell slides through the pore at a time; the portion sliding through is momentarily constricted to the size of the pore.

**White Blood Cells Move Through Tissue Spaces by Ameboid Motion.** Both neutrophils and macrophages can move through the tissues by ameboid motion. Some cells move at velocities as great as 40  $\mu\text{m}/\text{min}$ , a distance as great as their own length each minute.

**White Blood Cells Are Attracted to Inflamed Tissue Areas by Chemotaxis.** Many different chemical substances in the tissues cause both neutrophils and macrophages to move toward the source of the chemical. This phenomenon is known as *chemotaxis*. When a tissue becomes inflamed, at least a dozen different products that can cause chemotaxis toward the inflamed area are formed. They include (1) some of the bacterial or viral toxins, (2) degenerative products of the inflamed tissues themselves, (3) several reaction products of the —complement complex activated in inflamed tissues, and (4) several reaction products caused by plasma clotting in the inflamed area, as well as other substances.



**Fig. 2.4: Diapedesis of white blood cell into a tissue**

### Phagocytosis

The most important function of the neutrophils and macrophages is *phagocytosis*, which means cellular ingestion of the offending agent. Phagocytes must be selective of the material that is phagocytized; otherwise, normal cells and structures of the body might be ingested. Whether phagocytosis will occur depends especially on three selective procedures.

### Platelets

**Platelets** or **thrombocytes**, are minute fragments of cells, each consisting of a small amount of cytoplasm surrounded by a cell membrane. They are produced in the red bone marrow from **megakaryocytes** (mega-, large + *karyon*, nucleus + *kytos*, cell), which are large cells. Small fragments of these cells break off and enter the blood as platelets, which play an important role in preventing blood loss. This prevention is accomplished in two ways: (1) the formation of platelet plugs, which seal holes in small vessels, and (2) the formation of clots, which help seal off larger wounds in the vessels. A normal platelet count is between 130,000 and 360,000 platelets per cubic millimetre of blood.

## 3.5 Bleeding control

When a blood vessel is damaged, blood can leak into other tissues and interfere with normal tissue function, or blood can be lost from the body. A small amount of blood loss from the body can be tolerated, and new blood is produced to replace it. If a large amount of blood is lost, death can occur.

**Hemostasis** refers to the stoppage of bleeding. This is important when blood vessels are damaged and bleeding begins. Three processes occur in hemostasis:

(1) Blood vessel spasm, (2) platelet plug formation, and (3) blood coagulation.

### **Vascular Spasm**

**Vascular spasm** is an immediate but temporary constriction of a blood vessel resulting from a contraction of smooth muscle within the wall of the vessel. This constriction can close small vessels completely and stop the flow of blood through them. Damage to blood vessels can activate nervous system reflexes that cause vascular spasms.

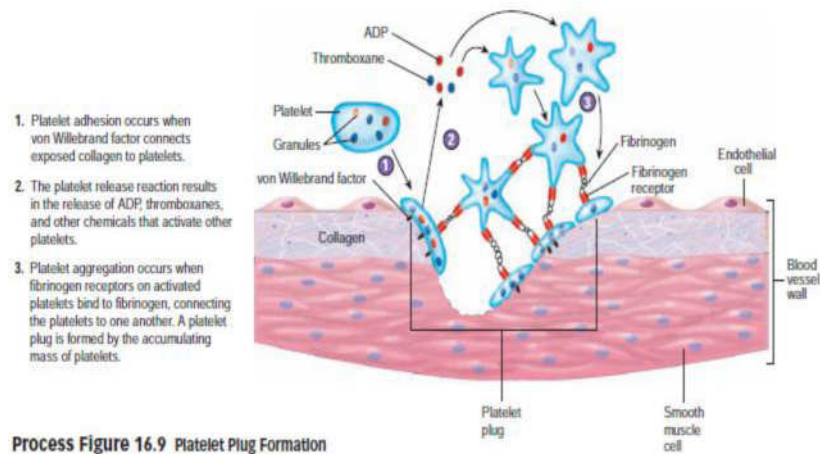
### **Platelet Plugs**

A **platelet plug** is an accumulation of platelets that can seal up a small break in a blood vessel. Platelet plug formation is very important in maintaining the integrity of the circulatory system because small tears occur in the smaller vessels and capillaries many times each day, and platelet plug formation quickly closes them. People who lack the normal number of platelets tend to develop numerous small haemorrhages in their skin and internal organs. The formation of a platelet plug can be described as a series of steps, but in actuality many of these steps occur at the same time. **Platelet adhesion** results in platelets sticking to collagen exposed by blood vessel damage. Most platelet adhesion is mediated through **von willebrand factor**, which is a protein produced, stored, and released by blood vessel endothelial cells. von Willebrand factor forms a bridge between collagen and platelets by binding to platelet surface receptors and collagen. After platelets adhere to collagen, they become activated, change shape, and release chemicals.

In the **platelet release reaction**, platelets release chemicals, such as adenosine diphosphate (ADP) and thromboxane. ADP and thromboxane bind to their respective receptors on the surfaces of platelets, resulting in the activation of the platelets. These activated platelets also release ADP and thromboxanes, which activates more platelets. Thus, a cascade of chemical release activates many platelets.

As platelets become activated, they express surface receptors called **fibrinogen receptors**, which can bind to fibrinogen, a plasma protein. In **platelet aggregation**, fibrinogen forms bridges between the fibrinogen receptors of numerous platelets, resulting in the formation of a platelet plug.

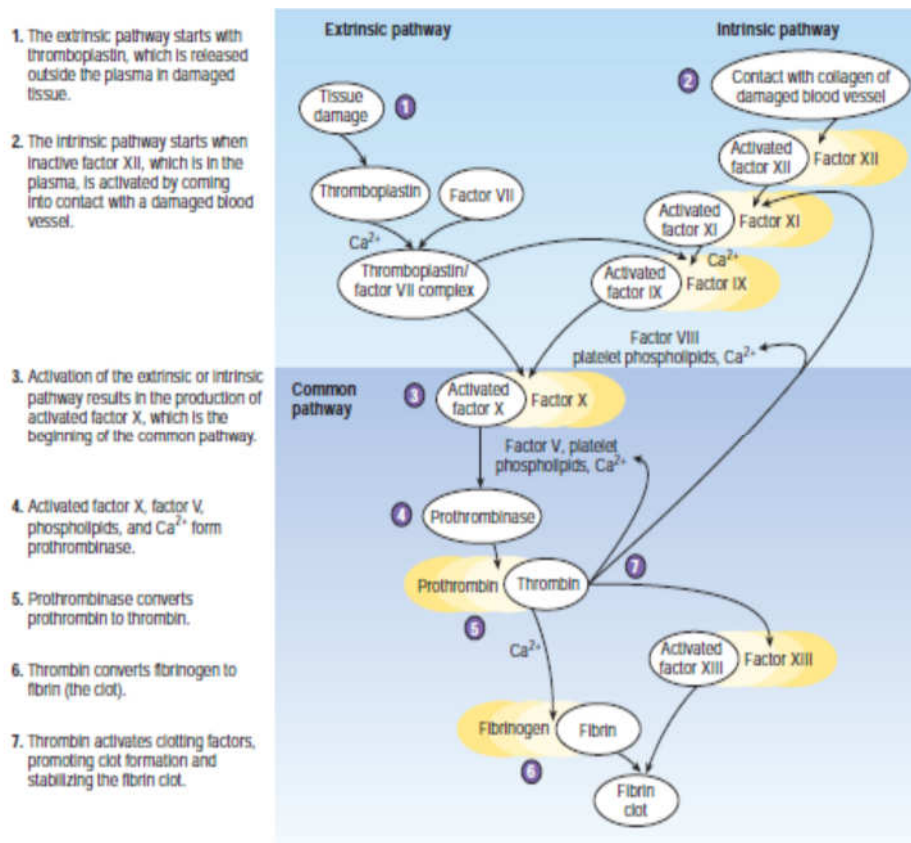




**Fig. 2.5: Platelet plug formation**

Blood Clotting vascular spasm and platelet plugs alone are not sufficient to close large tears or cuts. When blood vessel is severely damaged, blood clotting or coagulation results in the formation blood clots. A blood clot is a network of thread-like protein fibers called **fibrin** that traps blood cells, platelets and fluids. The formation of blood clots depends on a number of proteins called **clotting factors**. Most clotting factors are manufactured in the liver and many of them require vitamin k for their synthesis. In addition, many of the chemical reactions of clot formation require calcium and the chemicals released from platelets. Low levels of vitamin K, low levels of  $Ca^{2+}$ , low numbers of platelets, or reduced synthesis of clotting factors because of liver dysfunction can seriously impair the blood clotting process.

Normally, the clotting factors are in an inactive state and do not cause clotting. After injury, the clotting factors are activated to produce a clot. The activation of clotting proteins begins with the extrinsic and intrinsic pathways. These pathways converge to form the common pathway, which results in the formation of a fibrin clot.



**Fig. 2.6: Process of Clot Formation**

### Extrinsic Pathway

The extrinsic pathway is so named because it begins with chemicals that are outside of, or extrinsic to, the blood. Damaged tissues release a mixture of lipoproteins and phospholipids called **thromboplastin**, also known as **tissue factor (TF)**, or factor III. Thromboplastin, in the presence of Ca<sup>2+</sup>, forms a complex with factor VII, which activates factor X, which is the beginning of the common pathway.

### Intrinsic Pathway

The intrinsic pathway is so named because it begins with chemicals that are inside, or intrinsic to, the blood. Damage to blood vessels can expose collagen in the connective tissue beneath the endothelium lining the blood vessel. When plasma factor XII comes into contact with collagen, factor XII is activated and it stimulates factor XI, which in turn activates factor IX. Activated factor IX joins with factor VIII, platelet phospholipids, and Ca<sup>2+</sup> to activate factor X, which is the beginning of the common pathway.

## Common Pathway

On the surface of platelets, activated factor X, factor V, platelet phospholipids, and  $\text{Ca}^{2+}$  combine to form **prothrombinase**. Prothrombinase converts the soluble plasma protein **prothrombin** into the enzyme **thrombin**. Thrombin converts the soluble plasma protein fibrinogen into the insoluble protein **fibrin**. Fibrin forms the fibrous network of the clot.

## Control of Clot Formation

Without control, clotting would spread from the point of its initiation throughout the entire circulatory system. The blood contains several **anticoagulants**, which prevent clotting factors from forming clots. **Antithrombin** and **heparin**, for example, inactivate thrombin. Without thrombin, fibrinogen is not converted to fibrin, and no clot forms. Normally, there are enough anticoagulants in the blood to prevent clot formation. At an injury site, however, the activation of clotting factors is very rapid. Enough clotting factors are activated that the anticoagulants can no longer prevent a clot from forming. Away from the injury site there are enough anticoagulants to prevent clot formation from spreading.

## The Danger of Unwanted Clots

When platelets encounter damaged or diseased areas of blood vessels or heart walls, an attached clot, called a **thrombus**, can form. A thrombus that breaks loose and begins to float through the circulation is called an **embolus**. Both thrombi and emboli can result in death if they block vessels that supply blood to essential organs, such as the heart, brain, or lungs. Abnormal blood clotting can be prevented or hindered by the injection of anticoagulants, such as heparin, which acts rapidly. Coumadin, or warfarin, acts more slowly than heparin. Warfarin prevents clot formation by suppressing the production of vitamin K-dependent clotting factors by the liver.

## Clot Retraction and Fibrinolysis

After a clot has formed, it begins to condense into a more compact structure by a process known as **clot retraction**. Platelets contain the contractile proteins actin and myosin, which operate in a fashion similar to that of the actin and myosin in muscle. Platelets form small extensions that attach to fibrin through surface receptors. Contraction of the extensions pulls on the fibrin and is responsible for clot retraction. **Serum**, which is plasma without the clotting factors, is squeezed out of the clot during clot retraction. Retraction of the clot pulls the edges of

the damaged blood vessel together, helping stop the flow of blood, reducing the probability of infection, and enhancing healing. The damaged vessel is repaired by the movement of fibroblasts into the damaged area and the formation of new connective tissue. In addition, epithelial cells around the wound divide and fill in the torn area.

### Clot dissolution

Clots are dissolved by a process called **fibrinolysis** (fibrino-, fi ber- + *lysis*, dissolution) . **Plasminogen**) is an inactive plasma protein produced by the liver.

Thrombin, other clotting factors activated during clot formation, and **tissue plasminogen activator (t-PA)** released from surrounding tissues can stimulate the conversion of plasminogen to its active form, **plasmin**. Over a period of a few days, plasmin slowly breaks down the fibrin.

## 3.6 Blood typing

The ABO blood group consists of four different blood types: A, B, AB, and O. They are distinguished from each other in part by their antigens and antibodies.

**Agglutination** is the clumping of red blood cells following a blood transfusion. This clumping is not desirable because it leads to severe anemia. Agglutination occurs because proteins called *antigens* on the surface of red blood cells bind to antibodies in plasma. To prevent agglutination, antigens should not be mixed with antibodies that will bind to them. Fortunately, most antibodies do not bind to antigens on blood cells; only very specific ones bind to them.

- Type A People with type A blood have antigen A on the surface of their red blood cells. They also have antibody B in their plasma. Antibody B will only bind to antigen B.
- Type B People with type B blood have antigen B on the surface of their red blood cells. They also have antibody A in their plasma. If a person with type A blood is given type B blood, then the antibody B in the recipient's blood will bind with the red blood cells of the donor blood because those cells have antigen B on their surfaces. Therefore, agglutination occurs, and the donated red blood cells are destroyed. This is why a person with type A blood should not be given type B blood (and vice versa).
- Type AB People with type AB blood have both antigen A and antigen B on the surface of their red blood cells. They have neither antibody A nor antibody B in their plasma. People with type AB blood are called universal recipients, because most of

them can receive all ABO blood types. They can receive these blood types because they lack antibody A and antibody B in their plasma, so there is no reaction with antigens A and B of the donor blood.

- Type O People with type O blood have neither antigen A nor antigen B on the surface of their red blood cells. However, they do have both antibody A and antibody B in their plasma. People with type O blood are called universal donors because their blood can be given to most people regardless of recipients' blood type. Type O blood will not agglutinate when given to other people because it does not have the antigens to bind to antibody A or antibody B.

**Table 2.1:**

Blood Type	Antigen Present	Antibody Present	Blood That Can Be Received
A	A	B	A and O
B	B	A	B and O
AB	AB	None	A, B, AB, and O
O	None	A and B	O

*The above table shows ABO blood group*

### The Rhesus Factor

The **Rh antigen** is a protein first discovered on red blood cells of the Rhesus monkey, hence the name Rhesus. People who are Rh-positive have red blood cells that contain the Rh antigen. People who are Rh-negative have red blood cells that do not contain the Rh antigen. If a person who is Rh-negative is given Rh-positive blood, then the Rh-negative person's blood will make antibodies that bind to the Rh antigens. If the Rh-negative person is given Rh-positive blood a second time, the antibodies will bind to the donor cells and agglutination will occur. Clinically, it is very important for a female to know her Rh type.

If an Rh-negative female mates with an Rh-positive male, there is a fifty-fifty chance that her fetus will be Rh-positive. When the blood of a fetus who is Rh-positive mixes with the blood of a mother who is Rh-negative, the mother develops antibodies against the fetus's red blood cells. The first Rh-positive fetus usually does not suffer from these antibodies because it takes so long for the mother's body to generate them. However, if the mother conceives a second Rh-positive fetus, the fetus's blood will be attacked by the antibodies right away. The second fetus then develops a condition called **erythroblastosis fetalis**, and the baby is born severely anemic. Erythroblastosis fetalis is prevented by

giving an Rh-negative woman the drug **RhoGAM**. RhoGAM prevents an Rh-negative mother from making antibodies against the Rh antigen.

## 4.0 CONCLUSION

The blood is made up of the plasma and the formed elements. The formed elements are the red blood cells (RBCs), or erythrocytes, the five types of white blood cells (WBCs) or leukocytes and the Platelets or thrombocytes. Structural

## 5.0 SUMMARY

In this unit, you have learnt in details the structure and various functions of blood, the composition of blood, the various components of plasma and the formed elements. We also discussed bleeding control, blood typing and its importance. We finally ended this discussion with information about the rhesus factor and its clinical consequences. I sincerely hope that you have not only enjoyed this unit but gained a lot from it as well.

## 6.0 TUTOR MARKED ASSIGNMENTS

### 6.1 Activity (to be submitted in your portfolio)

- Visit the blood bank and document the procedure of blood banking.
- Solomon Abubakar, a physical education major, wanted to improve his performance in an upcoming marathon race. About 6 weeks before the race, he donated 500 mL of blood, and the formed elements were separated from the plasma. The formed elements were frozen, and the plasma was re-infused into his body. Just before the competition, the formed elements were thawed and injected into his body. Explain why this procedure, called blood doping or blood boosting, would help Solomon's performance. Can you suggest any possible bad effects?
- Visit the Chemical Pathology laboratory in your hospital or any secondary or tertiary institution close to you. Interview the laboratory scientist on the precautionary measures adopted to prevent contact with blood. Add your report to your portfolio.

### 6.2 Please answer the following questions:

- i. Describe the nature of blood as part of the cardiovascular system and highlight its functions.
- ii. What is the blood volume of an average person?
- iii. What are the conditions that can cause a change in haematocrit?

- iv. Can haemoglobin bind other gas molecules apart from oxygen? If yes, explain how.
- v. What are the two pathways that initiate clotting?

Hutchinson, M., Mallat, J., Marieb, E.N., Wilhelm P.B. (2007). A Brief Atlas of the Human Body. Sna Franscisco: Pearson Education Inc.

Katherine M. A. Rogers and William N. Scott (2011) Nurses! Test Yourself in Anatomy and Physiology

Kathryn A. Booth, Terri. D. Wyman (2008) Anatomy, Physiology, and Pathophysiology for Allied Health

Keith L Moore, Persuade T.V.N (2018), The Developing Human Clinically Oriented Embryology 11th Edition Lippincott Williams & Wilkins

Kent M. Van De Graff, R.Ward Rhees, Sidney Palmer (2010) Schaum's Outline of human Anatomy and Physiology 3rd edition.

Philip Tate (2012) Seeley's Principles of Anatomy & Physiology 2nd ed.

Sadler T.W (2012), Langman's Medical Embryology 12th edition.

Seeley's Principles of Anatomy & Physiology, Second edition Published by McGraw-Hill, a business unit of The McGraw-Hill Companies, Inc., 1221 Avenue of the Americas, New York, NY 10020. Copyright c 2012- Chapter 17&18

## **UNIT 3 LYMPHATIC SYSTEM**

### **CONTENT**

- 1.0 Introduction
- 2.0 Objectives
- 3.0 Main Content
  - 3.1 Functions of the lymphatic system
  - 3.2 Rate of lymph flow
  - 3.3 Lymphatic pathway
  - 3.4 Lymphatic tissues and organs
- 4.0 Conclusion
- 5.0 Summary
- 6.0 Tutor Marked Assignments
- 7.0 References and other resources

### **1.0 INTRODUCTION**

Most people are not aware of the existence of the lymphatic system and those that are aware do not fully understand its functions. It is one of the most important systems for survival as one of the soldiers that defends your body against invading enemies. You may be wondering how true that is, but relax, at the end of our discussion, you will agree with me. One of the basic themes of life is that many organisms consume, or use, other organisms to survive. Humans are host to any kinds of organisms, including microorganisms, such as bacteria, viruses, fungi, and protozoans; insects; and worms. Often, parasites harm humans, causing disease and sometimes death. For simplicity, the term pathogen is used for any parasite or substance that causes disease. The lymphatic system and immunity are the body's defense systems against threats arising from inside and outside the body.

### **2.0 OBJECTIVES**

At the end of this unit, you should be able to:

- Describe the functions of the lymphatic system
- Explain in details how lymph is formed
- List the major lymphatic vessels in the order lymph flows through them.
- Describe the structure and functions of diff use lymphatic tissue, lymphatic nodules, tonsils, lymph nodes, spleen, and thymus gland



### 3.0 MAIN CONTENT

#### 3.1 Functions of the lymphatic system

The lymphatic system represents an accessory route through which fluid can flow from the interstitial spaces into the blood. Most important, the lymphatics can carry proteins and large particulate matter away from the tissue spaces, neither of which can be removed by absorption directly into the blood capillaries. This return of proteins to the blood from the interstitial spaces is an essential function without which we would die within about 24 hours.

The functions of the lymphatic system includes:

- *Fluid balance.* Approximately 30 L of fluid pass from the blood capillaries into the interstitial spaces each day, whereas only 27 L pass from the interstitial spaces back into the blood capillaries. If the extra 3 L of fluid were to remain in the interstitial spaces, edema would result, causing tissue damage and eventual death. Instead, the 3L of fluid enters the lymphatic capillaries, where the fluid is called **lymph**, and it passes through the lymphatic vessels back to the blood. In addition to water, lymph contains solutes derived from two sources: (1) Substances in plasma, such as ions, nutrients, gases, and some proteins, pass from blood capillaries into the interstitial fluid and become part of the lymph and (2) substances derived from cells, such as hormones, enzymes, and waste products, are also found in the lymph.
- *Fat absorption.* The lymphatic system absorbs fats and other substances from the digestive tract. Lymphatic capillaries called **lacteals** are located in the lining of the small intestine. Fats enter the lacteals and pass through the lymphatic vessels to the venous circulation. The lymph passing through these lymphatic vessels, called **chyle**, has a milky appearance because of its fat content.
- *Defense.* Pathogens are filtered from lymph by lymph nodes and from blood by the spleen. In addition, lymphocytes and other cells are capable of destroying pathogens. The components of this system includes lymph, lymphatic vessels, lymphatic tissue, lymphatic nodules, lymph nodes, tonsils, the spleen, and the thymus.

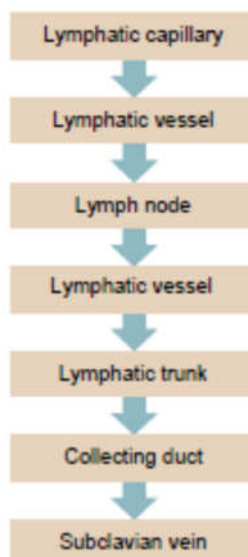
#### 3.2 Rate of lymph flow

About 100 milliliters per hour of lymph flows through the *thoracic duct* of a resting human, and approximately another 20 milliliters flows into the circulation each hour through other channels, making a total estimated lymph flow of about 120 ml/hr or 2 to 3 liters per day.

The fluid that returns to the circulation by way of the lymphatics is extremely important because substances of high molecular weight, such as proteins, cannot be absorbed from the tissues in any other way, although they can enter the lymphatic capillaries almost unimpeded. The reason for this is a special structure of the lymphatic capillaries is because the endothelial cells of the lymphatic capillary attached by *anchoring filaments* to the surrounding connective tissues.

### 3.3 Lymphatic pathway

The lymphatic system, unlike the circulatory system, does not circulate fluid to and from tissues. Instead, the lymphatic system carries fluid in one direction, from tissues to the circulatory system. Fluid moves from blood capillaries into the interstitial spaces. Most of the fluid returns to the blood, but some of the fluid moves from the interstitial spaces into lymphatic capillaries to become lymph. The **lymphatic capillaries** are tiny, closed-ended vessels consisting of simple squamous epithelium. Lymphatic capillaries differ from blood capillaries in that they lack a basement membrane and the cells of the simple squamous epithelium slightly overlap and are attached loosely to one another. Two things occur as a result of this structure. First, the lymphatic capillaries are far more permeable than blood capillaries, and nothing in the interstitial fluid is excluded from the lymphatic capillaries. Second, the lymphatic capillary epithelium functions as a series of one-way valves that allow fluid to enter the capillary but prevent it from passing back into the interstitial spaces.



**Fig. 3.1:** *The lymphatic pathway*

Lymphatic capillaries are in most tissues of the body. Exceptions are the central nervous system, bone marrow, and tissues without blood vessels,

such as the epidermis and cartilage. A superficial group of lymphatic capillaries drains the dermis and subcutaneous tissue, and a deep group drains muscle, viscera, and other deep structures.

The lymphatic capillaries join to form larger **lymphatic vessels**, which resemble small veins. Small lymphatic vessels have a beaded appearance because of one-way valves that are similar to the valves of veins. When a lymphatic vessel is compressed, the valves prevent the backward movement of lymph. Consequently, compression of lymphatic vessels causes lymph to move forward through them. Three factors cause compression of the lymphatic vessels:

- the periodic contraction of smooth muscle in the lymphatic vessel wall,
- the contraction of surrounding skeletal muscle during activity, and
- pressure changes in the thorax during respiration.

The lymphatic vessels converge and eventually empty into the blood at two locations in the body. Lymphatic vessels from the right upper limb and the right half of the head, neck, and chest empty into the right subclavian vein. These lymphatic vessels often converge to form a short duct, 1 cm in length, called the **right lymphatic duct**, which connects to the subclavian vein. Lymphatic vessels from the rest of the body enter the **thoracic duct**, which empties into the left subclavian vein. The thoracic duct is the largest lymphatic vessel. It is approximately 38–45 cm in length, extending from the twelfth thoracic vertebra to the base of the neck.

### 3.4 Lymphatic tissues and organs

The lymphatic organs include the tonsils, lymph nodes, spleen, and thymus. Lymphatic organs contain lymphatic tissue, which consists primarily of lymphocytes, but it also includes macrophages, dendritic cells, reticular cells, and other cell types.

Lymphocytes are a type of white blood cell. When the body is exposed to pathogens, the lymphocytes divide, increase in number, and are part of the immune response that destroys pathogens. Lymphatic tissue also has very fine collagen fibers, called reticular fibers, which are produced by reticular cells. Lymphocytes and other cells attach to these fibers. When lymph or blood filters through lymphatic organs, the fiber network traps pathogens in the fluid. Lymphatic tissue surrounded by a connective tissue capsule is said to be encapsulated, whereas lymphatic tissue without a capsule is called nonencapsulated. Lymphatic organs with a capsule include lymph nodes, the spleen, and the thymus.

Nonencapsulated lymphatic tissue includes diffuse lymphatic tissue, lymphatic nodules, Peyer patches, and the tonsils. Nonencapsulated lymphatic tissue is found in and beneath the mucous membranes lining the digestive, respiratory, urinary, and reproductive tracts. In these locations, the lymphatic tissue is well located to intercept pathogens as they enter the body.

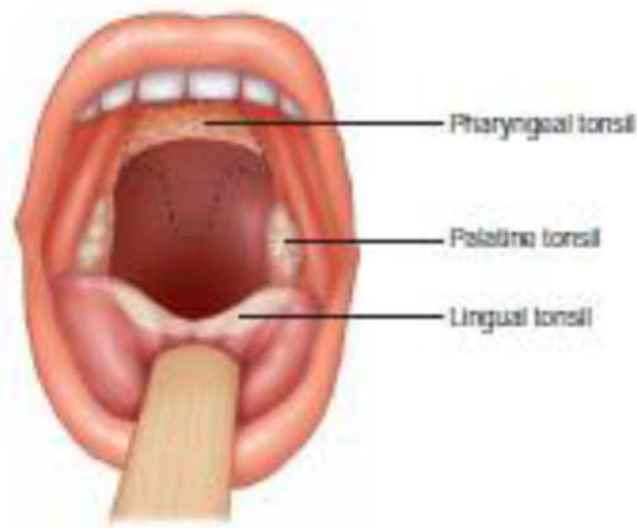
### **Diffuse Lymphatic Tissue and Lymphatic Nodules**

Diffuse lymphatic tissue has no clear boundary, blends with surrounding tissues, and contains dispersed lymphocytes, macrophages, dendritic cells, and other cells. It is located deep to mucous membranes, around lymphatic nodules, and within the lymph nodes and spleen. Lymphatic nodules are denser arrangements of lymphatic tissue organized into compact, somewhat spherical structures, ranging in size from a few hundred microns to a few millimeters or more in diameter. Lymphatic nodules are numerous in the loose connective tissue of the digestive, respiratory, urinary, and reproductive systems. Peyer patches are aggregations of lymphatic nodules found in the distal half of the small intestine and the appendix. Lymphatic nodules are also found within lymph nodes and the spleen.

### **Tonsils**

**Tonsils** are large groups of lymphatic nodules and diffuse lymphatic tissue located deep to the mucous membranes within the pharynx (throat). The tonsils provide protection against bacteria and other potentially harmful material entering the pharynx from the nasal or oral cavities.

In adults, the tonsils decrease in size and eventually may disappear. There are three groups of tonsils. The **palatine tonsils** are located on each side of the posterior opening of the oral cavity. They usually are referred to as “the tonsils.” The **pharyngeal tonsil** is located near the internal opening of the nasal cavity. When the pharyngeal tonsil is enlarged, it is commonly referred to as the **adenoid** or **adenoids**. An enlarged pharyngeal tonsil can interfere with normal breathing. The **lingual tonsil** is on the posterior surface of the tongue.



**Fig. 3.2:** *The tonsils*

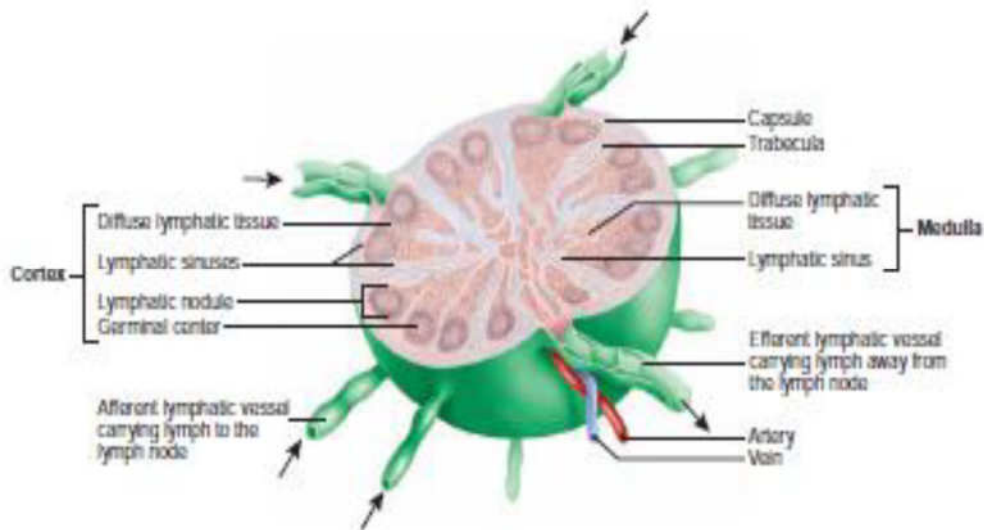
### Lymph Nodes

Lymph nodes are very small, glandular structures that usually cannot be felt very easily. They are located along the paths of larger lymphatic vessels and are spread throughout the body, but they do not occur in the nervous system. One side of a lymph node, called the hilum, is indented. Nerves and blood vessels enter the node through the hilum. They are small, round, or bean-shaped structures, ranging in size from 1–25 mm long. They filter the lymph, removing bacteria and other materials. In addition, lymphocytes congregate, function, and proliferate within lymph nodes. Approximately 450 lymph nodes are found throughout the body. **Superficial lymph nodes** are in the subcutaneous tissue, and **deep lymph nodes** are everywhere else. There are three superficial groups of lymph nodes on each side of the body: inguinal nodes in the groin, axillary nodes in the axilla (armpit), and cervical nodes in the neck.

A dense connective tissue **capsule** surrounds each lymph node. Extensions of the capsule, called **trabeculae**, subdivide lymph nodes into compartments containing diffuse lymphatic tissue, lymphatic nodules, and lymphatic sinuses. **Lymphatic sinuses** are spaces between lymphatic tissue containing macrophages and dendritic cells within a network of reticular fibers. The outer **cortex** consists of lymphatic nodules separated by diffuse lymphatic tissue and lymphatic sinuses. The inner **medulla** is organized into branching, irregular strands of diffuse lymphatic tissue separated by lymphatic sinuses. Two important cell types are found inside the node— macrophages and lymphocytes. Macrophages digest unwanted pathogens in the lymph as it sits in the node, and the lymphocytes start an immune response against the

pathogen. Lymph nodes are also responsible for the generation of some lymphocytes.

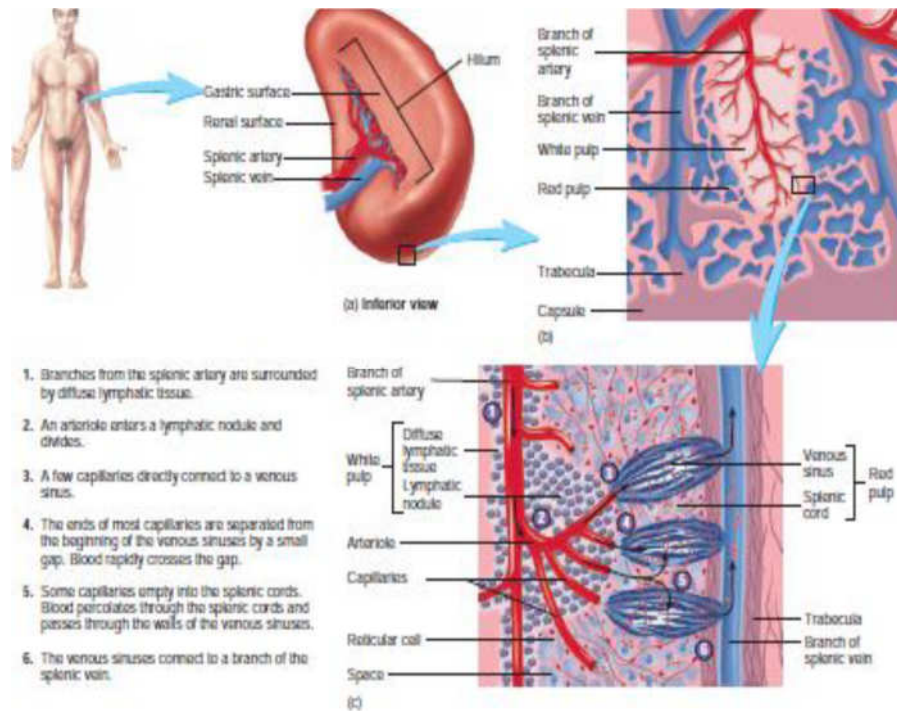
Lymph nodes are the only structures to filter lymph. They have **afferent lymphatic vessels**, which carry lymph to the lymph nodes, where it is filtered, and **efferent lymphatic vessels**, which carry lymph away from the nodes. As lymph moves through the lymph nodes, macrophages remove the pathogens from the lymph and lymphocytes respond to the pathogens by dividing and differentiating into cells that can kill pathogens. The lymph nodules containing the rapidly dividing lymphocytes are called **germinal centers**. The newly produced lymphocytes are released into the lymph and eventually reach the blood, where they circulate and enter infected tissues and other lymphatic tissues.



**Fig. 3.3:** *The lymph node*

## The Spleen

The spleen is the largest lymphatic organ. It is located in the upper left portion of the abdominal cavity. The spleen is filled with blood, macrophages, and lymphocytes. It filters blood in much the same way that lymph nodes filter lymph. The spleen also removes worn-out red blood cells from the bloodstream. The **spleen** is roughly the size of a clenched fist. It has an outer **capsule** of dense connective tissue and a small amount of smooth muscle. **Trabeculae** from the capsule divide the spleen into small, interconnected compartments containing two specialized types of tissue called **white pulp** and **red pulp**. Approximately one-fourth of the volume of the spleen is white pulp and three-fourths is red pulp. Branches of the **splenic artery** enter the spleen and their branches follow the various trabeculae into the spleen to supply white pulp within the compartments.



**Fig. 3.4: The spleen**

Blood flows from white pulp into red pulp. Veins from the red pulp converge, forming the splenic vein, which exits the spleen.

### Functions

The spleen destroys defective red blood cells and detects and responds to foreign substances in the blood. As red blood cells age, they lose their ability to bend and fold. Consequently, the cells can rupture as they pass slowly through the fibrous network of the splenic cords or the intercellular slits of the venous sinuses. Splenic macrophages then phagocytize the cellular debris. Foreign substances in the blood passing through the spleen can stimulate an immune response because of the presence in the white pulp of lymphocytes.

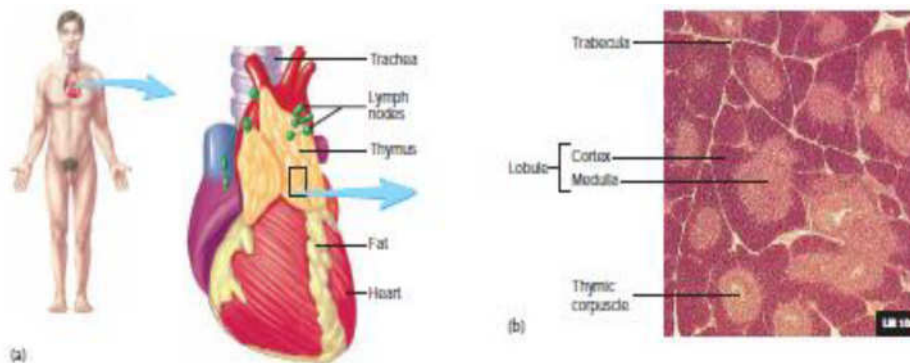
The spleen also functions as a blood reservoir, holding a small volume of blood. For example, during exercise splenic volume can be reduced by 40%–50%. The resulting small increase in circulating red blood cells can promote better oxygen delivery to muscles during exercise or emergency situations.

### Thymus

The **thymus** is a bi-lobed gland located in the superior mediastinum, the partition dividing the thoracic cavity into left and right parts. Each lobe of the thymus is surrounded by a thin connective tissue **capsule**. **Trabeculae** extend from the capsule into the substance of the gland,

dividing it into **lobules**. Unlike other lymphatic tissue, which has a fibrous network of reticular fibers, the framework of thymic tissue consists of epithelial cells. The processes of the epithelial cells are joined by desmosomes, and the cells form small, irregularly shaped compartments filled with lymphocytes. Near the capsule and trabeculae, the lymphocytes are numerous and form dark-staining areas of the lobules called the **cortex**. A lighter-staining, central portion of the lobules, called the **medulla**, has fewer lymphocytes. The medulla also contains rounded epithelial structures, called **thymic corpuscles** (Hassall corpuscles), which may be remnants of degenerating cells. The thymus is the site of the maturation of T cells. Large numbers of lymphocytes are produced in the thymus, but many degenerate. The surviving T cells enter the blood and travel to other lymphatic tissues where they act against pathogens.

The thymus increases in size until the first year of life, remains approximately the same size until 60 years of age, and then decreases in size. Although the size of the thymus is fairly constant throughout much of life, functional thymic tissue is gradually replaced with adipose tissue. By age 50 the ability to produce new, mature T cells is reduced to 20%, and by age 70 it is mostly gone.



**Fig. 3.5:** *The thymus*

## 5.0 SUMMARY

In this unit, we have discussed the three interrelated functions of the lymphatic system – fluid balance, fat absorption and defense. We also learnt that the rate of flow of lymph is 120ml/hr or 2 to 3l per day. We learnt that the lymphatic system does not circulate fluid to and from tissues but carries fluid in one direction, from tissues to the circulatory system. We have learnt about the lymphatic pathway, lymphatic tissues and organs which includes tonsils, lymph nodes, spleen and thymus, each of these were discussed in details.



## Clinical correlates

- Enlarged tonsils make swallowing difficult, and infected tonsils stimulate inflammation that causes a sore throat. An enlarged adenoid restricts air flow, causing snoring and sleeping with the mouth open. In addition, an enlarged and/or infected adenoid is associated with chronic middle ear infections because the openings to the auditory tubes are located next to the adenoid. Chronic middle ear infections are associated with loss of hearing, which in turn affects speech development. A **tonsillectomy** is the removal of the palatine tonsils, and an **adenoidectomy** is the removal of the adenoid. Both procedures performed at the same time is called a T&A.
- **Lymphadenitis** is an inflammation of the lymph nodes, causing them to become enlarged and tender. It is an indication that pathogens are being trapped and destroyed within the lymph nodes.
- **Lymphangitis** is an inflammation of the lymphatic vessels. This often results in visible red streaks in the skin that extend away from the site of infection. If pathogens pass through the lymphatic vessels and lymph nodes to reach the blood, **septicemia**, or blood poisoning, can result.
- A **lymphoma** is a neoplasm (tumor) of lymphatic tissue that is almost always malignant. Lymphomas are usually divided into two groups: **Hodgkin disease** and all other lymphomas, which are called **non-Hodgkin lymphomas**. The different types of lymphomas are diagnosed based on their histological appearance and cell of origin. Typically, a lymphoma begins as an enlarged, painless mass of lymph nodes. Enlargement of the lymph nodes can compress surrounding structures and produce complications. Immunity is depressed, and the patient has an increased susceptibility to infections. Fortunately, treatment with drugs and radiation is effective for many people who suffer from lymphoma.
- Although the spleen is protected by the ribs, it is often ruptured in traumatic abdominal injuries. A ruptured spleen can cause severe bleeding, shock, and death. Surgical intervention may stop the bleeding. Cracks in the spleen are repaired using sutures and blood clotting agents. Mesh wrapped around the spleen can hold it together. A **splenectomy**, removal of the spleen, may be necessary if these techniques do not stop the bleeding. Other lymphatic organs and the liver compensate for the loss of the spleen's functions.

## 6.0 TUTOR MARKED ASSIGNMENTS

### 6.1 Activity

1. Complete the specific assignments with regards to inspection and dissection of the various organs listed here in the Anatomy laboratory and report your work as directed by your Instructor.
2. Inspect the tonsil of 10 persons and report what you see in your note.

### 6.2 Please answer the following questions:

1. List 5 functions of the lymphatic system
2. Describe the composition of the lymph
3. Identify the major lymphatic vessels in the body
4. Outline the lymphatic pathways
5. With a well labelled diagram, describe the spleen, thymus and a lymph node

## 7.0 REFERENCES AND OTHER RESOURCES

Hutchinson, M., Mallat, J., Marieb, E.N., Wilhelm P.B. (2007). A Brief Atlas of the Human Body. Sna Franscisco: Pearson Education Inc.

Katherine M. A. Rogers and William N. Scott (2011) Nurses! Test Yourself in Anatomy and Physiology

Kathryn A. Booth, Terri. D. Wyman (2008) Anatomy, Physiology, and Pathophysiology for Allied Health

Keith L Moore, Persuade T.V.N (2018), The Developing Human Clinically Oriented Embryology 11th Edition Lippincott Williams & Wilkins

Kent M. Van De Graff, R.Ward Rhees, Sidney Palmer (2010) Schaum's Outline of human Anatomy and Physiology 3rd edition.

Philip Tate (2012) Seeley's Principles of Anatomy & Physiology 2nd ed.

Sadler T.W (2012), Langman's Medical Embryology 12th edition.

Seeley's Principles of Anatomy & Physiology, Second edition Published by McGraw-Hill, a business unit of The McGraw-Hill Companies, Inc., 1221 Avenue of the Americas, New York, NY 10020. Copyright c 2012- Chapter 17&18

## **MODULE 2      RESPIRATORY SYSTEM**

### **Introduction**

From our first breath at birth, the rate and depth of our breathing are unconsciously matched to our activities, whether studying, sleeping, talking, eating, or exercising. We can voluntarily stop breathing, but within a few seconds we must breathe again. Breathing is so characteristic of life that, along with the pulse, it is one of the first things we check for to determine if an unconscious person is alive. Breathing is necessary because all living cells of the body require oxygen and produce carbon dioxide.

### **Module objectives**

At the end of this module, you will be able to:

- i.      Discuss the structural components of the respiratory system

### **Contents**

Unit 1	Anatomy of the lungs
Unit 2	Developmental anatomy of the lungs
Unit 3	Anatomy of the diaphragm and mediastinum

## **UNIT 1      ANATOMY OF THE LUNGS**

### **CONTENT**

1.0	Introduction
2.0	Objectives
3.0	Main Content
3.1	Anatomical position of the lungs
3.2	Tracheobronchial tree
3.3	Vasculature of lungs and pleurae
3.4	Nerves of the lungs and pleurae
4.0	Conclusion
5.0	Summary
6.0	Tutor Marked Assignments
7.0	References and other resources

## 1.0 INTRODUCTION

I am sure that you have some background knowledge about the anatomy and the functions of the lungs. Breathing is so fundamental to life that when it ceases, life stops. Deviations in the structure or function of the respiratory system compromises life. Adequate knowledge of the structures of the various organs are also needed by the nurse to pre-empt, prevent, diagnose early and make appropriate plans and to intervene to achieve respiratory sufficiency in clients. In this unit, you will learn that the respiratory system performs other functions apart from breathing and smelling.

## 2.0 OBJECTIVES

At the end of this unit, you should be able to:

- Draw, label and describe various organs (including the functions) that make up the respiratory system
- Identify the components of the upper and lower respiratory tract
- Describe the trachea-brachial tree
- Explain the vasculature of the lungs and pleural
- Describe the nerve supply of the lungs and the pleural
- Explain the cough reflex

## 3.0 MAIN CONTENT

### 3.1 Anatomical position of the lungs

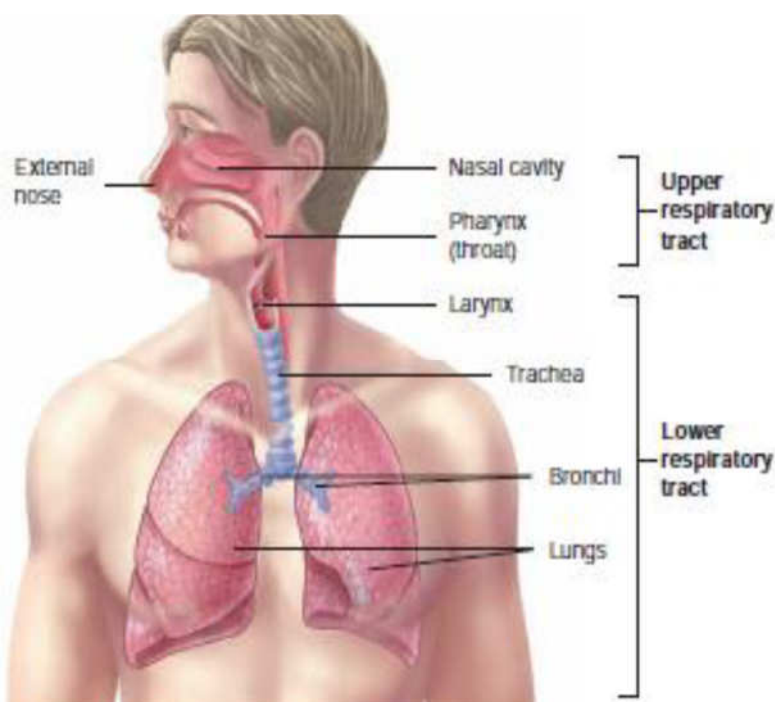
Respiration is necessary because all living cells of the body require oxygen and produce carbon dioxide. The respiratory system assists in gas exchange and performs other functions as well:

- i. *Gas exchange.* The respiratory system allows oxygen from the air to enter the blood and carbon dioxide to leave the blood and enter the air. The cardiovascular system transports oxygen from the lungs to the cells of the body and carbon dioxide from the cells of the body to the lungs. Thus, the respiratory and cardiovascular systems work together to supply oxygen to all cells and to remove carbon dioxide.
- ii. *Regulation of blood pH.* The respiratory system can alter blood pH by changing blood carbon dioxide levels.
- iii. *Voice production.* Air movement past the vocal folds makes sound and speech possible.
- iv. *Olfaction.* The sensation of smell occurs when airborne molecules are drawn into the nasal cavity.

- v. *Protection.* The respiratory system provides protection against some microorganisms by preventing their entry into the body and by removing them from respiratory surfaces.

The organs of the respiratory system are the nose, pharynx, larynx, trachea, bronchial tree (including the bronchi and bronchioles), and the lungs. The nose is made of bones and cartilage and the skin covering them. The openings of the nose are called nostrils. The hairs of the nostrils prevent large particles from entering the nose through air. Although air frequently passes through the oral cavity, it is considered to be part of the digestive system instead of the respiratory system.

The **upper respiratory tract** consists of the external nose, nasal cavity, pharynx, and associated structures, and the **lower respiratory tract** consists of the larynx, trachea, bronchi, and lungs. These are not official anatomical terms, however, and there are several alternate definitions. For example, one alternate definition places the larynx in the upper respiratory tract. The diaphragm and the muscles of the thoracic and abdominal walls are responsible for respiratory movements.



**Fig. 1.1:** *The respiratory system*

The nose, consists of the external nose and the nasal cavity. The external nose is the visible structure that forms a prominent feature of the face. The largest part of the external nose is composed of hyaline cartilage plates, and the bridge of the nose consists of bones. The nasal cavity extends from the nares to the choanae. The nostrils, are the external openings of the nasal cavity and the choanae are the openings into the pharynx. The anterior part of the nasal cavity, just inside each nostrils, is

the **vestibule**. The **hard palate** is a bony plate covered by a mucous membrane that forms the floor of the nasal cavity. It separates the nasal cavity from the oral cavity. The **nasal septum** is a partition of bone and cartilage dividing the nasal cavity into right and left parts. A deviated nasal septum occurs when the septum bulges to one side. Three bony ridges, called **conchae**, (resembling a conch shell), are present on the lateral walls on each side of the nasal cavity. Beneath each concha is a passageway called a **meatus**. Within the superior and middle meatus are openings from the various **paranasal sinuses** and the opening of a **nasolacrimal duct** is within each inferior meatus. Sensory receptors for the sense of smell are found in the superior part of the nasal cavity

The lungs are the vital organs of respiration. Their main function is to oxygenate the blood by bringing inspired air into close relation with the venous blood in the pulmonary capillaries. Although cadaveric lungs may be shrunken, firm or hard, and discolored, healthy lungs in living people are normally light, soft, and spongy, and fully occupy the pulmonary cavities. They are also elastic and recoil to approximately one third their size when the thoracic cavity is opened.

The **pharynx** is the common passageway of both the digestive and the respiratory systems. It receives air from the nasal cavity and receives air, food, and drink from the oral cavity. Inferiorly, the pharynx is connected to the respiratory system at the larynx and to the digestive system at the esophagus. The pharynx is divided into three regions: the nasopharynx, the oropharynx, and the laryngopharynx.

The **larynx** is located in the anterior part of the throat and extends from the base of the tongue to the trachea. It is a passageway for air between the pharynx and the trachea. The larynx is connected by membranes and/or muscles superiorly to the hyoid bone and consists of an outer casing of nine cartilages connected to one another by muscles and ligaments. Three of the nine cartilages are unpaired, and six of them form three pairs.

The largest of the cartilages is the unpaired **thyroid cartilage** or Adam's apple. The most inferior cartilage of the larynx is the unpaired **cricoid cartilage**, which forms the base of the larynx on which the other cartilages rest. The third unpaired cartilage is the **epiglottis**.

The larynx prevents the entry of swallowed materials into the lower respiratory tract and regulates the passage of air into and out of the lower respiratory tract. During swallowing, the epiglottis tips posteriorly until it lies below the horizontal plane and covers the opening into the larynx. Thus, food and liquid slide over the epiglottis toward the esophagus. The most important event for preventing the entry of

materials into the larynx, however, is the closure of the vestibular and vocal folds. That is, the vestibular folds move medially and come together, as do the vocal folds. The closure of the vestibular and vocal folds can also prevent the passage of air, as when a person holds his or her breath or increases air pressure within the lungs prior to coughing or sneezing.

The **trachea** or wind pipe, is a membranous tube attached to the larynx. The trachea has an inside diameter of 12 mm and a length of 10–12 cm, descending from the larynx to the level of the fifth thoracic vertebra. It consists of dense regular connective tissue and smooth muscle reinforced with 15–20 C-shaped pieces of hyaline cartilage. The cartilages support the anterior and lateral sides of the trachea. They protect the trachea and maintain an open passageway for air. The posterior wall of the trachea is devoid of cartilage; it contains an elastic ligamentous membrane and bundles of smooth muscle called the **trachealis muscle**. The esophagus lies immediately posterior to the cartilage-free posterior wall of the trachea.

The **lungs** are the principal organs of respiration. Each lung is cone-shaped, with its base resting on the diaphragm and its apex extending superiorly to a point about 2.5 cm above the clavicle.

The right lung has three **lobes** called the superior, middle, and inferior lobes. The left lung has two lobes called the superior and inferior lobes. The lobes of the lungs are separated by deep, prominent fissures on the surface of the lung. Each lobe is divided into **broncho-pulmonary segments** separated from one another by connective tissue septa, but these separations are not visible as surface fissures. Individual diseased bronchopulmonary segments can be surgically removed, leaving the rest of the lung relatively intact, because major blood vessels and bronchi do not cross the septa. There are 9 broncho-pulmonary segments in the left lung and 10 in the right lung.

The lungs are separated from each other by the mediastinum.

Each lung has:

- An apex, the blunt superior end of the lung ascending above the level of the 1st rib into the root of the neck that is covered by cervical pleura.
- A base, the concave inferior surface of the lung, opposite the apex, resting on and accommodating the ipsilateral dome of the diaphragm.
- Two or three lobes, created by one or two fissures.
- Three surfaces (costal, mediastinal, and diaphragmatic).
- Three borders (anterior, inferior, and posterior).

The right lung features right oblique and horizontal fissures that divide it into three right lobes: superior, middle, and inferior. The right lung is larger and heavier than the left, but it is shorter and wider because the right dome of the diaphragm is higher and the heart and pericardium bulge more to the left. The anterior border of the right lung is relatively straight.

The left lung has a single left oblique fissure dividing it into two left lobes, superior and inferior. The anterior border of the left lung has a deep cardiac notch, an indentation consequent to the deviation of the apex of the heart to the left side. This notch primarily indents the anteroinferior aspect of the superior lobe. This indentation often shapes the most inferior and anterior part of the superior lobe into a thin, tongue-like process, the lingula (L. dim. of lingua, tongue), which extends below the cardiac notch and slides in and out of the costomediastinal recess during inspiration and expiration.

### **Relations to the lungs**

The lungs of an embalmed cadaver, usually firm to the touch, demonstrate impressions formed by structures adjacent to them, such as the ribs, heart, and great vessels. These markings provide clues to the relationships of the lungs; however, only the cardiac impressions are evident during surgery or in fresh cadaveric or postmortem specimens.

The costal surface of the lung is large, smooth, and convex. It is related to the costal pleura, which separates it from the ribs, costal cartilages, and innermost intercostal muscles. The posterior part of the costal surface is related to the bodies of the thoracic vertebrae and is sometimes referred to as the vertebral part of the costal surface.

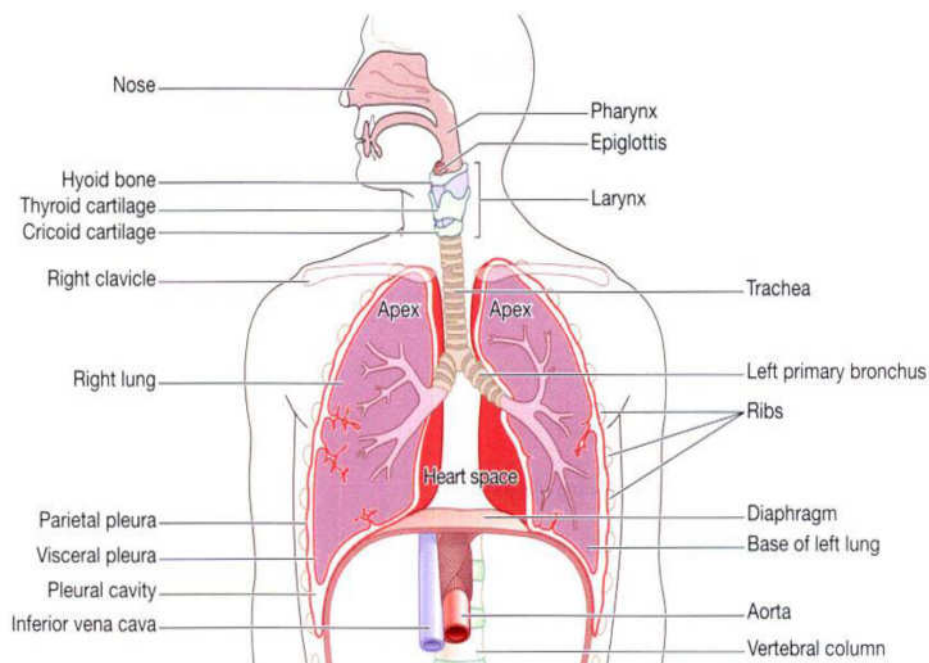
The mediastinal surface of the lung is concave because it is related to the middle mediastinum, which contains the pericardium and heart. The mediastinal surface includes the hilum, which receives the root of the lung. If embalmed, there is a groove for the esophagus and a cardiac impression for the heart on the mediastinal surface of the right lung. Because two thirds of the heart lies to the left of the midline, the cardiac impression on the mediastinal surface of the left lung is much larger. This surface of the left lung also features a prominent, continuous groove for the arch of the aorta and the descending aorta as well as a smaller groove for the esophagus.

The diaphragmatic surface of the lung, which is also concave, forms the base of the lung, which rests on the dome of the diaphragm. The concavity is deeper in the right lung because of the higher position of the



right dome, which overlies the liver. Laterally and posteriorly, the diaphragmatic surface is bounded by a thin, sharp margin (inferior border) that projects into the costodiaphragmatic recess of the pleura.

The anterior border of the lung is where the costal and mediastinal surfaces meet anteriorly and overlap the heart. The cardiac notch indents this border of the left lung. The inferior border of the lung circumscribes the diaphragmatic surface of the lung and separates this surface from the costal and mediastinal surfaces. The posterior border of the lung is where the costal and mediastinal surfaces meet posteriorly; it is broad and rounded and lies in the cavity at the side of the thoracic region of the vertebral column.



**Fig. 1.2:**

### Lung roots

The lungs are attached to the mediastinum by the roots of the lungs—that is, the bronchi (and associated bronchial vessels), pulmonary arteries, superior and inferior pulmonary veins, the pulmonary plexuses of nerves (sympathetic, parasympathetic, and visceral afferent fibers), and lymphatic vessels. If the lung root is sectioned before the (medial to) branching of the main (primary) bronchus and pulmonary artery, its general arrangement is

- Pulmonary artery: most superior on the left (the superior lobar or —eparteriall bronchus may be the most superior on the right).
- Superior and inferior pulmonary veins: most anterior and most inferior, respectively.

- Main bronchus: against and approximately in the middle of the posterior boundary, with the bronchial vessels coursing on its outer surface (usually on posterior aspect at this point).

The hilum of the lung is a wedge-shaped area on the mediastinal surface of each lung through which the structures forming the root of the lung pass to enter or exit the lung. The hilum (“doorway”) can be likened to the area of earth where a plant's roots enter the ground. Medial to the hilum, the lung root is enclosed within the area of continuity between the parietal and the visceral layers of pleura—the pleural sleeve (mesopneumonium).

Inferior to the root of the lung, this continuity between parietal and visceral pleura forms the pulmonary ligament, extending between the lung and the mediastinum, immediately anterior to the esophagus. The pulmonary ligament consists of a double layer of pleura separated by a small amount of connective tissue. When the root of the lung is severed and the lung is removed, the pulmonary ligament appears to hang from the root. To visualize the root of the lung, the pleural sleeve surrounding it, and the pulmonary ligament hanging from it, put on an extra-large lab coat and abduct your upper limb. Your forearm is comparable to the root of the lung, and the coat sleeve represents the pleural sleeve surrounding it. The pulmonary ligament is comparable to the slack of the sleeve as it hangs from your forearm; and your wrist, hand, and abducted fingers represent the branching structures of the root—the bronchi and pulmonary vessels.

### **3.2 Tracheobronchial tree**

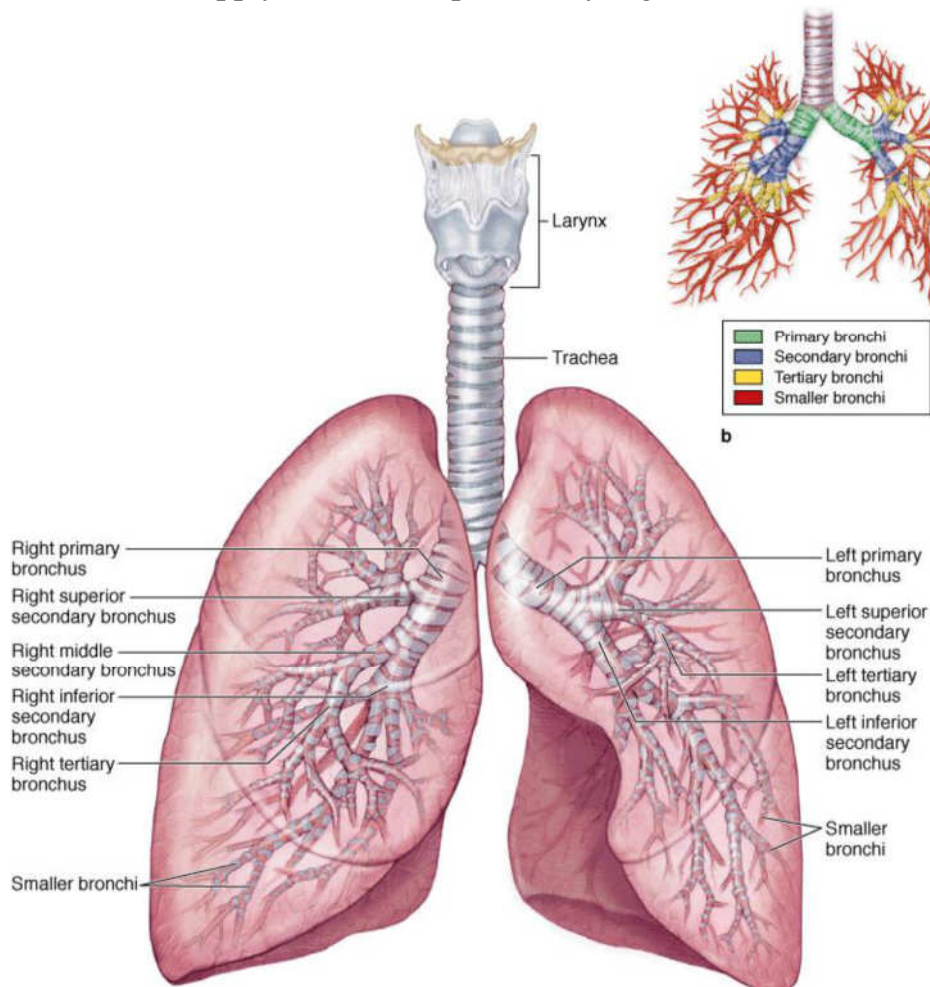
Beginning at the larynx, the walls of the airway are supported by horseshoe- or C-shaped rings of hyaline cartilage. The sublaryngeal airway constitutes the tracheobronchial tree.

The trachea (described with the superior mediastinum, described in the previous subunit), located within the superior mediastinum, constitutes the trunk of the tree. It bifurcates at the level of the transverse thoracic plane (or sternal angle) into main bronchi, one to each lung, passing inferolaterally to enter the lungs at the hila (singular = hilum)

- The right main bronchus is wider, shorter, and runs more vertically than the left main bronchus as it passes directly to the hilum of the lung.
- The left main bronchus passes inferolaterally, inferior to the arch of the aorta and anterior to the esophagus and thoracic aorta, to reach the hilum of the lung.

Within the lungs, the bronchi branch in a constant fashion to form the branches of the tracheobronchial tree. Note that the branches of the tracheobronchial tree are components of the root of each lung (consisting of branches of the pulmonary artery and veins as well as the bronchi).

Each main (primary) bronchus divides into secondary lobar bronchi, two on the left and three on the right, each of which supplies a lobe of the lung. Each lobar bronchus divides into several tertiary segmental bronchi that supply the bronchopulmonary segments.



**Fig. 1.3:**

### **The bronchopulmonary segments are:**

- The largest subdivisions of a lobe.
- Pyramidal-shaped segments of the lung, with their apices facing the lung root and their bases at the pleural surface.
- Separated from adjacent segments by connective tissue septa.
- Supplied independently by a segmental bronchus and a tertiary branch of the pulmonary artery.
- Named according to the segmental bronchi supplying them.
- Drained by intersegmental parts of the pulmonary veins that lie in the connective tissue between and drain adjacent segments.
- Usually 18-20 in number (10 in the right lung; 8-10 in the left lung, depending on the combining of segments).
- Surgically resectable.
- Conducting bronchioles. Bronchioles lack cartilage in their walls.

Conducting bronchioles transport air but lack glands or alveoli. Each terminal bronchiole gives rise to several generations of respiratory bronchioles, characterized by scattered, thin-walled outpocketings (alveoli) that extend from their lumens. The pulmonary alveolus is the basic structural unit of gas exchange in the lung. Due to the presence of the alveoli, the respiratory bronchioles are involved both in air transportation and gas exchange. Each respiratory bronchiole gives rise to 2-11 alveolar ducts, each of which gives rise to 5-6 alveolar sacs. Alveolar ducts are elongated airways densely lined with alveoli, leading to common spaces, the alveolar sacs, into which clusters of alveoli open. New alveoli continue to develop until about age 8 years, by which time there are approximately 300 million alveoli.

### **3.3 Vasculature of lungs and pleurae**

Each lung has a pulmonary artery supplying blood to it and two pulmonary veins draining blood from it. The right and left pulmonary arteries arise from the pulmonary trunk at the level of the sternal angle and carry low-oxygen (—venous!) blood to the lungs for oxygenation. (They are usually colored blue, like veins, in anatomical illustrations.) Each pulmonary artery becomes part of the root of the corresponding lung and divides secondary lobar arteries. The right and left superior lobar arteries to the superior lobes arise first, before entering the hilum. Continuing into the lung, the artery descends posterolateral to the main bronchus as the inferior lobar artery of the left lung and as an intermediate artery that will divide into middle and inferior lobar arteries of the right lung. Lobar arteries divide into tertiary segmental arteries. The arteries and bronchi are paired in the lung, branching simultaneously and running parallel courses. Consequently, a paired

secondary lobar artery and bronchus serves each lobe and a paired tertiary segmental artery and bronchus supply each bronchopulmonary segment of the lung, with the arteries usually located on the anterior aspect of the corresponding bronchus.

- Two pulmonary veins, a superior and an inferior pulmonary vein on each side, carry oxygen-rich (—arteriall) blood from corresponding lobes of each lung to the left atrium of the heart. The middle lobe vein is a tributary of the right superior pulmonary vein. (Pulmonary veins are commonly colored red, like arteries, or purple in anatomical illustrations.) The pulmonary veins run independently of the arteries and bronchi in the lung, coursing between and receiving blood from adjacent bronchopulmonary segments as they run toward the hilum. Except in the central, perihilar region of the lung, the veins from the visceral pleura and the bronchial venous circulation drain into the pulmonary veins, the relatively small volume of low-oxygen blood entering the large volume of oxygen-rich blood returning to the heart. Veins from the parietal pleura join systemic veins in adjacent parts of the thoracic wall.
- Bronchial arteries supply blood for nutrition of the structures making up the root of the lungs, the supporting tissues of the lungs, and the visceral pleura. The two left bronchial arteries usually arise directly from the thoracic aorta. The single right bronchial artery may also arise directly from the aorta. Most commonly it arises indirectly, either by way of the proximal part of one of the upper posterior intercostal arteries (usually the right 3rd posterior intercostal artery), or from a common trunk with the left superior bronchial artery.
- The small bronchial arteries provide branches to the upper esophagus and then typically pass along the posterior aspects of the main bronchi, supplying them and their branches as far distally as the respiratory bronchioles. The most distal branches of the bronchial arteries anastomose with branches of the pulmonary arteries in the walls of the bronchioles and in the visceral pleura. The parietal pleura is supplied by the arteries that supply the thoracic wall.
- The bronchial veins drain only part of the blood supplied to the lungs by the bronchial arteries primarily that distributed to or near the more proximal part of the roots of the lungs. The remainder of the blood is drained by the pulmonary veins, specifically that returning from the visceral pleura, the more peripheral regions of the lung, and the distal components of the root of the lung. The right bronchial vein drains into the azygos vein, and the left bronchial vein drains into the accessory

hemiazygos vein or the left superior intercostal vein. Bronchial veins also receive some blood from esophageal veins.

- The pulmonary lymphatic plexuses communicate freely. The superficial (subpleural) lymphatic plexus lies deep to the visceral pleura and drains the lung parenchyma (tissue) and visceral pleura. Lymphatic vessels from this superficial plexus drain into the bronchopulmonary lymph nodes (hilar lymph nodes) in the region of the lung hilum.
- The deep lymphatic plexus is located in the submucosa of the bronchi and in the peribronchial connective tissue. It is largely concerned with draining the structures that form the root of the lung. Lymphatic vessels from this deep plexus drain initially into the intrinsic pulmonary lymph nodes, located along the lobar bronchi. Lymphatic vessels from these nodes continue to follow the bronchi and pulmonary vessels to the hilum of the lung, where they also drain into the bronchopulmonary lymph nodes. From them, lymph from both the superficial and deep lymphatic plexuses drains to the superior and inferior tracheobronchial lymph nodes, superior and inferior to the bifurcation of the trachea and main bronchi, respectively. The right lung drains primarily through the consecutive sets of nodes on the right side, and the superior lobe of the left lung drains primarily through corresponding nodes of the left side. Many, but not all, of the lymphatics from the lower lobe of the left lung, however, drain to the right superior tracheobronchial nodes; the lymph then continues to follow the right-side pathway.
- Lymph from the tracheobronchial lymph nodes passes to the right and left bronchomediastinal lymph trunks, the major lymph conduits draining the thoracic viscera. These trunks usually terminate on each side at the venous angles (junctions of the subclavian and internal jugular veins); however, the right bronchomediastinal trunk may first merge with other lymphatic trunks, converging here to form the short right lymphatic duct. The left bronchomediastinal trunk may terminate in the thoracic duct. Lymph from the parietal pleura drains into the lymph nodes of the thoracic wall (intercostal, parasternal, mediastinal, and phrenic). A few lymphatic vessels from the cervical parietal pleura drain into the axillary lymph nodes.

### **3.4 Nerves of lungs and pleurae**

The nerves of the lungs and visceral pleura are derived from the pulmonary plexuses anterior and (mainly) posterior to the roots of the lungs. These nerve networks contain parasympathetic, sympathetic, and visceral afferent fibers.

The parasympathetic fibers conveyed to the pulmonary plexus are presynaptic fibers from the vagus nerve (CN X). They synapse with parasympathetic ganglion cells (cell bodies of postsynaptic neurons) in the pulmonary plexuses and along the branches of the bronchial tree. The parasympathetic fibers are motor to the smooth muscle of the bronchial tree (bronchoconstrictor), inhibitory to the pulmonary vessels (vasodilator), and secretory to the glands of the bronchial tree (secretomotor). The sympathetic fibers of the pulmonary plexuses are postsynaptic fibers. Their cell bodies (sympathetic ganglion cells) are in the paravertebral sympathetic ganglia of the sympathetic trunks. The sympathetic fibers are inhibitory to the bronchial muscle (bronchodilator), motor to the pulmonary vessels (vasoconstrictor), and inhibitory to the alveolar glands of the bronchial tree—type II secretory epithelial cells of the alveoli.

## 5.0 SUMMARY

In this unit, you have learnt about the following:

- i. Functions of the respiratory system
- ii. Anatomical position and relations of the lungs
- iii. Lung roots and traheobronchial tree
- iv. Vasculature and nerve supply of the lungs and pleura
- v. Seven clinical oriented anatomy.

### Clinical correlates

#### Sinusitis

a. Sinusitis is an inflammation of the mucous membrane of any sinus, especially of one or more paranasal sinuses. Viral infections, such as the common cold, can cause mucous membranes to become inflamed, to swell, and to produce excess mucus. As a result, the sinus opening into the nasal cavity can be partially or completely blocked. Mucus accumulates within the sinus, which can promote the development of a bacterial infection. Treatments consist of taking antibiotics and promoting sinus drainage with decongestants, hydration, and steam inhalation. Sinusitis can also result from swelling caused by allergies or by polyps that obstruct a sinus-opening into the nasal cavity.

#### The Sneeze Reflex

a. The **sneeze reflex** dislodges foreign substances from the nasal cavity. Sensory receptors detect the foreign substances, and action potentials are conducted along the trigeminal nerves to the medulla oblongata in which the reflex is triggered. During the sneeze reflex, the uvula and the soft

palate are depressed so that rapidly flowing air from the lungs is directed primarily through the nasal passages, although a considerable amount passes through the oral cavity. Some people have a photic sneeze reflex, in which exposure to bright light, such as the sun, can stimulate a sneeze reflex. The pupillary reflex causes the pupils to constrict in response to bright light. It is speculated that the complicated —wiring of the pupillary and sneeze reflexes is intermixed in some people so that, when bright light activates a pupillary reflex, it also activates a sneeze reflex.

### **The Cough Reflex**

a. The function of the **cough reflex** is to dislodge foreign substances from the trachea. Sensory receptors detect the foreign substances, and action potentials are conducted along the vagus nerves to the medulla oblongata in which the cough reflex is triggered. During coughing, contraction of trachealis muscle decreases the diameter of the trachea. As a result, air moves rapidly through the trachea, which helps expel mucus and foreign substances. Also, the uvula and soft palate are elevated so that air passes primarily through the oral cavity.

### **Establishing Air flow**

- a. In cases of extreme emergency when the upper air passageway is blocked by a foreign object to the extent that the victim cannot breathe, quick reaction is required to save the person's life. An **abdominal thrust**, or the **Heimlich maneuver**, is designed to force objects out of the air passage by the sudden application of pressure
- b.
- c. to the abdomen. The person who performs the maneuver stands behind the victim, with his or her arms under the victim's arms and hands over the victim's abdomen between the navel and the rib cage. With one hand formed into a fist and the other hand over it, both hands are suddenly pulled toward the abdomen with an accompanying upward motion. This maneuver, if done properly, forces air up the trachea and dislodges most foreign objects.

### **Asthma**

a. This is a disease characterized by abnormally increased constriction of the bronchi and bronchioles in response to various stimuli, resulting in a narrowing of the air passageways and decreased ventilation efficiency. Symptoms include rapid, shallow breathing; wheezing; coughing; and shortness of breath. In contrast to many other respiratory disorders,



however, the symptoms of asthma typically reverse either spontaneously or with therapy.

**Cystic fibrosis (CF)** is a disease characterized by frequent, serious respiratory

- a. infections and thick, sticky mucus in the lungs and digestive tract. It is the most
- b. common lethal genetic disorder in Caucasians. Cystic fibrosis is inherited as an
- c. autosomal-recessive gene on chromosome 7.

A **pneumothorax** is the introduction of air into the pleural cavity. Air can enter by an external route when a sharp object, such as a bullet or broken rib, penetrates the thoracic wall, or air can enter the pleural cavity by an internal route if alveoli at the lung surface rupture, such as can occur in a patient with emphysema. When the pleural cavity is connected to the outside by such openings, air moves into the pleural cavity because air moves from the higher atmospheric pressure to the lower sub-atmospheric pressure in the pleural cavity. When air moves into the pleural cavity, the pressure in the pleural cavity increases and becomes equal to the atmospheric pressure outside the body.

## 6.0 TUTOR MARKED ASSIGNMENTS

### 6.1 Activity

- i. Smoking destroys cilia in the respiratory tract. Search the Internet and download pictures and illustrations of how cigarette affects and damage the lungs and other parts of the body.
- ii. Draw well labelled diagrams of different organs that make up the reproductive system. Include the drawings in your portfolio for submission at the conclusion of this module.
- iii. Compile different diseases that can affect the different organs in the respiratory system

### 6.2 Please answer the following questions:

1. Describe the locations and structures of the following structures:
  - a. pharynx
  - b. larynx
  - c. primary bronchi
  - d. alveoli
  - e. epiglottis

2. Compare and contrast the right and left lungs
3. In a table list out the arteries and veins that supply the various organs that makes up the respiratory system
4. Explain the cough reflex.

## **7.0 REFERENCES AND OTHER RESOURCES**

Hutchinson, M., Mallat, J., Marieb, E.N., Wilhelm P.B. (2007). A Brief Atlas of the Human Body. Sna Franscisco: Pearson Education Inc.

Katherine M. A. Rogers and William N. Scott (2011) Nurses! Test Yourself in Anatomy and Physiology

Kathryn A. Booth, Terri. D. Wyman (2008) Anatomy, Physiology, and Pathophysiology for Allied Health

Keith L Moore, Persuade T.V.N (2018), The Developing Human Clinically Oriented Embryology 11th Edition Lippincott Williams & Wilkins

Kent M. Van De Graff, R.Ward Rhees, Sidney Palmer (2010) Schaum's Outline of human Anatomy and Physiology 3rd edition.

Philip Tate (2012) Seeley's Principles of Anatomy & Physiology 2nd ed.

Sadler T.W (2012), Langman's Medical Embryology 12th edition.

Seeley's Principles of Anatomy & Physiology, Second edition Published by McGraw-Hill, a business unit of The McGraw-Hill Companies, Inc., 1221 Avenue of the Americas, New York, NY 10020. Copyright c 2012- Chapter 17&18

## **UNIT 2 DEVELOPMENTAL AND MICROANATOMY OF THE RESPIRATORY SYSTEM.**

### **CONTENT**

- 1.0 Introduction
- 2.0 Objectives
- 3.0 Main Content
  - 3.1 Developmental anatomy of respiratory system
  - 3.2 Histology/Microanatomy of the respiratory system
- 4.0 Conclusion
- 5.0 Summary
- 6.0 Tutor Marked Assignments
- 7.0 References and other resources

### **1.0 INTRODUCTION**

Early spontaneous breathing is normally quiet and accomplished without effort. The amount of energy expended on breathing depends on the rate and depth of each breath, airway resistance and compliance (stretch) of the lungs. The ribs, intercostal muscles and diaphragm allow ventilation (the moving of air in and out of the lungs) under the control of the respiratory centre in the brain and the lung sacs (the alveoli) allow oxygen and carbon dioxide gases to exchange with the blood. The respiratory system develops after the fourth week of gestation

### **2.0 OBJECTIVES**

At the end of this unit, you should be able to:

- Describe the embryology of the respiratory system
- Describe the micro- anatomy of the respiratory system

### **3.0 MAIN CONTENT**

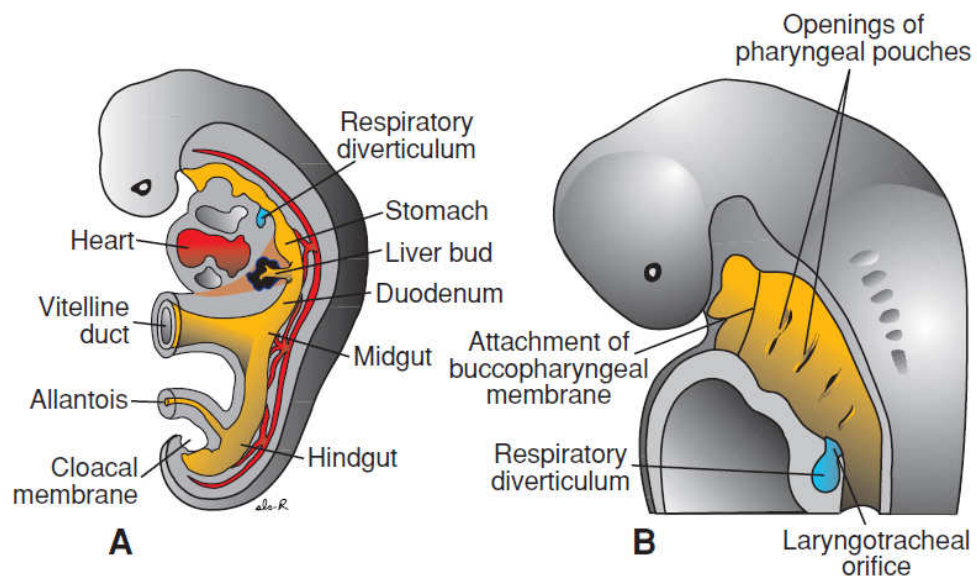
#### **3.1 Developmental anatomy of the respiratory system**

In considering the development of this system it is important to review the development of the foregut, in specific and the development of the endoderm overall. It is also important to consider the development of the respiratory system in terms of its many constituent components.

The respiratory system begins at the nasal cavity and consists of a conducting portion and a respiratory portion. The conducting portion

includes nasal cavity, pharynx, larynx, trachea, bronchi, and bronchioles. The respiratory portion consists of the respiratory bronchioles, alveolar ducts, alveolar sacs and the alveoli. Gaseous exchange occurs in the alveoli. The development of the respiratory system involves the endoderm and the mesoderm that surrounds it. As discussed previously, the embryo undergoes lateral body folding and during this process the endoderm forms into a gut tube. This G.I. tube begins cephalically at the oral plate and continues until it reaches the cloacal or anal plate. If we look at the gut tube at the time the body folding is completed, it can be subdivided into three divisions: a foregut, a midgut and a hindgut.

The early development of the lungs lags behind the development of the heart and great vessels. However, as development proceeds the lungs will eventually occupy more of the thoracic cavity than the heart. This will be discussed further in the section on the partitioning of the body cavities. The structures that are located cephalic to the larynx include the pharynx and the nasal and oral cavities. The development of these structures will be discussed later in the course. We will begin with the development of the larynx and continue caudally.



**Fig 2.1:** 5 weeks old embryo showing respiratory diverticulum

### Larynx

The larynx is first seen as an outgrowth from the foregut. The outgrowth of tissue is called the **respiratory diverticulum** or the **lung bud**. The formation of the lung bud occurs when two lateral folds of splanchnic mesoderm and endoderm meet in the midline and separate the larynx and trachea from the esophagus. The lung bud is a ventral diverticulum of endoderm that arises from the floor of the foregut caudal to the

pharynx. The diverticulum forms a groove in the floor of the pharynx called the **laryngotracheal groove**. Cephalic to the laryngotracheal groove is the **epiglottal swelling**. On either side of this groove are the developing **arytenoid swellings**.

The epithelium of the larynx develops from the endoderm of the foregut. However, the muscles and cartilage arise from the 4th and the 6th arches. The development of these structures will be discussed in a later lecture.

## **Trachea**

The trachea develops caudal to the larynx. The epithelium develops from the endoderm and the tracheal cartilage and muscles develop from splanchnic mesoderm. Early in development the **trachea bifurcates** into the left and right bronchi.

## **Bronchi and bronchioles**

As the bronchi develop they continue to branch. The right bronchus gives off three diverticula and the left bronchus gives off two diverticula. These diverticula become the **lobar bronchi** and indicate that the right lung will have three lobes and the left lung will have two lobes. Each of the bronchi at this stage will divide into smaller bronchi. The branching of the bronchi continues until the **bronchioles** begin to form. In all there are 17 divisions of the bronchi until the sixth fetal month is reached. However, by early childhood there will be a total of 24 generations of branching that occurs.

## **Maturation of the lungs**

As the lungs develop and divide into smaller divisions there are changes in the vascular supply of the lungs as well. The lungs can be described as undergoing 4 phases of development. During the first phase of development, the **pseudoglandular period**, the bronchi are dividing into smaller and smaller units, the bronchioles. This period occurs from the 2nd month through the end of the 4th month. During the next 2 and 1/2 months the respiratory bronchioles are formed. They will give rise to alveolar ducts. This is called the **canalicular period (microscope slide image)**. During this time period the epithelium remains as a cuboidal epithelium and the capillaries while proliferating do not approach the respiratory epithelium.

The next phase of development occurs from the 7th month until birth. During this period, the **terminal sac phase (microscope slide image)**, the number of capillaries increases and the capillaries approach the

respiratory epithelium. At the same time the terminal sacs form. This results in the formation of a squamous epithelium, made up of **type I alveolar epithelial cells**, which will permit gaseous exchange. Hence, from the 7th month on the fetus is capable of survival. It is also starting with the 7th month that **type II alveolar epithelial cells** develop. These type II cells produce **surfactant**, the fluid that reduces the surface tension at the alveolar cell surface.

Finally, from the 8th month on, the mature alveoli continue to be formed with an increase in the amount of surface area where capillaries and alveolar cells are in contact. This period of lung development is the **alveolar period** and actually can last through age ten. The growth of the lungs after birth is mainly the result of increases in the number of alveoli during this time.

### **Partitioning of the embryonic body cavity**

Early during development the embryonic coelom was a single cavity and, in the most cephalic region, was identified as the horse-shoe shaped **prospective pericardial cavity**. The intraembryonic body cavity is located between the splanchnic and somatic mesoderm. During the cephalic head folding, the perspective pericardial cavities moved caudally and remain continuous with the peritoneal cavity.

### **Septum transversum**

Caudal to the developing heart in the region where the veins enter the sinus venosus a septum develops from the body wall after lateral body folding is completed. This septum is called **septum transversum** and separates the thoracic cavity from the abdominal cavity. The communication between the two cavities that remains is located dorsally and is called the **pericardioperitoneal canals**.

The fibrous pericardium forms from the **pleuropericardial folds**. Mesoderm develops from the dorsolateral body wall in the region of the common cardinal veins. As they extend caudally these folds intersect the septum transversum, the folds grow toward the midline and attach to the **primitive mediastinum** and end up separating the heart from the lungs with the thoracic cavity now divided into a pericardial cavity and two pleural cavities. The other structure that lies within the pleuropericardial fold is the phrenic nerve as it descends to innervate the diaphragm.

## Diaphragm

The diaphragm develops from four structures:

- lateral body wall mesoderm,
- septum transversum,
- dorsal mesentery of the esophagus, and
- pleuroperitoneal folds. **Pleuroperitoneal folds** arise from the posterior body wall and lie in a plane that is parallel to the septum transversum and perpendicular to the pleuropericardial folds.

It is the pleuroperitoneal membranes that **close off the pericardioperitoneal canal**.

The diaphragm is innervated from the 3rd - 5th cervical spinal cord segments via the phrenic nerve. The diaphragm develops initially in a more cephalic region and during development descends into a more caudal thoracic position. The phrenic nerves travel with the diaphragm and come to lie within the fibrous pericardium.

### 3.2 Histology of the respiratory system

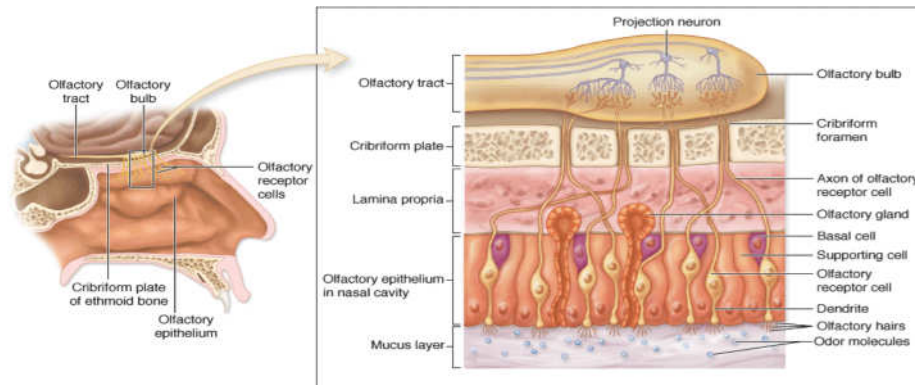
The complex of organs and tissue which are necessary to exchange blood carbon dioxide (CO<sub>2</sub>) with air oxygen (O<sub>2</sub>) is called the respiratory system. It consists of

- structures, which function as ducts, and which together are called the conductive portion of the respiratory system
- structures which form the respiratory portion of the respiratory system, in which the exchange of CO<sub>2</sub> and O<sub>2</sub> is occurring
- The parts of the thoracic musculo-skeletal apparatus and specialisations of the lung which allow the movement of air through the respiratory system - the ventilating mechanism.

#### Nasal Cavity

The Nasal cavity is divided into three structurally and functionally different parts.

- The vestibules (the first ~1.5 cm of the conductive portion following the nostrils) are lined with a keratinised stratified squamous epithelium. Hairs, which filter large particulate matter out of the airstream, and sebaceous glands are also present.



**Fig. 2.1:**

- At the transition from the vestibule to the respiratory region of the nasal cavity the epithelium becomes first stratified squamous and then pseudostratified columnar and ciliated. This type of epithelium is characteristic for all conductive passages dedicated to the respiratory system and therefore also called respiratory epithelium. Mucus producing goblet cells are present in the epithelium. The surface of the lateral parts of the nasal cavity is thrown into folds by bony projections called conchae. These folds increase the surface area of the nasal cavity and create turbulence in the stream of passing air, both of which facilitate the conditioning (warming, cooling and filtration) of the air. Mucous and serous glands in the connective tissue underlying the epithelium, the lamina propria, supplement the secretion of the goblet cells. Veins in the lamina propria form thin-walled, cavernous sinusoids, also called cavernous bodies.
- Tissues on the superior concha and the nasal septum form the olfactory region of the nasal cavity. Cilia in the epithelium of the olfactory region arise from olfactory cells. Although their internal structure resembles largely that of normal cilia they do not move, because they lack dynein arms which are necessary for ciliary motility. The cell membrane covering the surface of the cilia contains olfactory receptors which respond to odour-producing substances, odorants, dissolved in the serous covering the epithelium. The axons of the olfactory cells collect into bundles in the lamina propria. The olfactory cells and their processes receive mechanical and metabolic support from supporting cells (or sustentacular cells). Basal cells can divide and differentiate into either olfactory or supporting cells. The supporting cells and



the secretion of the serous glands contain lipofuscin granules, which give a yellow-brown colour to the surface of the olfactory region.

## **Pharynx**

The pharynx connects the nasal cavity with the larynx. Depending on the extent of abrasive forces on the epithelium, the pharynx is either lined with respiratory epithelium (nasopharynx or epipharynx) or with a stratified squamous epithelium (oropharynx or meso- and hypopharynx), which also covers the surfaces of the oral cavity and the oesophagus. Lymphocytes frequently accumulate beneath the epithelium of the pharynx.

## **Larynx**

The larynx connects the pharynx and trachea. The vocal folds of the larynx control airflow and allow the production of sound. The vocal folds are lined by stratified squamous epithelium and contain the muscle (striated, skeletal) and ligaments needed to control the tension of the vocal folds. The larynx is supported by a set of complexly shaped cartilages.

## **Trachea**

The trachea is a fairly short tube (10-12 cm) with a diameter of ~2 cm consisting of Epithelium, Mucosa and Submucosa. The trachea is lined by respiratory epithelium. The number of goblet cells is variable and depends on physical or chemical irritation of the epithelium which increase goblet cell number. Prolonged intense irritation of the epithelium may lead to its transformation to a stratified squamous epithelium (squamous metaplasia). In addition to the staple of basal cells, ciliated cells and goblet cells, the respiratory epithelium also contains brush cells, endocrine cells (or small granule cells, function not clear), surfactant-producing cells (or Clara cells), and serous cells.

Epithelium and underlying lamina propria are called the mucosa. The lamina propria consists of loose connective tissue with many elastic fibres, which condense at the deep border of the lamina propria to form an elastic membrane. This elastic membrane forms the border between the mucosa and the connective tissue below it, which is called the submucosa. Muco-serous glands in the submucosa (submucosal glands) supplement the secretions of cells in the epithelium. The submucosa ends with the perichondrium of the tracheal cartilages.

The trachea is stabilised by 16-20 C-shaped cartilages (hyaline cartilage). The free dorsal ends of the cartilages are connected by bands of smooth muscle (trachealis muscle) and connective tissue fibres. Longitudinal collagenous and elastic connective tissue fibres (annular ligaments) link the individual cartilages and allow both the lengthening and shortening of the trachea for example during swallowing or movements of the neck. They are inseparable from the fibres of the perichondrium. The tracheal cartilages may ossify with age. The trachea bifurcates to give rise to the main bronchi. Their histological structure corresponds largely to that of the trachea.

## **Conductive Structures in the Lung**

### **Bronchi**

In the lungs we find the last segments of the conductive portion of the respiratory system. The main bronchi divide into lobar bronchi which in turn give rise to segmental bronchi. The latter supply the bronchopulmonary segments of the lungs. Bronchial branches are accompanied by branches of the pulmonary artery, nerves and lymph vessels. These structures usually travel in intersegmental and interlobar sheets of connective tissue. Conductive structures of a size down to ~1 mm are termed bronchi. Smaller ones are called bronchioles. Aside from their different sizes, bronchi are characterized by the presence of glands and supporting cartilage. The cartilage supporting the bronchi is typically found in several small pieces.

The histological structure of the epithelium and the underlying connective tissue of the bronchi corresponds largely to that of the trachea and the main bronchi. In addition, bronchi are surrounded by a layer of smooth muscle, which is located between the cartilage and epithelium.

### **Bronchioles**

Bronchioles are the terminal segments of the conductive portion. At the transition from bronchi to bronchioles the epithelium changes to a ciliated columnar epithelium, but most of the cell types found in the epithelium of other parts of the conductive portion are still present. Glands and cartilage are absent. The layer of smooth muscle is relatively thicker than in the bronchi.

## **Respiratory Structures in the Lung**

Bronchioles divide into respiratory bronchioles, which are the first structures that belong to the respiratory portion of the respiratory

system. Small outpouchings of the walls of the respiratory bronchioles form alveoli, the site of gas exchange. The number of alveoli increases as the respiratory bronchioles continue to divide. They terminate in alveolar ducts. The "walls" of alveolar ducts consists of entirely of alveoli.

### **Histological Structure of Alveoli**

The wall of the alveoli is formed by a thin sheet ( $\sim 2\mu\text{m}$ ) of tissue separating two neighbouring alveoli. This sheet is formed by epithelial cells and intervening connective tissue. Collagenous (few and fine), reticular and elastic fibres are present. Between the connective tissue fibres we find a dense, anastomosing network of pulmonary capillaries. The wall of the capillaries are in direct contact with the epithelial lining of the alveoli. The basal laminae of the epi- and endothelium may actually fuse. Neighbouring alveoli may be connected to each other by small alveolar pores.

The epithelium of the alveoli is formed by two cell types:

- Alveolar type I cells (small alveolar cells or type I pneumocytes) are extremely flattened (the cell may be as thin as  $0.05\ \mu\text{m}$ ) and form the bulk (95%) of the surface of the alveolar walls. The shape of the cells is very complex, and they may actually form part of the epithelium on both faces of the alveolar wall.
- Alveolar type II cells (large alveolar cells or type II pneumocytes) are irregularly (sometimes cuboidal) shaped. They form small bulges on the alveolar walls. Type II alveolar cells contain a large number of granules called cytosomes (or multilamellar bodies), which consist of precursors to pulmonary surfactant (the mixture of phospholipids which keep surface tension in the alveoli low). There are just about as many type II cells as type I cells. Their small contribution to alveolar area is explained by their shape.

Cilia are absent from the alveolar epithelium and cannot help to remove particulate matter which continuously enters the alveoli with the inspired air. Alveolar macrophages take care of this job. They migrate freely over the alveolar epithelium and ingest particulate matter. Towards the end of their life span, they migrate either towards the bronchioles, where they enter the mucus lining the epithelium to be finally discharged into the pharynx, or they enter the connective tissue septa of the lung.

## 5.0 SUMMARY

In this unit, you have just learnt the following:

1. The development of the respiratory system involves the endoderm and the mesoderm that surrounds it.
2. The epithelium of the larynx develops from the endoderm of the foregut. However, the muscles and cartilage arise from the 4th and the 6th arches.
3. The lungs can be described as undergoing 4 phases of development – pseudoglandular phase, canalicular phase, terminal sac phase and the alveolar phase.
4. The histology of the various components of the respiratory system.

## 6.0 TUTOR MARKED ASSIGNMENTS

**6.1 Activity** – See Laboratory manual

**6.2 Please answer the following questions:**

1. The nasopharynx
  - a. is lined with nonkeratinized stratified squamous epithelium.
  - b. contains the pharyngeal tonsil.
  - c. opens into the oral cavity.
  - d. extends to the tip of the epiglottis.
  - e. is an area through which food, drink, and air normally pass.
2. The larynx
  - a. connects the oropharynx to the trachea.
  - b. has three unpaired and six paired cartilages.
  - c. contains the vocal folds.
  - d. contains the vestibular folds.
  - e. all of the above.
3. Terminal bronchioles branch to form
  - a. the alveolar duct.
  - b. alveoli.
  - c. bronchioles.
  - d. respiratory bronchioles.
4. The parietal pleura
  - a. covers the surface of the lung.
  - b. covers the inner surface of the thoracic cavity.

- c. is the connective tissue partition that divides the thoracic cavity into right and left pleural cavities.
  
- d. covers the inner surface of the alveoli.
  
- e. is the membrane across which gas exchange occurs.

## **UNIT 3 ANATOMY OF THE DIAPHRAGM AND MEDIASTINUM**

### **CONTENT**

- 1.0 Introduction
- 2.0 Objectives
- 3.0 Main Content
  - 3.1 Anatomy of the diaphragm
  - 3.2 Functions of the diaphragm
  - 3.3 Anatomy of the mediastinum
- 4.0 Conclusion
- 5.0 Summary
- 6.0 Tutor Marked Assignments
- 7.0 References and other resources

### **1.0 INTRODUCTION**

The diaphragm is the primary muscle of respiration. It is dome shaped and consists of a peripheral muscular part and central tendinous part. The muscular part arises from the margins of the thoracic opening and gets inserted into the central tendon. It has three openings which shall be discussed extensively in this unit.

### **2.0 OBJECTIVES**

At the end of this unit, you should be able to:

- i. Identify the major structures of the mediasternum.
- ii. Describe the structure, functions and innervations of the diaphragm.

### **3.0 MAIN CONTENT**

#### **3.1 Anatomy of the diaphragm**

Diaphragm is a muscular and tendinous sheath that closes the opening between thorax and abdomen and is pierced by structures that pass between these two regions of the body.

***Origin of diaphragm:***

The origin of the diaphragm can be divided into three parts.

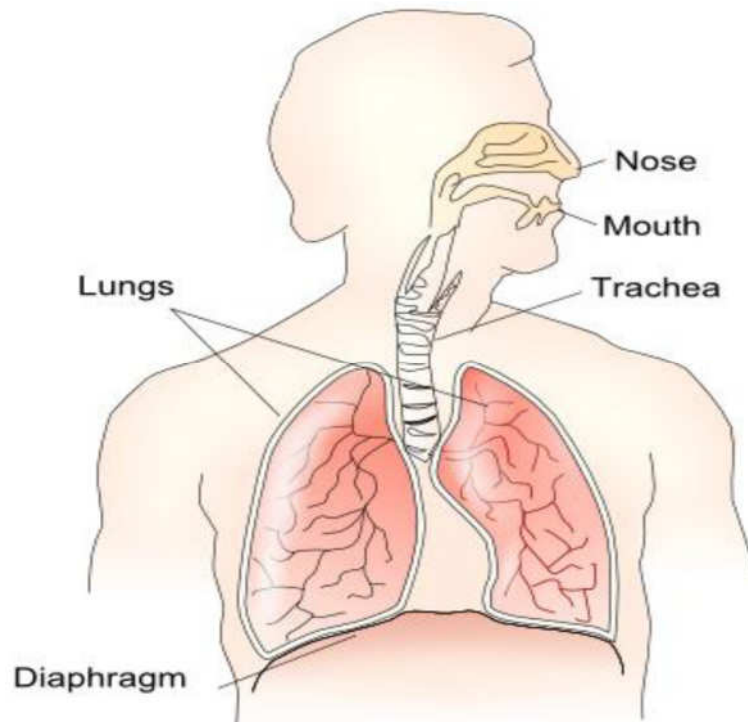
- **Sternal part:** It consists of small left and right strips that arise from the posterior surface of the xiphoid process.
- **Costal part:** It consists of six slips that arise from the lower six ribs (rib 7 to rib 12) and their costal cartilages.
- **Vertebral part:** It arises by means of vertical columns, also known as crura, and from the arcuate ligaments.

**Crura:** The right crus arises from the bodies of first three lumbar vertebrae and their intervertebral discs. The left crus, on the other hand, arises from the bodies of first two lumbar vertebrae.

**From arcuate ligaments:** Lateral to the crura on both sides, the diaphragm arises from the medial and lateral arcuate ligaments. Medial arcuate ligament is thickened upper margin of fascia that covers the psoas muscle on its anterior surface and the lateral arcuate ligament is thickened upper margin of the fascia covering the quadratus lumborum muscle. The medial arcuate ligament is extended from the side of the body of first lumbar vertebra to the tip of the transverse process of second lumbar vertebra. The lateral arcuate ligament, in contrast to the medial, extends from the tip of the transverse process of first lumbar vertebra and is inserted into the lower border of the 12th rib.

***Insertion of diaphragm:***

The diaphragm is inserted into the central tendon that is shaped like three leaves. On the superior side, the surface of the tendon is partially fused with the pericardium



**Fig. 3.1:**

In anatomic position, the diaphragm curves into right and left domes (also known as cupolae). The right dome is slightly higher than the left dome and reaches as high as the upper border of the fifth rib. The left dome may reach up to the lower border of the fifth rib. The reason behind the right dome being higher than the left one is probably the larger size of the right lobe of liver. The central tendon, which lies between the two domes, remains at the level of xiphisternal joint. The domes of diaphragm support the right and left lungs while the central tendon provides support to heart. The position and shape of diaphragm is not absolute but vary with the phase of respiration. During inspiration, the diaphragm lies at a lower level and during expiration, it rises to a higher level. The position also depends upon the posture of body (lower when a person is sitting or standing and higher in supine position) and degree of distention of the abdominal viscera.

### ***Openings in the diaphragm:***

All the structures that pass from the thorax into the abdomen or rise from abdomen into the thorax pass through the diaphragm. For this reason, diaphragm contains numerous openings. Besides many small openings, there are three major ones as described below.

- **Aortic opening:** This opening transmits aorta, thoracic duct and azygous vein and lies anterior to the body of 12th thoracic vertebra between the crura.



- **Esophageal opening:** It transmits esophagus, left and right vagus nerves, esophageal branches of the left gastric vessels and lymphatics from lower third of the esophagus. It lies at the level of 10th thoracic vertebra in a sling of muscle fibers derived from the right crus.
- **Caval opening:** It transmits the inferior vena cava and terminal branches of right phrenic nerve. It lies at the level of 8th thoracic vertebra.

**Other minor openings:** Besides the three major openings, the diaphragm contains numerous small openings for various structures. Some of the structures that have their own small openings in the diaphragm are:

- Sympathetic trunk (pass posterior to the medial arcuate ligament on both sides)
- Superior epigastric vessels (pass between the sterna and costal origins of the diaphragm on each side)
- Left phrenic nerve (pierces the left dome of diaphragm)
- Neurovascular bundles of lower six intercostal spaces (pass between the muscular slips of costal origin of diaphragm)

### **Action of diaphragm:**

Diaphragm is the primary respiratory muscle of the body. It, on contraction, increases the vertical diameter of the chest cavity by pulling its central tendon downwards. In this way, the lungs get extra space to expand and air rushes into them.

### **Nerve supply of diaphragm:**

The motor nerve supply of diaphragm is only from the phrenic nerve. The sensory supply of the central tendon of diaphragm that is covered by parietal and peritoneal pleura is from phrenic nerve. Sensory supply to the periphery of diaphragm is from lower six intercostal nerves.

## **3.2 Functions of diaphragm**

**Muscle of inspiration:** Diaphragm is the primary muscle of inspiration and holds the most important value for the overall process of exchange of gases.

**Muscle of abdominal straining:** With the aid of a contracted diaphragm, muscles of the anterior abdominal wall can raise the intra-abdominal pressure to evacuate pelvic contents, which is important for micturition, defecation and parturition. The role of diaphragm is further

aided when the person takes a deep breath and closes the glottis of the larynx. Consequently, the diaphragm is unable to rise because of the air trapped in the respiratory tract and the abdominal muscles can create increased abdominal pressure. During the process, whenever air escapes, a grunting sound is produced.

**Muscle of weight-lifting:** By fixing the diaphragm in the same way as described above, it is possible to raise the intra-abdominal pressure to such an extent that it helps support the vertebral column and prevent flexion. This greatly assists postvertebral muscles in lifting of heavy weights.

**Thoraco-abdominal pump of blood flow:** The descent of diaphragm into the abdomen decreases the intra-thoracic pressure while increasing the intra-abdominal pressure at the same time. This pressure gradient causes the blood to flow upward into the heart. Lymph within the lymph vessels is also forced to move in a similar way.

### 3.3 Anatomy of the mediastinum

The mediastinum lies between the right and left pleuræ in and near the median sagittal plane of the chest. It extends from the sternum in front to the vertebral column behind, and contains all the thoracic viscera excepting the lungs. It may be divided for purposes of description into two parts: an upper portion, above the upper level of the pericardium, which is named the superior mediastinum; and a lower portion, below the upper level of the pericardium. This lower portion is again subdivided into three parts, viz., that in front of the pericardium, the anterior mediastinum; that containing the pericardium and its contents, the middle mediastinum; and that behind the pericardium, the posterior mediastinum.

**The Superior Mediastinum** is that portion of the interpleural space which lies between the manubrium sterni in front, and the upper thoracic vertebræ behind. It is bounded below by a slightly oblique plane passing backward from the junction of the manubrium and body of the sternum to the lower part of the body of the fourth thoracic vertebra, and laterally by the pleuræ. It contains the origins of the Sternohyoidei and Sternothyroidei and the lower ends of the Longicollii; the aortic arch; the innominate artery and the thoracic portions of the left common carotid and the left subclavian arteries; the innominate veins and the upper half of the superior vena cava; the left highest intercostal vein; the vagus, cardiac, phrenic, and left recurrent nerves; the trachea, esophagus, and thoracic duct; the remains of the thymus, and some lymph glands.

**The Anterior Mediastinum** exists only on the left side where the left pleura diverges from the mid-sternal line. It is bounded in front by the sternum, laterally by the pleuræ, and behind by the pericardium. It is narrow, above, but widens out a little below. Its anterior wall is formed by the left Transversusthoracis and the fifth, sixth, and seventh left costal cartilages. It contains a quantity of loose areolar tissue, some lymphatic vessels which ascend from the convex surface of the liver, two or three anterior mediastinal lymph glands, and the small mediastinal branches of the internal mammary artery.

**The Middle Mediastinum** is the broadest part of the interpleural space. It contains the heart enclosed in the pericardium, the ascending aorta, the lower half of the superior vena cava with the azygos vein opening into it, the bifurcation of the trachea and the two bronchi, the pulmonary artery dividing into its two branches, the right and left pulmonary veins, the phrenic nerves, and some bronchial lymph glands.

**The Posterior Mediastinum** is an irregular triangular space running parallel with the vertebral column; it is bounded in front by the pericardium above, and by the posterior surface of the diaphragm below, behind by the vertebral column from the lower border of the fourth to the twelfth thoracic vertebra, and on either side by the mediastinal pleura. It contains the thoracic part of the descending aorta, the azygos and the two hemiazygos veins, the vagus and splanchnic nerves, the esophagus, the thoracic duct, and some lymph glands.

## 5.0 SUMMARY

In this unit, you have learnt about the following:

- The diaphragm is the primary muscle of respiration. It is dome shaped and consists of a peripheral muscular part and central tendinous part
- The mediastinum extends from the sternum in front to the vertebral column behind, and
- The mediastinum contains all the thoracic viscera except the lungs. It may be divided for purposes of description into two parts: the superior mediastinum; This lower portion is again subdivided into three parts, viz., that in front of the pericardium, the anterior mediastinum; the part containing the pericardium and its contents, the middle mediastinum; and that behind the pericardium, the posterior mediastinum.

## **6.0 TUTOR MARKED ASSIGNMENTS**

**6.1 Activity** – See Laboratory Instructions as provided by facilitator

**6.2 Please answer the following questions:**

- i. Describe the anterior, medial and posterior mediastinum
- ii. Identify the major structures of the mediasternum.
- iii. Describe the structure, functions and innervations of the diaphragm.

## **7.0 REFERENCES AND OTHER RESOURCES**

1. Richard S. Snell (2012), Clinical Anatomy by Regions 9th Ed Lippincott Williams & Wilkins.
2. Moore, Keith L.; Dalley, Arthur F. (2006) Clinically Oriented Anatomy, 5th Ed Lippincott Williams & Wilkins.
3. Chummy S. Sinnatamby FRCS. (2011) LAST'S ANATOMY Regional and Applied Twelfth Edition.
4. Sadler T.W (2012), Langman's Medical Embryology 12th edition.
5. Keith L Moore, Persuade T.V.N (2018), The Developing Human Clinically Oriented Embryology 11th Edition Lippincott Williams & Wilkins

## **MODULE 3      THE DIGESTIVE SYSTEM**

### **Introduction**

Every cell of the body needs nourishment, yet most cells cannot leave their position in the body and travel to a food source, so the food must be converted to a usable form and delivered. The digestive system, with the help of the circulatory system, acts as a gigantic “meals on wheels”, providing nourishment to over a hundred trillion “customer” cells in the body. It also has its own quality control and waste disposal system.

### **Module objective**

At the end of this module, you should be able to:

- (i) Describe in details the various organs of the digestive system.

### **CONTENTS**

Unit 1	Anatomy of the Stomach
Unit 2	Anatomy of the Small Intestine
Unit 3	Anatomy of the Large Intestine
Unit 4	Other Accessory Organs of Digestion

## **UNIT 1      ANATOMY OF THE STOMACH**

### **CONTENT**

1.0	Introduction
2.0	Objectives
3.0	Main Content
	3.1 Anatomical position of the stomach
	3.2 Component parts of the stomach
	3.3 The vasculature and nerve supply to the stomach
	3.4 Gastric glands
4.0	Conclusion
5.0	Summary
6.0	Tutor Marked Assignments
7.0	References and other resources

### **1.0 INTRODUCTION**

The stomach is the most dilated part of the digestive tube, and is situated between the end of the esophagus and the beginning of the small

intestine. Its primary functions are to store food, mix food with stomach secretions into a semi-liquid material, and start protein digestion.

## 2.0 OBJECTIVES

At the end of this unit, you should be able to;

- Discuss the role of Stomach in digestion
- Describe the different parts and vasculature of the stomach.
- Describe the gastric glands

### 3.1 Anatomical position of the stomach

The **stomach** is an enlarged segment of the digestive tract in the left superior part of the abdomen. It lies in the epigastric, umbilical, and left hypochondriac regions of the abdomen, and occupies a recess bounded by the upper abdominal viscera, and completed in front and on the left side by the anterior abdominal wall and the diaphragm. The shape and position of the stomach are so greatly modified by changes within itself and in the surrounding viscera that no one form can be described as typical. The chief modifications are determined by:

- the amount of the stomach contents,
- the stage at which the digestive process has reached,
- the degree of development of the gastric musculature, and
- the condition of the adjacent intestines.

It is however possible by comparing a series of stomachs to determine certain markings more or less common to all. The stomach presents two openings, two borders or curvatures, and two surfaces.

#### Position of the Stomach

The position of the stomach varies with the posture, with the amount of the stomach contents and with the condition of the intestines on which it rests. In the erect posture the empty stomach is somewhat J-shaped; the part above the cardiac orifice is usually distended with gas; the pylorus descends to the level of the second lumbar vertebra and the most dependent part of the stomach is at the level of the umbilicus.

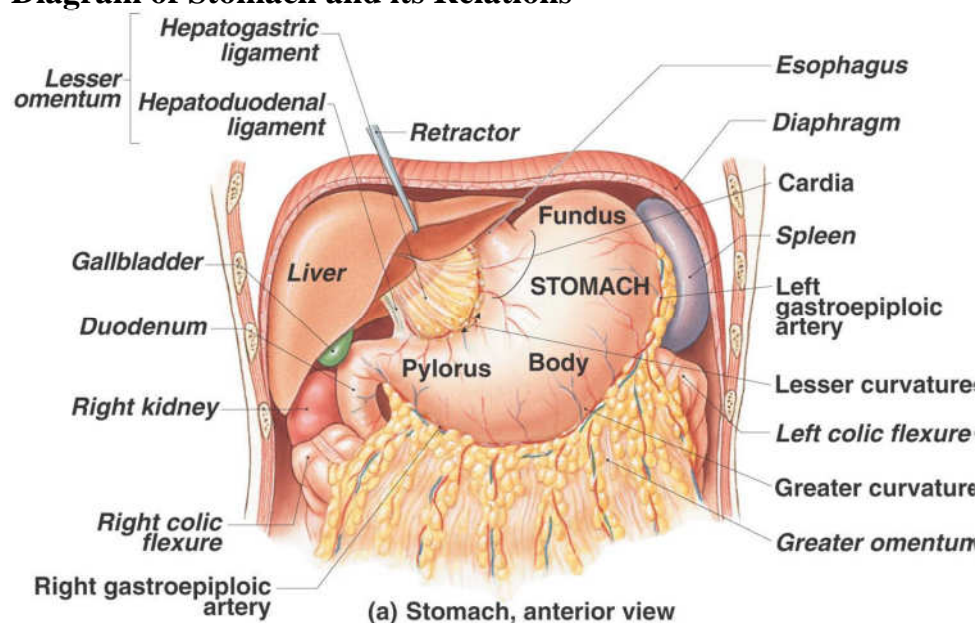
Variation in the amount of its contents affects mainly the cardiac portion, the pyloric portion remaining in a more or less contracted condition during the process of digestion.

As the stomach fills it tends to expand forward and downward in the direction of least resistance, but when this is interfered with by a distended condition of the colon or intestines the fundus presses upward on the liver and diaphragm and gives rise to the feelings of oppression and palpitation complained of in such cases, the contracted stomach has a sickle shape, the fundus looking directly backward. The surfaces are directed upward and downward, the upper surface having, however, a gradual downward slope to the right. The greater curvature is in front and at a slightly higher level than the lesser.

The position of the full stomach depends, as already indicated, on the state of the intestines; when these are empty the fundus expands vertically and also forward, the pylorus is displaced toward the right and the whole organ assumes an oblique position, so that its surfaces are directed more forward and backward. The lowest part of the stomach is at the pyloric vestibule, which reaches to the region of the umbilicus. Where the intestines interfere with the downward expansion of the fundus the stomach retains the horizontal position which is characteristic of the contracted viscus.

Examination of the stomach during life by x-rays has confirmed these findings, and has demonstrated that, in the erect posture, the full stomach usually presents a hook-like appearance, the long axis of the clinical fundus being directed downward, medialward, and forward toward the umbilicus, while the pyloric portion curves upward to the duodenopyloric junction.

### Diagram of Stomach and its Relations



**Fig. 1.1:**

## Openings

The opening by which the esophagus communicates with the stomach is known as the *cardiac orifice*, and is situated on the left of the middle line at the level of the tenth thoracic vertebra. The short abdominal portion of the esophagus (*antrum cardiacum*) is conical in shape and curved sharply to the left, the base of the cone being continuous with the cardiac orifice of the stomach. The right margin of the esophagus is continuous with the lesser curvature of the stomach, while the left margin joins the greater curvature at an acute angle, termed the *incisura cardiaca*.

The *pyloric orifice* communicates with the duodenum, and its position is usually indicated on the surface of the stomach by a circular groove, the duodenopyloric constriction. This orifice lies to the right of the middle line at the level of the upper border of the first lumbar vertebra.

## The Curvatures

### The lesser curvature (*curvaturaventriculi minor*)

This extends between the cardiac and pyloric orifices, forms the right or posterior border of the stomach. It descends as a continuation of the right margin of the esophagus in front of the fibers of the right crus of the diaphragm, and then, turning to the right, it crosses the first lumbar vertebra and ends at the pylorus. Nearer its pyloric than its cardiac end is a well-marked notch, the *incisura angularis*, which varies somewhat in position with the state of distension of the viscus; it serves to separate the stomach into a right and a left portion. The lesser curvature gives attachment to the two layers of the hepatogastric ligament, and between these two layers are the left gastric artery and the right gastric branch of the hepatic artery.

### The greater curvature (*curvaturaventriculi major*)

This is directed mainly forward, and is four or five times as long as the lesser curvature. Starting from the cardiac orifice at the *incisura cardiaca*, it forms an arch backward, upward, and to the left; the highest point of the convexity is on a level with the sixth left costal cartilage. From this level it may be followed downward and forward, with a slight convexity to the left as low as the cartilage of the ninth rib; it then turns to the right, to the end of the pylorus. Directly opposite the *incisura angularis* of the lesser curvature the greater curvature presents a



dilatation, which is the left extremity of the pyloric part; this dilatation is limited on the right by a slight groove, the sulcus intermedius, which is about 2.5 cm, from the duodenopyloric constriction.

The portion between the sulcus intermedius and the duodenopyloric constriction is termed the **pyloric antrum**. At its commencement, the greater curvature is covered by peritoneum continuous with that covering the front of the organ. The left part of the curvature gives attachment to the gastrosplenic ligament, while to its anterior portion are attached the two layers of the greater omentum, separated from each other by the gastroepiploic vessels.

## **Surfaces**

During contraction of the stomach, its surfaces are directed upward and downward respectively, but when the viscus is distended they are directed forward, and backward. They may therefore be described as anterosuperior and postero-inferior.

### **Antero-superior Surface**

The left half of this surface is in contact with the diaphragm, which separates it from the base of the left lung, the pericardium, and the seventh, eighth, and ninth ribs, and intercostal spaces of the left side. The right half is in relation with the left and quadrate lobes of the liver and with the anterior abdominal wall. When the stomach is empty, the transverse colon may lie on the front part of this surface. The whole surface is covered by peritoneum.

### **Postero-inferior Surface**

This is in relation with the diaphragm, the spleen, the left suprarenal gland, the upper part of the front of the left kidney, the anterior surface of the pancreas, the left colic flexure, and the upper layer of the transverse mesocolon. These structures form a shallow bed, the stomach bed, on which the viscus rests. The transverse mesocolon separates the stomach from the duodenojejunal flexure and small intestine. The postero-inferior surface is covered by peritoneum, except over a small area close to the cardiac orifice; this area is limited by the lines of attachment of the gastrophrenic ligament, and lies in apposition with the diaphragm, and frequently with the upper portion of the left suprarenal gland.

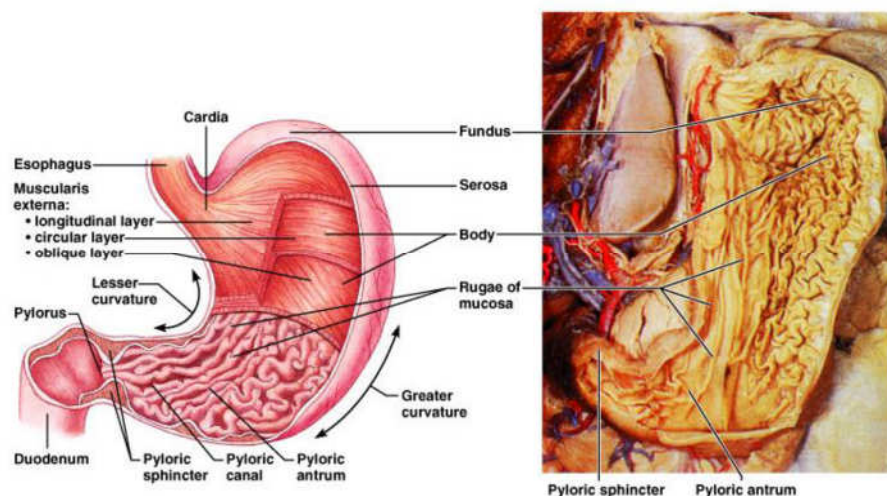
## Interior of the Stomach

When examined after death, the stomach is usually fixed at some temporary stage of the digestive process. If the viscus be laid open by a section through the plane of its two curvatures, it is seen to consist of two segments:

- (a) *a large globular portion on the left and (b) a narrow tubular part on the right.* These correspond to the clinical subdivisions of fundus and pyloric portions already described, and are separated by a constriction which indents the body and greater curvature, but does not involve the lesser curvature. To the left of the cardiac orifice is the incisuracardiaca: the projection of this notch into the cavity of the stomach increases as the organ distends, and has been supposed to act as a valve preventing regurgitation into the esophagus.

In the pyloric portion are seen:

- a. the elevation corresponding to the incisuraangularis, and
- b. the circular projection from the duodenopyloric constriction which forms the pyloric valve



**Fig. 1.2:**

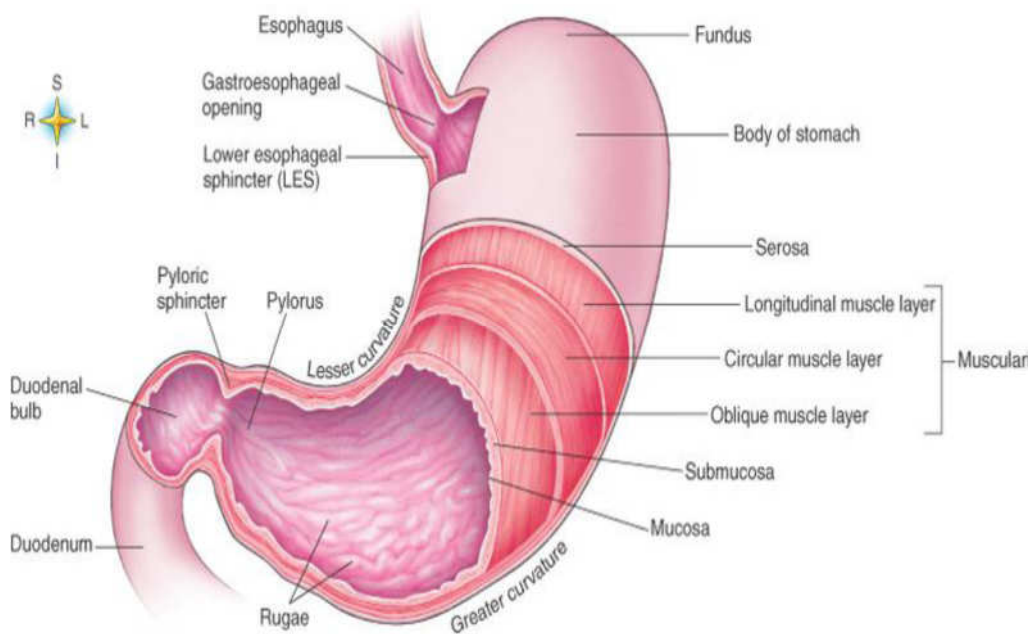
## Interior of the stomach

The pyloric valve (*valvula pylori*) is formed by a reduplication of the mucous membrane of the stomach, covering a muscular ring composed of a thickened portion of the circular layer of the muscular coat. Some of the deeper longitudinal fibers turn in and interlace with the circular fibers of the valve.

## 2.0 Component parts of the stomach

A plane passing through the incisura angularis on the lesser curvature and the left limit of the opposed dilatation on the greater curvature divides the stomach into a left portion or body and a right or pyloric portion. The left portion of the body is known as the **fundus**, and is marked off from the remainder of the body by a plane passing horizontally through the cardiac orifice.

The **pyloric portion** is divided by a plane through the sulcus intermedius at right angles to the long axis of this portion; the part to the right of this plane is the pyloric antrum



**Fig. 1.3:**

If the stomach be examined during the process of digestion it will be found divided by a muscular constriction into a large dilated left portion, and a narrow contracted tubular right portion. The constriction is in the body of the stomach, and does not follow any of the anatomical landmarks; indeed, it shifts gradually toward the left as digestion progresses, *i. e.*, more of the body is gradually absorbed into the tubular part.

### The wall of the stomach

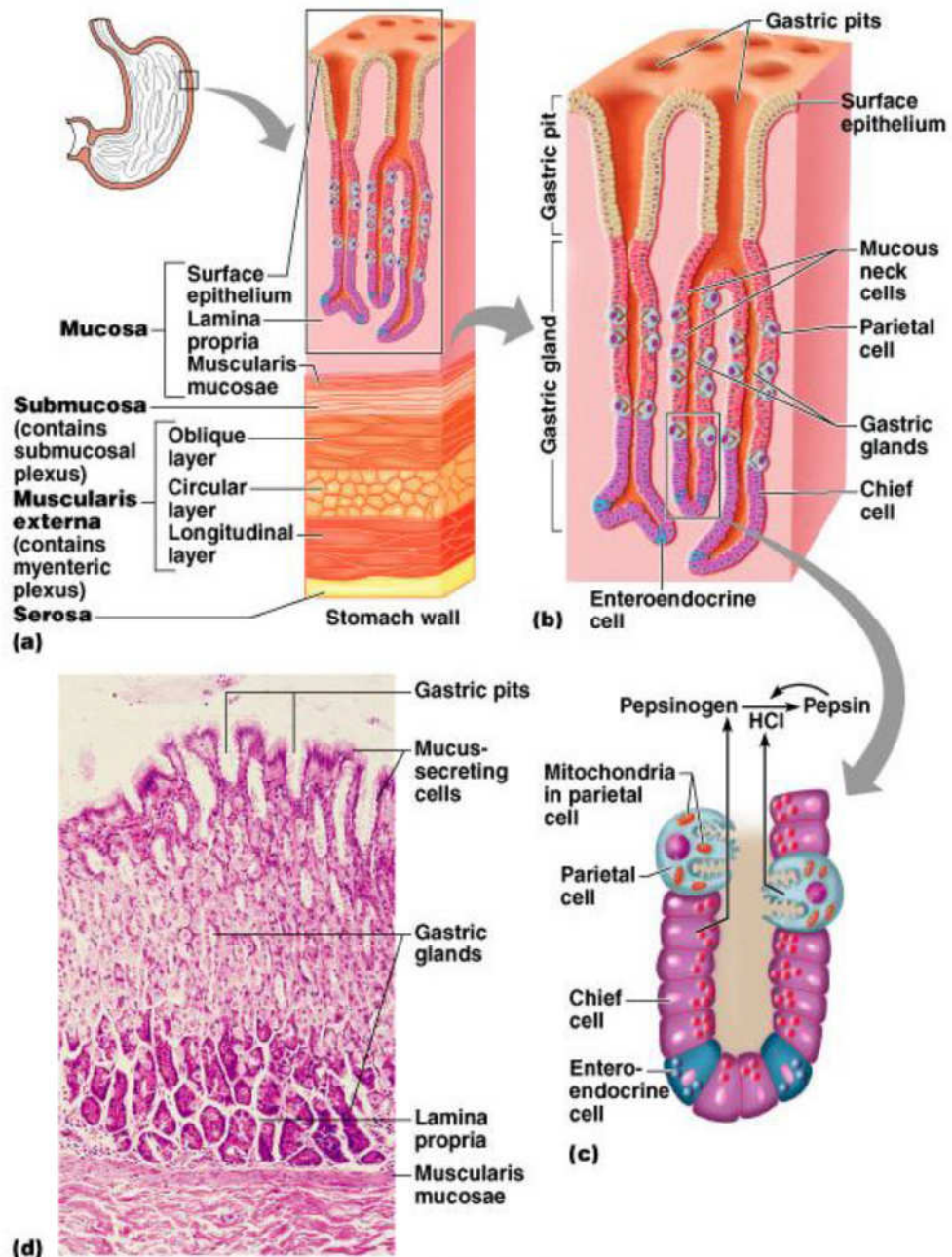
The wall of the stomach consists of four coats: serous, muscular, areolar, and mucous, together with vessels and nerves.

#### The serous coat (*tunica serosa*)

This is derived from the peritoneum, and covers the entire surface of the organ, excepting along the greater and lesser curvatures at the points of

attachment of the greater and lesser omenta; here the two layers of peritoneum leave a small triangular space, along which the nutrient vessels and nerves pass. On the posterior surface of the stomach, close to the cardiac orifice, there is also a small area uncovered by peritoneum, where the organ is in contact with the under surface of the diaphragm.

### Histology of the Stomach



**Fig 1.4:**

**The muscular coat** (*tunica muscularis*)

It is situated immediately beneath the serous covering, with which it is closely connected. It consists of three sets of smooth muscle fibers: longitudinal, circular and oblique.

The *longitudinal fibers* (*stratum longitudinale*) are the most superficial, and are arranged in two sets.

The first set consists of fibers continuous with the longitudinal fibers of the esophagus; they radiate in a stellate manner from the cardiac orifice and are practically all lost before the pyloric portion is reached. The second set commences on the body of the stomach and passes to the right, its fibers becoming more thickly distributed as they approach the pylorus. Some of the more superficial fibers of this set pass on to the duodenum, but the deeper fibers dip inward and interlace with the circular fibers of the pyloric valve.

The *circular fibers* (*stratum circulare*) form a uniform layer over the whole extent of the stomach beneath the longitudinal fibers. At the pylorus they are most abundant, and are aggregated into a circular ring, which projects into the lumen, and forms, with the fold of mucous membrane covering its surface, the pyloric valve. They are continuous with the circular fibers of the esophagus, but are sharply marked off from the circular fibers of the duodenum.

The *oblique fibers* (*fibræ obliquæ*) internal to the circular layer, are limited chiefly to the cardiac end of the stomach, where they are disposed as a thick uniform layer, covering both surfaces, some passing obliquely from left to right, others from right to left, around the cardiac end.

**The areolar or submucous coat** (*tela submucosa*) consists of a loose, areolar tissue, connecting the mucous and muscular layers.

**The mucous membrane** (*tunica mucosa*) is thick and its surface is smooth, soft, and velvety. In the fresh state it is of a pinkish tinge at the pyloric end, and of a red or reddish-brown color over the rest of its surface. In infancy it is of a brighter hue, the vascular redness being more marked. It is thin at the cardiac extremity, but thicker toward the pylorus. During the contracted state of the organ it is thrown into numerous plaits or rugæ, which, for the most part, have a longitudinal direction, and are most marked toward the pyloric end of the stomach, and along the greater curvature. These folds are entirely obliterated when the organ becomes distended.

### *Structure of the Mucous Membrane*

When examined with a lens, the inner surface of the mucous membrane presents a peculiar honeycomb appearance from being covered with small shallow depressions or alveoli, of a polygonal or hexagonal form, which vary from 0.12 to 0.25 mm. in diameter. These are the ducts of the gastric glands, and at the bottom of each may be seen one or more minute orifices, the openings of the gland tubes. The surface of the mucous membrane is covered by a single layer of columnar epithelium with occasional goblet cells. This epithelium commences very abruptly at the cardiac orifice, where there is a sudden transition from the stratified epithelium of the esophagus. The epithelial lining of the gland ducts is of the same character and is continuous with the general epithelial lining of the stomach.

### **3.3 The vasculature and nerve supply to the stomach**

**The arteries**-supplying the stomach are: the left gastric, the right gastric and right gastroepiploic branches of the hepatic, and the left gastroepiploic and short gastric branches of the ileal. They supply the muscular coat, ramify in the submucous coat, and are finally distributed to the mucous membrane. The arrangement of the vessels in the mucous membrane is somewhat peculiar. The arteries break up at the base of the gastric tubules into a plexus of fine capillaries which run upward between the tubules, anastomosing with each other, and ending in a plexus of larger capillaries, which surround the mouths of the tubes, and also form hexagonal meshes around the ducts.

**The veins** -arise, and pursue a straight course downward, between the tubules, to the submucous tissue; they end either in the lienal and superior mesenteric veins, or directly in the portal vein. The lymphatics are numerous: they consist of a superficial and a deep set, and pass to the lymph glands found along the two curvatures of the organ.

**The nerves** -are the terminal branches of the right and left vagi, the former being distributed upon the back, and the latter upon the front part of the organ. A great number of branches from the celiac plexus of the sympathetic are also distributed to it. Nerve plexuses are found in the submucous coat and between the layers of the muscular coat as in the intestine. From these plexuses fibrils are distributed to the muscular tissue and the mucous membrane.

### 3.4 The Gastric Glands

The gastric glands are of three kinds: (a) pyloric, (b) cardiac, and (c) fundus or oxyntic glands. They are tubular in character, and are formed of a delicate basement membrane, consisting of flattened transparent endothelial cells lined by epithelium.

**The pyloric glands** are found in the pyloric portion of the stomach. They consist of two or three short closed tubes opening into a common duct or mouth. These tubes are wavy, and are about one-half the length of the duct. The duct is lined by columnar cells, continuous with the epithelium lining the surface of the mucous membrane of the stomach, the tubes by shorter and more cubical cell which are finely granular.

**The cardiac glands** few in number, occur close to the cardiac orifice. They are of two kinds:

- simple tubular glands resembling those of the pyloric end of the stomach, but with short ducts;
- compound glands resembling the duodenal glands.

**The fundus glands** are found in the body and fundus of the stomach; they are simple tubes, two or more of which open into a single duct. The duct, however, in these glands is shorter than in the pyloric variety, sometimes not amounting to more than one-sixth of the whole length of the gland; it is lined throughout by columnar epithelium. The gland tubes are straight and parallel to each other. At the point where they open into the duct, which is termed the neck, the epithelium alters, and consists of short columnar or polyhedral, granular cells, which almost fill the tube, so that the lumen becomes suddenly constricted and is continued down as a very fine channel. They are known as the *chief* or *central* cells of the glands. Between these cells and the basement membrane, larger oval cells, which stain deeply with eosin, are found; these cells are studded throughout the tube at intervals, giving it a beaded or varicose appearance. These are known as the parietal or oxyntic cells, and they are connected with the lumen by fine channels which run into their substance. Between the glands the mucous membrane consists of a connective-tissue frame-work, with lymphoid tissue. In places, this later tissue, especially in early life, is collected into little masses, which to a certain extent resemble the solitary nodules of the intestine, and are termed the lenticular glands of the stomach. They are not, however, so distinctly circumscribed as the solitary nodules. Beneath the mucous membrane, and between it and the submucous coat, is a thin stratum of involuntary muscular fiber (*muscularis mucosæ*), which in some parts consists only of a single longitudinal layer; in others of two layers, an inner circular and an outer longitudinal.

## 5.0 SUMMARY

In this unit, you have learnt about the following:

- The location of the stomach-left superior part of the abdomen
- The various modifying factors that determine the shape and size of the stomach.
- The structure of the stomach
- Details about the gastric glands and the roles of the stomach indigestion.

### Clinical correlates

**Gastroesophageal reflux disease (GERD)**, or heartburn, is a painful or burning sensation in the chest associated with the reflux of acidic chyme into the esophagus. The pain is usually short-lived but may be confused with the pain of an ulcer or a heart attack. Overeating, eating fatty foods, lying down immediately after a meal, consuming too much alcohol or caffeine, smoking, and wearing extremely tight clothing can all cause heartburn. A hiatal hernia can also cause heartburn, especially in older people. Drugs that neutralize gastric acid or reduce gastric acid production can effectively treat GERD.

### Treatment of Excess Acid Secretion

**Antacids** are bases, such as  $\text{CaCO}_3$ ,  $\text{Al}(\text{OH})_3$ , and  $\text{Mg}(\text{OH})_2$ , that neutralize gastric acid when ingested. They are fast acting but have relatively short duration of effect. Antacids are effective for up to 30 minutes on an empty stomach and neutralize acid for 2 to 3 hours when taken with food. Long-term self-treatment with antacids should be avoided because the cause of excess acid production should be determined. Also, there are more effective treatments

**H<sub>2</sub>-receptor antagonists** are drugs that block the histamine receptor on parietal cells. Recall that histamine, gastrin, and acetylcholine stimulate parietal cells to secrete acid and that histamine has the greatest stimulatory effect. H<sub>2</sub> receptors are the type of histamine receptor on parietal cells. Cimetidine (Tagamet), ranitidine (Zantac), and famotidine (Pepcid) are H<sub>2</sub>-receptor antagonists that bind reversibly to H<sub>2</sub> receptors. They suppress 24-hour gastric acid secretion approximately 70%. The H<sub>2</sub> receptors are different from the H<sub>1</sub> receptors involved in allergic reactions.

Antihistamines that block allergic reactions do not affect histamine-mediated gastric acid secretion, and vice versa.



**Proton pump inhibitors** bind irreversibly with the H<sup>+</sup>–K<sup>+</sup> exchange pump in parietal cells. The pump is inactivated, and acid secretion does not resume until a new pump molecule is manufactured and inserted into the plasma membrane. Proton pump inhibitors effectively reduce acid secretion for 24 to 48 hours

## 6.0 TUTOR MARKED ASSIGNMENTS

**6.1 Activity** – As provided by the Facilitator

**6.2** Please answer the following questions:

- i. Discuss the role of Stomach in digestion
- ii. Describe the different parts and vasculature of the stomach.
- iii. Describe the gastric glands

### 1. The stomach

- a. has large folds in the submucosa and mucosa called rugae.
  - b. has two layers of smooth muscle in the muscularis layer.
  - c. opening from the esophagus is the pyloric orifice.
  - d. has an area closest to the duodenum called the fundus.
  - e. all of the above.
2. Which of these stomach cell types is *not* correctly matched with its function?
- a. surface mucous cells—produce mucus
  - b. parietal cells—produce hydrochloric acid
  - c. chief cells—produce intrinsic factor
  - d. endocrine cells—produce regulatory hormones
3. HCl
- a. is an enzyme.
  - b. creates the acid condition necessary for pepsin to work.
  - c. is secreted by the small intestine.
  - d. activates salivary amylase.
  - e. all of the above.
4. Why doesn't the stomach digest itself?
- a. The stomach wall is not composed of protein, so it is not affected by proteolytic enzymes.
  - b. The digestive enzymes of the stomach are not strong enough to digest the stomach wall.
  - c. The lining of the stomach wall has a protective layer of epithelial cells.
  - d. The stomach wall is protected by large amounts of mucus.

5. Which of these hormones stimulates stomach secretions?
  - a. cholecystokinin
  - b. insulin
  - c. gastrin
  - d. secretin
  
6. Which of these phases of stomach secretion is correctly matched?
  - a. cephalic phase—the largest volume of secretion is produced
  - b. gastric phase—gastrin secretion is inhibited by distension of the stomach
  - c. gastric phase—initiated by chewing, swallowing, or thinking of food
  - d. intestinal phase—stomach secretions are inhibited
7. While anesthetized, patients sometimes vomit. Given that the anesthetic eliminates the swallowing reflex, explain why it is dangerous for an anesthetized patient to vomit.

## **7.0 REFERENCES AND OTHER RESOURCES**

Hutchinson, M., Mallat, J., Marieb, E.N., Wilhelm P.B. (2007). *A Brief Atlas of the Human Body*. San Francisco: Pearson Education Inc.

Katherine M. A. Rogers and William N. Scott (2011) *Nurses! Test Yourself in Anatomy and Physiology*

Kathryn A. Booth, Terri. D. Wyman (2008) *Anatomy, Physiology, and Pathophysiology for Allied Health*

Keith L Moore, Persuade T.V.N (2006), *The Developing Human Clinically Oriented Embryology 8th Edition* Lippincott Williams & Wilkins.

Kent M. Van De Graff, R.Ward Rhees, Sidney Palmer (2010) *Schaum's Outline of human Anatomy and Physiology 3rd edition*.

Philip Tate (2012) Seeley's Principles of Anatomy & Physiology 2nd ed.

Sadler T.W (2004), Langman's Medical Embryology 9th edition.

Seeley's Principles of Anatomy & Physiology, Second edition Published by McGraw-Hill, a business unit of The McGraw-Hill Companies, Inc., 1221 Avenue of the Americas, New York, NY 10020. Copyright c 2012- Chapter 17&18

## UNIT 2 THE SMALL INTESTINE

### CONTENT

- 1.0 Introduction
- 2.0 Objectives
- 3.0 Main Content
  - 3.1 The Gross anatomy of the small intestine
  - 3.2 The structure of the small intestine
  - 3.3 Asculature of the small intestine
  - 3.4 The nerve supply to the small intestine
- 4.0 Conclusion
- 5.0 Summary
- 6.0 Tutor Marked Assignments
- 7.0 References and other resources

### 1.0 INTRODUCTION

The small intestine is where the greatest amount of digestion and absorption occur. It consists of three parts: the duodenum, the jejunum, and the ileum. The entire small intestine is about 7 m long (range: 4.6–9 m). The duodenum is about 25 cm long (*duodenum* means 12, suggesting that it is 12 inches long), the jejunum is about 2.5 m long, and the ileum is about 3.5 m long. Two major accessory glands, the liver and the pancreas, are associated with the duodenum.

### 2.0 OBJECTIVES

At the end of this unit, you should be able to;

- Describe the location and regions of the small intestine and the way in which it is supported.
- List the functions of the small intestine and describe the structural adaptations through which these functions are accomplished.
- Describe the movements that occur within the small intestine.

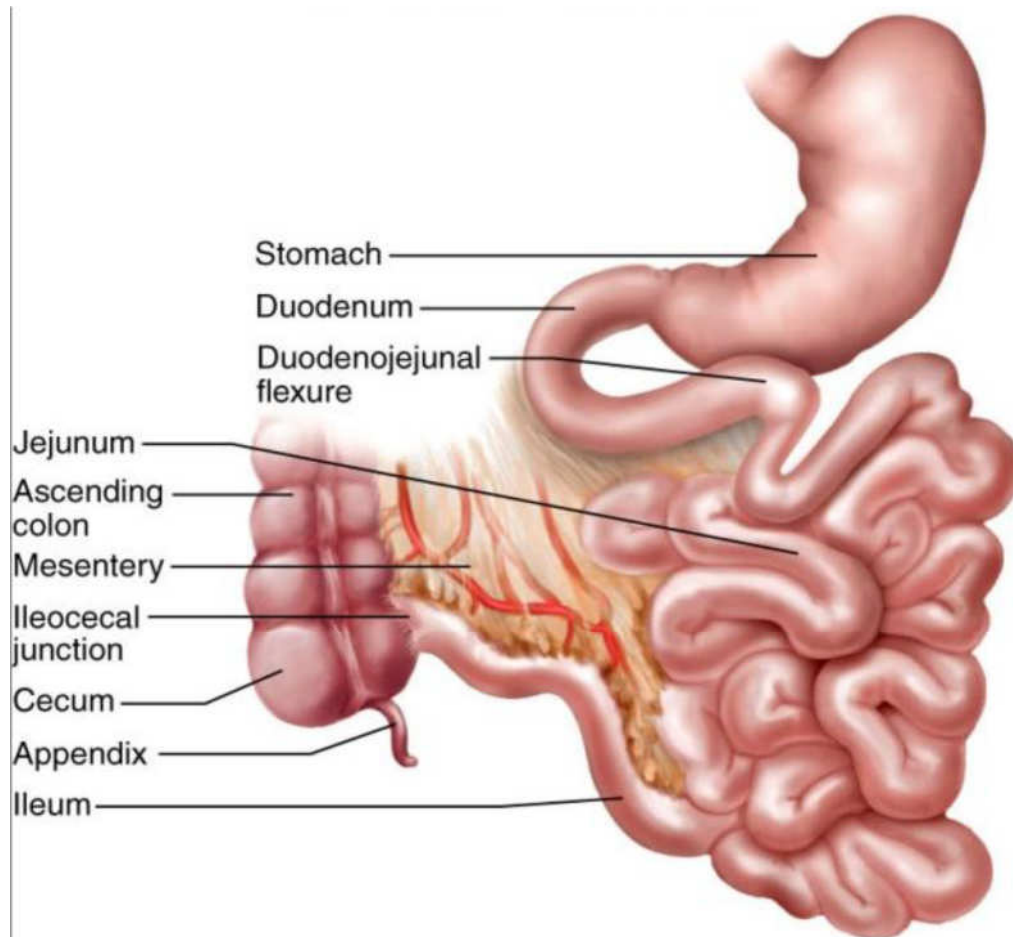
### 3.0 MAIN CONTENT

#### 3.1 The gross anatomy of the small intestine

The small intestine is a convoluted tube, extending from the pylorus to the colic valve, where it ends in the large intestine. It is contained in the central and lower part of the abdominal cavity, and is surrounded above and at the sides by the large intestine; a portion of it extends below the superior aperture of the pelvis and lies in front of the rectum. It is in relation, in front, with the greater omentum and abdominal parietes, and

is connected to the vertebral column by a fold of peritoneum, the mesentery.

The small intestine is divisible into three portions: the duodenum, the jejunum, and the ileum.



**Fig. 2.1:** The small intestine

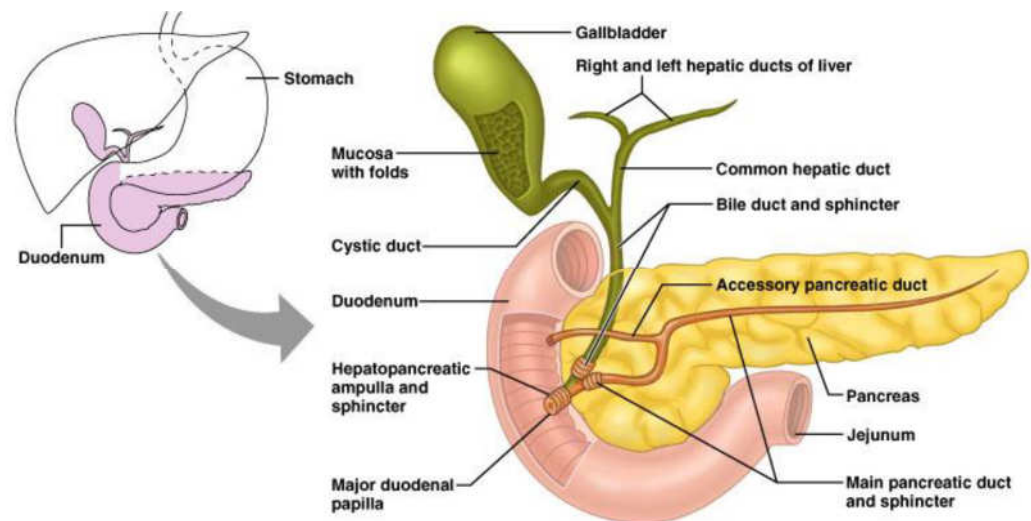
### The Duodenum

It received its name from being about equal in length to the breadth of twelve fingers (25 cm.). It is the shortest, the widest, and the most fixed part of the small intestine, and has no mesentery, being only partially covered by peritoneum.

Its course presents a remarkable curve, somewhat of the shape of an imperfect circle, so that its termination is not far removed from its starting-point. In the adult the course of the duodenum is as follows: commencing at the pylorus it passes backward, upward, and to the right, beneath the quadrate lobe of the liver to the neck of the gall-bladder, varying slightly in direction according to the degree of distension of the stomach: it then takes a sharp curve and descends along the right margin

of the head of the pancreas, for a variable distance, generally to the level of the upper border of the body of the fourth lumbar vertebra.

It now takes a second bend, and passes from right to left across the vertebral column, having a slight inclination upward; and on the left side of the vertebral column it ascends for about 2.5 cm, and then ends opposite the second lumbar vertebra in the jejunum. As it unites with the jejunum it turns abruptly forward, forming the duodenojejunal flexure. Duodenum may be divided into four portions: superior, descending, horizontal, and ascending.



**Fig. 2.2:** Relations

***The superior portion (pars superior; first portion)***

It is about 5 cm. long. Beginning at the pylorus, it ends at the neck of the gall-bladder. It is the most movable of the four portions. It is almost completely covered by peritoneum, but a small part of its posterior surface near the neck of the gall-bladder and the inferior vena cava is uncovered; the upper border of its first half has the hepatoduodenal ligament attached to it, while to the lower border of the same segment the greater omentum is connected.

It is in such close relation with the gall-bladder that it is usually found to be stained by bile after death, especially on its anterior surface. It is in relation above and in front with the quadrate lobe of the liver and the gall-bladder; behind with the gastroduodenal artery, the common bile duct, and the portal vein; and below and behind with the head and neck of the pancreas.

***The descending portion (pars descendens; second portion)***

This is between 7 to 10 cm. long, and extends from the neck of the gall-bladder, on a level with the first lumbar vertebra, along the right side of the vertebral column as low as the upper border of the body of the fourth lumbar vertebra. It is crossed in its middle third by the transverse colon, the posterior surface of which is uncovered by peritoneum and is connected to the duodenum by a small quantity of connective tissue. The supra- and infracolic portions are covered in front by peritoneum, the infracolic part by the right leaf of the mesentery. Posteriorly the descending portion of the duodenum is not covered by peritoneum.

The descending portion is in relation, in front, from above downward, with the duodenal impression on the right lobe of the liver, the transverse colon, and the small intestine; behind, it has a variable relation to the front of the right kidney in the neighborhood of the hilum, and is connected to it by loose areolar tissue; the renal vessels, the inferior vena cava, and the Psoas below, are also behind it. At its medial side is the head of the pancreas, and the common bile duct; to its lateral side is the right colic flexure. The common bile duct and the pancreatic duct together perforate the medial side of this portion of the intestine obliquely, some 7 to 10 cm. below the pylorus; the accessory pancreatic duct sometimes pierces it about 2 cm. above and slightly in front of these.

**The horizontal portion** (*pars horizontalis*; third or preaortic or transverse portion)

It is from 5 to 7.5 cm. long. It begins at the right side of the upper border of the fourth lumbar vertebra and passes from right to left, with a slight inclination upward, in front of the great vessels and crura of the diaphragm, and ends in the ascending portion in front of the abdominal aorta. It is crossed by the superior mesenteric vessels and the mesentery. Its front surface is covered by peritoneum, except near the middle line, where it is crossed by the superior mesenteric vessels. Its posterior surface is uncovered by peritoneum, except toward its left extremity, where the posterior layer of the mesentery may sometimes be found covering it to a variable extent. This surface rests upon the right crus of the diaphragm, the inferior vena cava, and the aorta. The upper surface is in relation with the head of the pancreas.

**The ascending portion** (*pars ascendens*; fourth portion)

It is about 2.5 cm long. It ascends on the left side of the aorta, as far as the level of the upper border of the second lumbar vertebra, where it turns abruptly forward to become the jejunum, forming the duodenojejunal flexure. It lies in front of the left Psoas major and left

renal vessels, and is covered in front and partly at the sides, by peritoneum continuous with the left portion of the mesentery.

The superior part of the duodenum, as stated above is somewhat movable, but the rest is practically fixed, and is bound down to neighboring viscera and the posterior abdominal wall by the peritoneum. In addition to this, the ascending part of the duodenum and the duodenojejunal flexure are fixed by a structure to which the name of *Musculus suspensorius duodeni* has been given. This structure commences in the connective tissue around the celiac artery and left crus of the diaphragm, and passes downward to be inserted into the superior border of the duodenojejunal curve and a part of the ascending duodenum, and from this it is continued into the mesentery.

It possesses, according to Treitz, plain muscular fibers mixed with the fibrous tissue of which it is principally made up. It is of little importance as a muscle, but acts as a suspensory ligament.

### **Vessels and Nerves**

The arteries supplying the duodenum are the right gastric and superior pancreaticoduodenal branches of the hepatic, and the inferior pancreaticoduodenal branch of the superior mesenteric. The veins end in the lienal and superior mesenteric. The nerves are derived from the celiac plexus. The remainder of the small intestine from the end of the duodenum is named jejunum and ileum; the former term being given to the upper two-fifths and the latter to the lower three-fifths. There is no morphological line of distinction between the two, and the division is arbitrary; but at the same time the character of the intestine gradually undergoes a change from the commencement of the jejunum to the end of the ileum, so that a portion of the bowel taken from these two situations would present characteristic and marked differences.

### **The Jejunum**

(*intestinum jejunum*) is wider, its diameter being about 4 cm., and is thicker, more vascular, and of a deeper color than the ileum, so that a given length weighs more. The circular folds (*valvulae conniventes*) of its mucous membrane are large and thickly set, and its villi are larger than in the ileum. The aggregated lymph nodules are almost absent in the upper part of the jejunum, and in the lower part are less frequently found than in the ileum, and are smaller and tend to assume a circular form. By grasping the jejunum between the finger and thumb the circular folds can be felt through the walls of the gut; these being absent in the lower part of the ileum, it is possible in this way to distinguish the upper from the lower part of the small intestine.



**The Ileum** (*intestinum ileum*)

It is narrow, its diameter being 3.75 cm, and its coats thinner and less vascular than those of the jejunum. It possesses but few circular folds, and they are small and disappear entirely toward its lower end, but aggregated lymph nodules (Peyer's patches) are larger and more numerous.

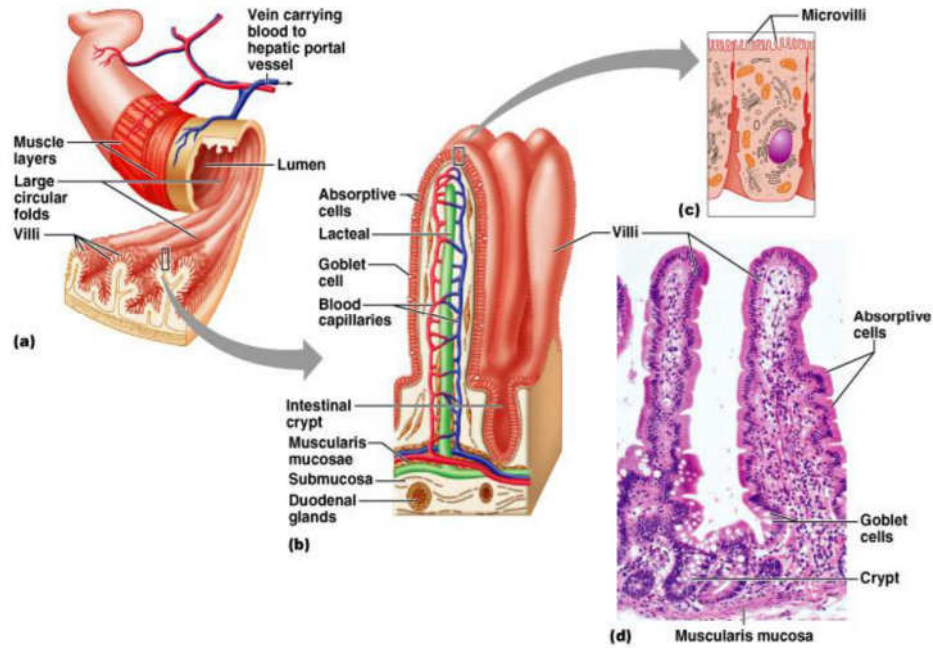
The jejunum forms the most part that occupies the umbilical and left iliac regions, while the ileum occupies chiefly the umbilical, hypogastric, right iliac, and pelvic regions. The terminal part of the ileum usually lies in the pelvis, from which it ascends over the right Psoas and right iliac vessels; it ends in the right iliac fossa by opening into the medial side of the commencement of the large intestine. The jejunum and ileum are attached to the posterior abdominal wall by an extensive fold of peritoneum, the mesentery, which allows the freest motion, so that each coil can accommodate itself to changes in form and position. The mesentery is fan-shaped; its posterior border or root, about 15 cm. long, is attached to the posterior abdominal wall from the left side of the body of the second lumbar vertebra to the right sacroiliac articulation, crossing successively. The horizontal part of the duodenum, the aorta, the inferior vena cava, the ureter, and right Psoas muscle. Its breadth between its vertebral and intestinal borders averages about 20 cm, and is greater in the middle than at its upper and lower ends.

**Meckel's Diverticulum** (*diverticulum ilei*)

This consists of a pouch which projects from the lower part of the ileum in about 2 per cent of subjects. Its average position is about 1 meter above the colic valve, and its average length about 5 cm. Its caliber is generally similar to that of the ileum, and its blind extremity may be free or may be connected with the abdominal wall or with some other portion of the intestine by a fibrous band. It represents the remains of the vitelline duct, the duct of communication between the yolk-sac and the primitive digestive tube in early fetal life.

**3.2 The structure of the small intestine**

The wall of the small intestine is composed of four coats: serous, muscular, areolar, and mucous.



**Fig. 2.3:**

### **The serous coat (*tunica serosa*)**

It is derived from the peritoneum. The superior portion of the duodenum is almost completely surrounded by this membrane near its pyloric end, but is only covered in front at the other extremity; the descending portion is covered by it in front, except where it is carried off by the transverse colon; and the inferior portion lies behind the peritoneum which passes over it without being closely incorporated with the other coats of this part of the intestine, and is separated from it in and near the middle line by the superior mesenteric vessels. The rest of the small intestine is surrounded by the peritoneum, excepting along its attached or mesenteric border; here a space is left for the vessels and nerves to pass to the gut.

### **The muscular coat (*tunica muscularis*)**

This consists of two layers of unstriated fibers: an external, longitudinal, and an internal, circular layer. The *longitudinal fibers* are thinly scattered over the surface of the intestine, and are more distinct along its free border. The *circular fibers* form a thick, uniform layer, and are composed of plain muscle cells of considerable length. The muscular coat is thicker at the upper than at the lower part of the small intestine.

### **The areolar or submucous coat** (*tela submucosa*)

It connects together the mucous and muscular layers. It consists of loose, filamentous areolar tissue containing bloodvessels, lymphatics, and nerves. It is the strongest layer of the intestine.

### **The mucous membrane** (*tunica mucosa*)

It is thick and highly vascular at the upper part of the smallintestine, but somewhat paler and thinner below. It consists of the following structures: next the areolar or submucous coat is a double layer of unstriated muscular fibers, outer longitudinal and inner circular, the muscularis mucosæ; internal to this is a quantity of retiform tissue, enclosing in its meshes lymph corpuscles, and in this the blood vessels and nerves ramify; lastly, a basement membrane, supporting a single layer of epithelial cells, which throughout the intestine are columnar in character.

The cells are granular in appearance, and each possesses a clear oval nucleus. At their superficial or unattached ends, they present a distinct layer of highly refracting material, marked by vertical striæ, the striated border.

### **The circular folds**

(*plicæ circulares* [*Kerkringi*]; *valvulæ conniventes*; *valves of Kerkring*)

These are large valvular flaps projecting into the lumen of the bowel. They are composed of reduplications of the mucous membrane, the two layers of the fold being bound together by submucous tissue; unlike the folds in the stomach, they are permanent, and are not obliterated when the intestine is distended. The majority extend transversely around the cylinder of the intestine for about one-half or two-thirds of its circumference, but some form complete circles, and others have a spiral direction; the latter usually extend a little more than once around the bowel, but occasionally two or three times. The larger folds are about 8 mm. in depth at their broadest part; but the greater numbers are of smaller size. The larger and smaller folds alternate with each other. They are not found at the commencement of the duodenum, but begin to appear about 2.5 or 5 cm. beyond the pylorus.

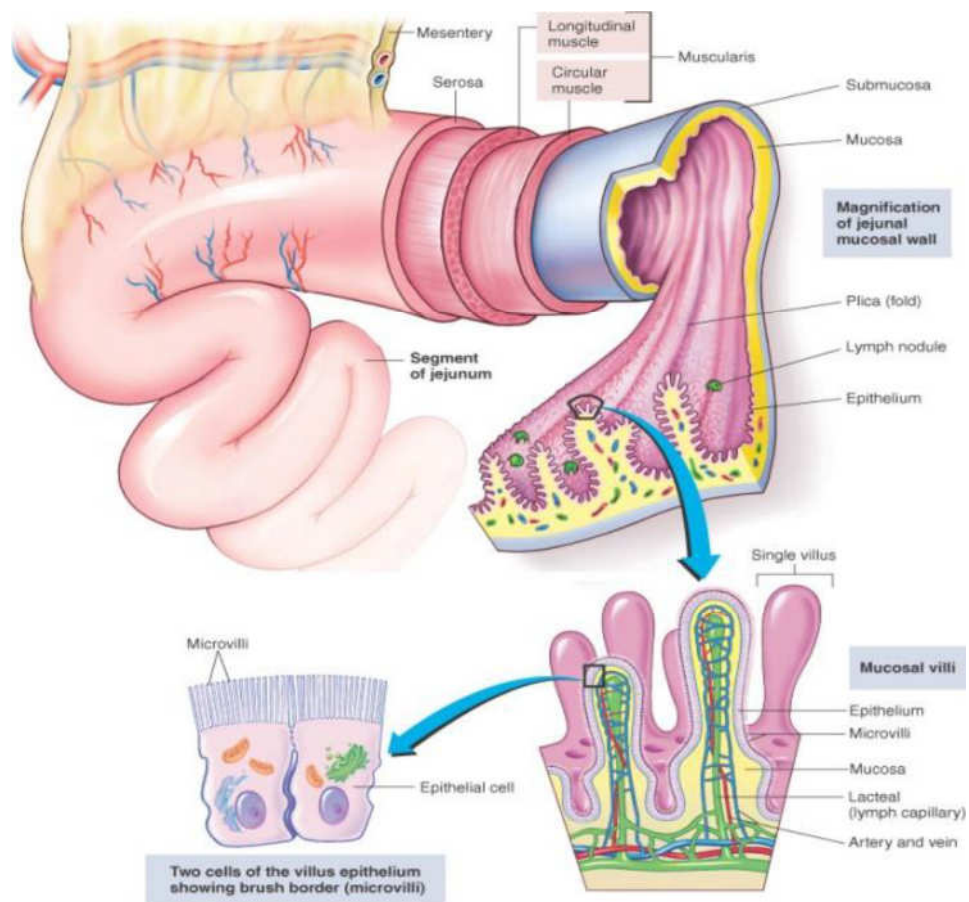
In the lower part of the descending portion, below the point where the bile and pancreatic ducts enter the intestine, they are very large and closely approximated. In the horizontal and ascending portions of the duodenum and upper half of the jejunum they are large and numerous, but from this point, down to the middle of the ileum, they diminish

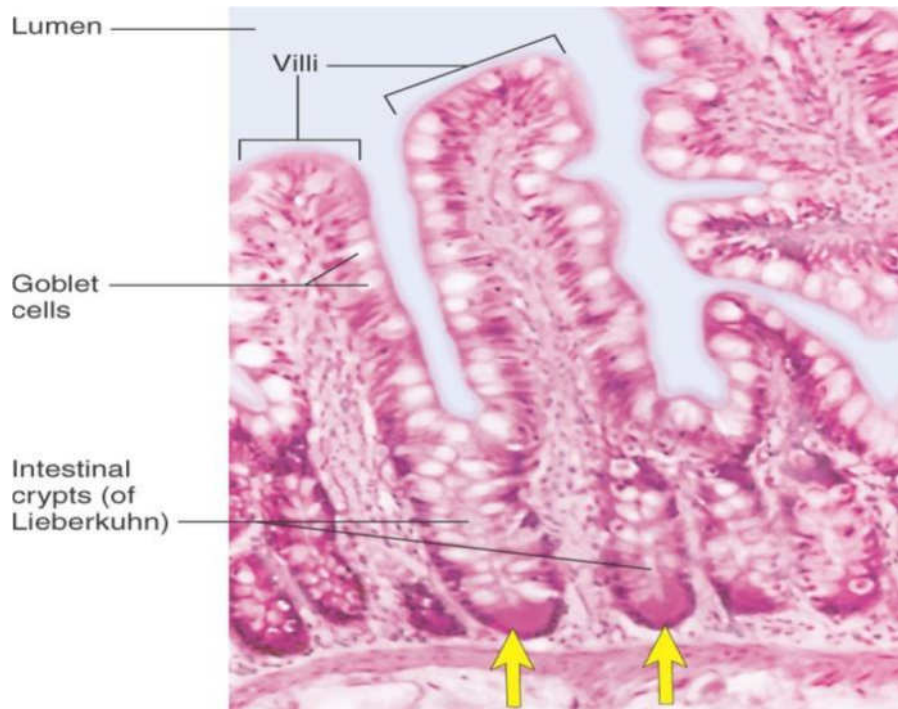
considerably in size. In the lower part of the ileum they almost entirely disappear; hence the comparative thinness of this portion of the intestine, as compared with the duodenum and jejunum. The circular folds retard the passage of the food along the intestines, and afford an increased surface for absorption.

### The intestinal villi

They are highly vascular processes, projecting from the mucous membrane of the small intestine throughout its whole extent, and giving to its surface a velvety appearance. They are largest and most numerous in the duodenum and jejunum, and become fewer and smaller in the ileum.

The essential parts of a villus are: the lacteal vessel, the blood vessels, the epithelium, the basement membrane, and the muscular tissue of the mucosa, all being supported and held together by retiform lymphoid tissue. The *lacteals* are in some cases double, and in some animals, multiple but usually there is a single vessel. Situated in the axis of the villus, each commences by dilated cecal extremities near to, but not quite at, the summit of the villus. The walls are composed of a single layer of endothelial cells.





**Fig 2.4:**

### **The muscular fibers**

These are derived from the muscularismucosæ, and are arranged in longitudinal bundles around the lacteal vessel, extending from the base to the summit of the villus, and giving off, laterally, individual muscle cells, which are enclosed by the reticulum, and by it are attached to the basement-membrane and to the lacteal.

The *blood vessels* form a plexus under the basement membrane, and are enclosed in the reticular tissue. These structures are surrounded by the *basement membrane*, which is made up of a stratum of endothelial cells, and upon this is placed a layer of *columnar epithelium*,. The *retiform tissue* forms a net-work in the meshes of which a number of leucocytes are found.

### **The intestinal glands**

(*glandulæ intestinales*[*Lieberkühni*]; *crypts of Lieberkühn*) considerable numbers over every part of the mucous membrane of the small intestine. They consist of minute tubular depressions of the mucous membrane, arranged perpendicularly to the surface, upon which they open by small circular apertures. They may be seen with the aid of a lens, their orifices appearing as minute dots scattered between the villi. Their walls are thin, consisting of a basement membrane lined by columnar epithelium, and covered on their exterior by capillary vessels.

### **The duodenal glands**

(*glandulæduodenales*[*Brunneri*]; *Brunner's glands*) are limited to the duodenum and are found in the submucous areolar tissue. They are largest and most numerous near the pylorus, forming an almost complete layer in the superior portion and upper half of the descending portions of the duodenum. They then begin to diminish in number, and practically disappear at the junction of the duodenum and jejunum. They are small compound acinotubular glands consisting of a number of alveoli lined by short columnar epithelium and opening by a single duct on the inner surface of the intestine.

### **The solitary lymphatic nodules**

(*nodulilymphaticisolitarii*; *solitary glands*) are found scattered throughout the mucous membrane of the small intestine, but are most numerous in the lower part of the ileum. Their free surfaces are covered with rudimentary villi, except at the summits, and each gland is surrounded by the openings of the intestinal glands. Each consists of a dense interlacing retiform tissue closely packed with lymph-corpuscles, and permeated with an abundant capillary network. The interspaces of the retiform tissue are continuous with larger lymph spaces which surround the gland, through which they communicate with the lacteal system. They are situated partly in the submucous tissue, partly in the mucous membrane, where they form slight projections of its epithelial layer.

### **The aggregated lymphatic nodules**

(*nodulilymphaticiaggregati*; *Peyer's patches*; *Peyer's glands*; *agminated follicles*; *tonsillæintestinales*) form circular or oval patches, from twenty to thirty in number, and varying in length from 2 to 10 cm. They are largest and most numerous in the ileum. In the lower part of the jejunum they are small, circular, and few in number. They are occasionally seen in the duodenum. They are placed lengthwise in the intestine, and are situated in the portion of the tube most distant from the attachment of the mesentery. Each patch is formed of a group of solitary lymphatic nodules covered with mucous membrane, but the patches do not, as a rule, possess villi on their free surfaces. They are best marked in the young subject, become indistinct in middle age, and sometimes disappear altogether in advanced life. They are freely supplied with blood vessels which form an abundant plexus around each follicle and give off fine branches permeating the lymphoid tissue in the interior of the follicle. The lymphatic plexuses are especially abundant around these patches.

### 3.3 Vasculature of the small intestine

**The arteries-** jejunum and ileum are supplied by **the superior mesenteric artery**, the intestinal branches of which, having reached the attached border of the bowel, run between the serous and muscular coats, with frequent inosculation to the free border, where they also anastomose with other branches running around the opposite surface of the gut. From these vessels numerous branches are given off, which pierce the muscular coat, supplying it and forming an intricate plexus in the submucous tissue. From this plexus minute vessels pass to the glands and villi of the mucous membrane.

The veins have a similar course and arrangement to the arteries. The lymphatics of the small intestine (lacteals) are arranged in two sets, those of the mucous membrane and those of the muscular coat. The lymphatics of the villi commence in these structures in the manner described above. They form an intricate plexus in the mucous and submucous tissue, being joined by the lymphatics from the lymph spaces at the bases of the solitary nodules, and from this pass to larger vessels at the mesenteric border of the gut.

The lymphatics of the muscular coat are situated to a great extent between the two layers of muscular fibers, where they form a close plexus; throughout their course they communicate freely with the lymphatics from the mucous membrane, and empty themselves in the same manner as these into the origins of the lacteal vessels at the attached border of the gut.

### 3.4 The nerve supply to the small intestine

**The nerves** -of the small intestines are derived from the plexuses of **sympathetic nerves** around the superior mesenteric artery. From this source they run to the **myenteric plexus** (*Auerbach's plexus*) of nerves and ganglia situated between the circular and longitudinal muscular fibers from which the nervous branches are distributed to the muscular coats of the intestine.

From this a secondary plexus, the plexus of the **submucosa** (*Meissner's plexus*) is derived, and is formed by branches which have perforated the circular muscular fibers. This plexus lies in the submucous coat of the intestine; it also contains ganglia from which nerve fibers pass to the muscularis mucosæ and to the mucous membrane. The nerve bundles of the submucous plexus are finer than those of the myenteric plexus.

## 4.0 CONCLUSION

The small intestine is where the greatest amount of digestion and absorption occur. It consists of three parts: the duodenum, the jejunum, and the ileum. The structure of the small intestine – serous coat, muscular coat, areolar coat, mucous membrane, circular folds, the intestinal glands, The vasculature of the small intestine - jejunum and ileum are supplied by the superior mesenteric artery, the veins have a similar course and arrangement to the arteries.

## 5.0 SUMMARY

In this unit, you have learnt about the following:

- The Gross anatomy of the small intestine
- The Structure of the small intestine
- Vasculature of the small intestine
- The Nerve supply to the small intestine

### Clinical correlates

Peptic ulcers can occur in the duodenum and stomach. Duodenal ulcers are in the duodenum, usually near the pyloric sphincter. Approximately 80% of all peptic ulcers are duodenal ulcers. The most common contributing factor to developing duodenal ulcers is the over secretion of gastric juices relative to the degree of mucous and alkaline protection of the small intestine. People who experience severe anxiety over a long period are the most prone to developing duodenal ulcers. They often have a rate of gastric secretion between meals that is as much as 15 times the normal amount.

## 6.0 TUTOR MARKED ASSIGNMENTS

### 6.1 Activity

- i. What are the primary functions of the small intestine?
- ii. List four structural modifications of the small intestine that increase its absorptive surface area.
- iii. Describe the movements of the small intestine. Which movements are produced by the circular layer of the tunica muscularis?



**6.2** Please answer the following questions:

- i. Describe the location and regions of the small intestine and the way in which it is supported.
  - ii. List the functions of the small intestine and describe the structural adaptations through which these functions are accomplished.
- Describe the movements that occur within the small intestine.
1. Which of these structures increase the mucosal surface of the small intestine?
    - a. circular folds
    - b. villi
    - c. microvilli
    - d. length of the small intestine
    - e. all of the above
  2. Given these parts of the small intestine:
    - a. duodenum
    - b. ileum
    - c. jejunum
  3. Choose the arrangement that lists the parts in the order food encounters them as it passes from the stomach through the small intestine.
    - a. 1,2,3
    - b. 1,3,2
    - c. 2,1,3
    - d. 2,3,1
    - e. 3,1,2
  4. Which cells in the small intestine have digestive enzymes attached to their surfaces?
    - a. mucous cells
    - b. goblet cells
    - c. endocrine cells
    - d. absorptive cells

## **UNIT 3 ANATOMY OF THE LARGE INTESTINE**

### **CONTENT**

- 1.0 Introduction
- 2.0 Objectives
- 3.0 Main Content
  - 3.1 Gross anatomy of the large intestine
  - 3.2 Structure of the large intestine
  - 3.3 Vasculature and nerve supply of the large intestine
- 4.0 Conclusion
- 5.0 Summary
- 6.0 Tutor Marked Assignments
- 7.0 References and other resources

### **1.0 INTRODUCTION**

The large intestine is the portion of the digestive tract extending from the ileocecal junction to the anus. It consists of the cecum, colon, rectum, and anal canal. While in the colon, chyme is converted to feces. The absorption of water and salts, secretion of mucus, and extensive action of microorganisms are involved in the formation of feces, which the colon stores until the feces are eliminated by the process of defecation.

### **2.0 OBJECTIVES**

At the end of this unit, you should be able to;

- Identify the regions of the large intestine and describe its gross and histological structure.
- Describe the functions of the large intestine and explain how defecation is accomplished.

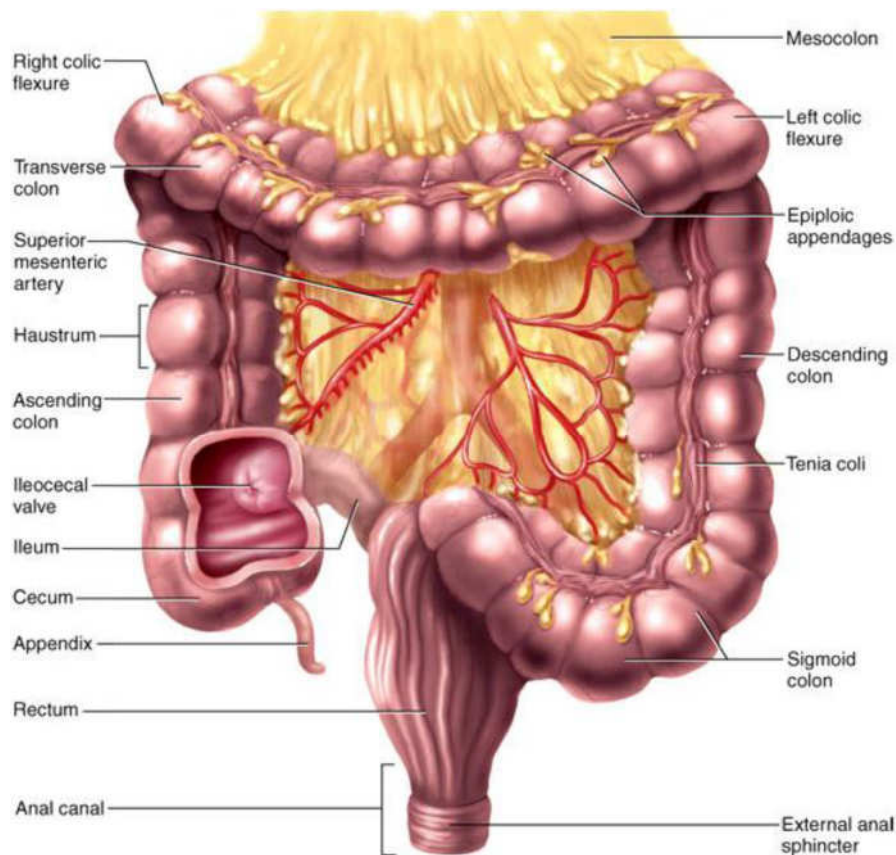
### **3.0 MAIN CONTENT**

#### **3.1 Gross anatomy of the large intestine**

The large intestine extends from the end of the ileum to the anus. It is about 1.5 meters long, being one-fifth of the whole extent of the intestinal canal. Its caliber is largest at its commencement at the cecum, and gradually diminishes as far as the rectum, where there is a dilatation of considerable size just above the anal canal. It differs from the small intestine in its greater caliber, its more fixed position, its sacculated

form, and in possessing certain appendages to its external coat, the appendices epiploicæ.

Further, its longitudinal muscular fibers do not form a continuous layer around the gut, but are arranged in three longitudinal bands or tæniæ. The large intestine, in its course, describes an arch which surrounds the convolutions of the small intestine. It commences in the right iliac region, in a dilated part, the cecum. It ascends through the right lumbar and hypochondriac regions to the under surface of the liver; it here takes a bend, the right colic flexure, to the left and passes transversely across the abdomen on the confines of the epigastric and umbilical regions, to the left hypochondriac region; it then bends again, the left colic flexure, and descends through the left lumbar and iliac regions to the pelvis, where it forms a bend called the sigmoid flexure; from this it is continued along the posterior wall of the pelvis to the anus.



**Fig. 3.1:**

The large intestine is divided into the **cecum, colon, rectum, and anal canal.**

### **The Cecum**

The commencement of the large intestine is the large blindpouch situated below the colic valve. Its blind end is directed downward, and its open end upward, communicating directly with the colon, of which this blind pouch appears to be the beginning or head, and hence the old name of *caput cæcum coli* was applied to it. Its size is variously estimated by different authors, but on an average it may be said to be 6.25 cm. in length and 7.5 in breadth. It is situated in the right iliac fossa, above the lateral half of the inguinal ligament: it rests on the Iliacus and Psoas major, and usually lies in contact with the anterior abdominal wall, but the greater omentum and, if the cecum be empty, some coils of small intestine may lie in front of it.

As a rule, *it is entirely enveloped by peritoneum*, but at times the peritoneal covering is not complete, so that the upper part of the posterior surface is uncovered and connected to the iliac fascia by connective tissue.

The cecum lies quite free in the abdominal cavity and enjoys a considerable amount of movement, so that it may become herniated down the right inguinal canal, and has occasionally been found in an inguinal hernia on the left side, the cecum varies in shape.

### **The Vermiform Process or Appendix**

This is a long, narrow, worm-shaped tube, which starts from what was originally the apex of the cecum, and may pass in one of several directions:

- *upward behind the cecum;*
- *to the left behind the ileum and mesentery;*
- *downward into the lesser pelvis.*

It varies from 2 to 20 cm. in length, its average being about 8.3 cm. It is retained in position by a fold of peritoneum (mesenteriole), derived from the left leaf of the mesentery. This fold, in the majority of cases, is more or less triangular in shape, and as a rule extends along the entire length of the tube. Between its two layers and close to its free margin lies the appendicular artery.

The canal of the vermiform process is small, extends throughout the whole length of the tube, and communicates with the cecum by an orifice which is placed below and behind the ileocecal opening. It is sometimes guarded by a semilunar valve formed by a fold of mucous membrane, but this is by no means constant.

### **The Colic Valve** (*valvula coli; ileocecal valve*)

The lower end of the ileum ends by opening into the medial and back part of the large intestine, at the point of junction of the cecum with the colon. The opening is guarded by a valve, consisting of two segments or lips, which project into the lumen of the large intestine. If the intestine has been inflated and dried, the lips are of a semilunar shape.

The upper one, nearly horizontal in direction, is attached by its convex border to the line of junction of the ileum with the colon; the lower lip, which is longer and more concave, is attached to the line of junction of the ileum with the cecum. At the ends of the aperture the two segments of the valve coalesce, and are continued as narrow membranous ridges around the canal for a short distance, forming the frenula of the valve.

The left or anterior end of the aperture is rounded; the right or posterior is narrow and pointed. In the fresh condition, or in specimens which have been hardened *in situ*, the lips project as thick cushion-like folds into the lumen of the large gut, while the opening between them may present the appearance of a slit or may be somewhat oval in shape.

Each lip of the valve is formed by a reduplication of the mucous membrane and of the circular muscular fibers of the intestine, the longitudinal fibers and peritoneum being continued uninterruptedly from the small to the large intestine. The surfaces of the valve directed toward the ileum are covered with villi, and present the characteristic structure of the mucous membrane of the small intestine; while those turned toward the large intestine are destitute of villi, and marked with the orifices of the numerous tubular glands peculiar to the mucous membrane of the large intestine. These differences in structure continue as far as the free margins of the valve.

It is generally maintained that this valve prevents reflux from the cecum into the ileum, but in all probability it acts as a sphincter around the end of the ileum and prevents the contents of the ileum from passing too quickly into the cecum.

## The Colon

This is divided into four parts: *the ascending, transverse, descending, and sigmoid.*

### The Ascending Colon (*colon ascendens*)

This is smaller in caliber than the cecum, with which it is continuous. It passes upward, from its commencement at the cecum, opposite the colic valve, to the under surface of the right lobe of the liver, on the right of the gall-bladder, where it is lodged in a shallow depression, the colic impression; here it bends abruptly forward and to the left, forming the right colic (*hepatic*) flexure. It is retained in contact with the posterior wall of the abdomen by the peritoneum, which covers its anterior surface and sides, its posterior surface being connected by loose areolar tissue with the Iliacus, Quadratus lumborum, aponeurotic origin of Transversus abdominis, and with the front of the lower and lateral part of the right kidney. Sometimes the peritoneum completely invests it, and forms a distinct but narrow mesocolon. It is in relation, in front, with the convolutions of the ileum and the abdominal parietes.

### The Transverse Colon (*colon transversum*)

The longest and most movable part of the colon, passes with a downward convexity from the right hypochondriac region across the abdomen, opposite the confines of the epigastric and umbilical zones, into the left hypochondriac region, where it curves sharply on itself beneath the lower end of the spleen, forming the left colic (*splenic*) flexure.

In its course it describes an arch, the concavity of which is directed backward and a little upward; toward its splenic end there is often an abrupt U-shaped curve which may descend lower than the main curve. It is almost completely invested by peritoneum, and is connected to the inferior border of the pancreas by a large and wide duplicature of that membrane, the transverse mesocolon. It is in relation, by its upper surface, with the liver and gall-bladder, the greater curvature of the stomach, and the lower end of the spleen; by its under surface, with the small intestine; by its anterior surface, with the anterior layers of the greater omentum and the abdominal parietes; its posterior surface is in relation from right to left with the descending portion of the duodenum, the head of the pancreas, and some of the convolutions of the jejunum and ileum.

*The left colic or splenic flexure* is situated at the junction of the transverse and descending parts of the colon, and is in relation with the

lower end of the spleen and the tail of the pancreas; the flexure is so acute that the end of the transverse colon usually lies in contact with the front of the descending colon. It lies at a higher level than, and on a plane posterior to, the right colic flexure, and is attached to the diaphragm, opposite the tenth and eleventh ribs, by a peritoneal fold, named the phrenicocolic ligament, which assists in supporting the lower end of the spleen, Iliac colon, sigmoid or pelvic colon, and rectum seen from the front, after removal of pubic bones and bladder.

### **The Descending Colon** (*colon descendens*)

It passes downward through the left hypochondriac and lumbar regions along the lateral border of the left kidney. At the lower end of the kidney it turns medialward toward the lateral border of the Psoas, and then descends, in the angle between Psoas and Quadratus lumborum, to the crest of the ilium, where it ends in the iliac colon. The peritoneum covers its anterior surface and sides, while its posterior surface is connected by areolar tissue with the lower and lateral part of the left kidney, the aponeurotic origin of the Transversus abdominis, and the Quadratus lumborum. It is smaller in caliber and more deeply placed than the ascending colon, and is more frequently covered with peritoneum on its posterior surface than the ascending colon. In front of it are some coils of small intestine.

### **The Iliac Colon**

This is situated in the left iliac fossa, and is about 12 to 15 cm. long. It begins at the level of the iliac crest, where it is continuous with the descending colon, and ends in the sigmoid colon at the superior aperture of the lesser pelvis. It curves downward and medialward in front of the Iliacus and Psoas, and, as a rule, *is covered by peritoneum on its sides and anterior surface only.*

### **The Sigmoid Colon** (*colon sigmoideum; pelvic colon; sigmoid flexure*)

This forms a loop which averages about 40 cm. in length, and normally lies within the pelvis, but on account of its freedom of movement it is liable to be displaced into the abdominal cavity. It begins at the superior aperture of the lesser pelvis, where it is continuous with the iliac colon, and passes transversely across the front of the sacrum to the right side of the pelvis; it then curves on itself and turns toward the left to reach the middle line at the level of the third piece of the sacrum, where it bends downward and ends in the rectum.

It is completely surrounded by peritoneum, which forms a mesentery (sigmoid mesocolon), which diminishes in length from the center toward the ends of the loop, where it disappears, so that the loop is fixed at its

junctions with the iliac colon and rectum, but enjoys a considerable range of movement in its central portion.

*Behind* the sigmoid colon are the external iliac vessels, the left Piriformis, and left sacral plexus of nerves; *in front*, it is separated from the bladder in the male, and the uterus in the female, by some coils of the small intestine.

### **The Rectum** (*intestinum rectum*)

This is continuous above with the sigmoid colon, while below it ends in the anal canal. From its origin at the level of the third sacral vertebra it passes downward, lying in the sacrococcygeal curve, and extends for about 2.5 cm. in front of, and a little below, the tip of the coccyx, as far as the apex of the prostate. It then bends sharply backward into the anal canal. It therefore presents two antero-posterior curves: an upper, with its convexity backward, and a lower, with its convexity forward. Two lateral curves are also described, one to the right opposite the junction of the third and fourth sacral vertebræ, and the other to the left, opposite the left sacrococcygeal articulation; they are, however, of little importance. The rectum is about 12 cm. long, and at its commencement its caliber is similar to that of the sigmoid colon, but near its termination it is dilated to form the rectal ampulla.

The rectum has no sacculations comparable to those of the colon, but when the lower part of the rectum is contracted, its mucous membrane is thrown into a number of folds, which are longitudinal in direction and are effaced by the distension of the gut. Besides these there are certain permanent transverse folds, of a semilunar shape, known as *Houston's valves*.

**Houston valves** are usually three in number; sometimes a fourth is found, and occasionally only two are present. One is situated near the commencement of the rectum, on the right side; a second extends inward from the left side of the tube, opposite the middle of the sacrum; a third, the largest and most constant, projects backward from the forepart of the rectum, opposite the fundus of the urinary bladder. When a fourth is present, it is situated nearly 2.5 cm. above the anus on the left and posterior wall of the tube. These folds are about 12 mm. in width, and contain some of the circular fibers of the gut.

In the empty state of the intestine they overlap each other, as *Houston remarks*, so effectually as to require considerable maneuvering to conduct a bougie or the finger along the canal. Their use seems to be, —to support the weight of fecal matter, and prevent its urging toward



the anus, where its presence always excites a sensation demanding its discharge.

The peritoneum is related to the upper two-thirds of the rectum, covering at first its front and sides, but lower down its front only; from the latter it is reflected on to the seminal vesicles in the male and the posterior vaginal wall in the female

The level at which the peritoneum leaves the anterior wall of the rectum to be reflected on to the viscus in front of it is of considerable importance from a surgical point of view, in connection with the removal of the lower part of the rectum. It is higher in the male than in the female. In the former the height of the rectovesical excavation is about 7.5 cm., *i. e.*, the height to which an ordinary index finger can reach from the anus. In the female the height of the rectouterine excavation is about 5.5 cm. from the anal orifice.

The rectum is surrounded by a dense tube of fascia derived from the fascia endopelvina, but fused behind with the fascia covering the sacrum and coccyx. The fascial tube is loosely attached to the rectal wall by areolar tissue in order to allow of distension of the viscus.

### **Relations of the Rectum**

The upper part of the rectum is in relation, *behind*, with the superior hemorrhoidal vessels, the left Piriformis, and left sacral plexus of nerves, which separate it from the pelvic surfaces of the sacral vertebræ; in its lower part it lies directly on the sacrum, coccyx, and Levatores ani, a dense fascia alone intervening; *in front*, it is separated above, in the male, from the fundus of the bladder; in the female, from the intestinal surface of the uterus and its appendages, by some convolutions of the small intestine, and frequently by the sigmoid colon; *below*, it is in relation in the male with the triangular portion of the fundus of the bladder, the vesiculæ seminales, and ductus deferentes, and more anteriorly with the posterior surface of the prostate; in the female, with the posterior wall of the vagina.

**The Anal Canal** (*pars analis recti*), or terminal portion of the large intestine, begins at the level of the apex of the prostate, is directed downward and backward, and ends at the anus. It forms an angle with the lower part of the rectum, and measures from 2.5 to 4 cm. in length. It has no peritoneal covering, but is invested by the Sphincter ani internus, supported by the Levator ani, and surrounded at its termination by the Sphincter ani externus.

In the empty condition it presents the appearance of an antero-posterior longitudinal slit. Behind it is a mass of muscular and fibrous tissue, the anococcygeal body; in front of it, in the male, but separated by connective tissue from it, are the membranous portion and bulb of the urethra, and the fascia of the urogenital diaphragm; and in the female it is separated from the lower end of the vagina by a mass of muscular and fibrous tissue, named the *perineal body*.

The lumen of the anal canal presents, in its upper half, a number of vertical folds, produced by an infolding of the mucous membrane and some of the muscular tissue. They are known as the rectal columns [*Morgagni*] and are separated from one another by furrows (rectal sinuses), which end below in small valve-like folds, termed anal valves, which join together the lower ends of the rectal columns.

### 3.2 Structure of the large intestine

#### The vermiform process

The coats of the vermiform process are the same as those of the intestine: serous, muscular, submucous, and mucous. The serous coat forms a complete investment for the tube, except along the narrow line of attachment of its mesenteriole in its proximal two-thirds.

The *longitudinal muscular fibers* do not form three bands as in the greater part of the large intestine, but invest the whole organ, except at one or two points where both the longitudinal and circular fibers are deficient so that the peritoneal and submucous coats are contiguous over small areas.

The *circular muscle fibers* form a much thicker layer than the longitudinal fibers, and are separated from them by a small amount of connective tissue. The submucous coat is well marked, and contains a large number of masses of lymphoid tissue which cause the mucous membrane to bulge into the lumen and so render the latter of small size and irregular shape. The mucous membrane is lined by columnar epithelium and resembles that of the rest of the large intestine, but the intestinal glands are fewer in number.

**Structure of the Colon;** the large intestine has four coats: serous, muscular, areolar, and mucous.

*The serous coat (tunica serosa)* is derived from the peritoneum, and invests the different portions of the large intestine to a variable extent. The cecum is completely covered by the serous membrane, except in about 5 per cent of cases where the upper part of the posterior surface is

uncovered. The ascending, descending, and iliac parts of the colon are usually covered only in front and at the sides; a variable amount of the posterior surface is uncovered. The transverse colon is almost completely invested, the parts corresponding to the attachment of the greater omentum and transverse mesocolon being alone excepted.

The sigmoid colon is entirely surrounded. The rectum is covered above on its anterior surface and sides; below, on its anterior aspect only; the anal canal is entirely devoid of any serous covering. In the course of the colon the peritoneal coat is thrown into a number of small pouches filled with fat, called *appendicesepiploicæ*. They are most numerous on the transverse colon.

**The muscular coat** (*tunica muscularis*) consists of an external longitudinal, and an internal circular, layer of non-striped muscular fibers: The *longitudinal fibers* do not form a continuous layer over the whole surface of the large intestine. In the cecum and colon they are especially collected into three flat longitudinal bands (*tænæi coli*), each of about 12 mm. in width; one, the posterior, is placed along the attached border of the intestine; the anterior, the largest, corresponds along the arch of the colon to the attachment of the greater omentum, but is in front in the ascending, descending, and iliac parts of the colon, and in the sigmoid colon; the third, or lateral band, is found on the medial side of the ascending and descending parts of the colon, and on the under aspect of the transverse colon.

These bands are shorter than the other coats of the intestine, and serve to produce the sacculi which are characteristic of the cecum and colon; accordingly, when they are dissected off, the tube can be lengthened, and its sacculated character disappears. In the sigmoid colon the longitudinal fibers become more scattered; and around the rectum they spread out and form a layer, which completely encircles this portion of the gut, but is thicker on the anterior and posterior surfaces, where it forms two bands, than on the lateral surfaces. In addition, two bands of plain muscular tissue arise from the second and third coccygeal vertebræ, and pass downward and forward to blend with the longitudinal muscular fibers on the posterior wall of the anal canal. These are known as the Rectococcygealmuscles. The blood vessels of the rectum and anus, showing the distribution and anastomosis on the posterior surface near the termination of the gut.

The *circular fibers* form a thin layer over the cecum and colon, being especially accumulated in the intervals between the sacculi; in the rectum they form a thick layer, and in the anal canal they become numerous, and constitute the Sphincter aniinternus.

**The areolar coat** (*tela submucosa; submucous coat*) connects the muscular and mucous layers closely together. The mucous membrane (*tunica mucosa*) in the cecum and colon, is pale, smooth, destitute of villi, and raised into numerous crescentic folds which correspond to the intervals between the sacculi. In the rectum it is thicker, of a darker color, more vascular, and connected loosely to the muscular coat, as in the esophagus.

The **mucous membrane** consists of a muscular layer, the muscularismucosæ; a quantity of retiform tissue in which the vessels ramify; a basement membrane and epithelium which is of the columnar variety, and resembles the epithelium found in the small intestine.

### 3.3 Vasculature and nerve supply of the large intestine

**The arteries** supplying the colon are derived from the colic and sigmoid branches of the *mesenteric arteries*. They give off large branches, which ramify between and supply the muscular coats, and after dividing into small vessels in the submucous tissue, pass to the mucous membrane.

The rectum is supplied by the *superior hemorrhoidal branch* of the inferior mesenteric, and the anal canal by the *middle hemorrhoidal* from the hypogastric, and the *inferior hemorrhoidal* from the internal pudendal artery. The superior hemorrhoidal, the continuation of the inferior mesenteric, divides into two branches, which run down either side of the rectum to within about 12.5 cm. of the anus; they here split up into about six branches which pierce the muscular coat and descend between it and the mucous membrane in a longitudinal direction, parallel with each other as far as the Sphincter ani internus, where they anastomose with the other hemorrhoidal arteries and form a series of loops around the anus.

**The veins** of the rectum commence in a plexus of vessels which surrounds the anal canal. In the vessels forming this plexus are smaller saccular dilatations just within the margin of the anus; from the plexus about six vessels of considerable size are given off. These ascend between the muscular and mucous coats for about 12.5 cm., running parallel to each other; they then pierce the muscular coat, and, by their union, form a single trunk, the superior hemorrhoidal vein. This arrangement is termed the hemorrhoidal plexus; it communicates with the tributaries of the middle and inferior hemorrhoidal veins, at its commencement, and thus a communication is established between the systemic and portal circulations.

**The nerves** are derived from the sympathetic plexuses around the branches of the superior and inferior mesenteric arteries. They are distributed in a similar way to those found in the small intestine.

## 5.0 SUMMARY

In this unit, you have learnt about the following:

- i. Gross anatomy of the large intestine
- ii. Structure of the large intestine
- iii. Asculature and nerve supply of the large intestine

### 3.3.5 Clinical correlates

**Congenital Hernia.**—There are some varieties of oblique inguinal hernia depending upon congenital defects in the saccus vaginalis, the pouch of peritoneum which precedes the descent of the testis. Normally this pouch is closed before birth, closure commencing at two points, viz., at the abdominal inguinal ring and at the top of the epididymis, and gradually extending until the whole of the intervening portion is converted into a fibrous cord. From failure in the completion of this process, variations in the relation of the hernial protrusion to the testis and tunica vaginalis are produced; these constitute distinct varieties of inguinal hernia, viz., the hernia of the funicular process and the complete congenital variety.

Where the processus vaginalis is occluded at the lower point only, *i.e.*, just above the testis, the intestine descends into the pouch of peritoneum as far as the testis, but is prevented from entering the sac of the tunica vaginalis by the septum which has formed between it and the pouch. This is known as *hernia into the funicular process* or *incomplete congenital hernia*; it differs from the former in that instead of enveloping the testis it lies above it.

## 6.0 TUTOR MARKED ASSIGNMENTS

### 6.1 Activity

- i. Identify the four principal regions of the large intestine and describe the functions of the colon.

### 6.2 Please answer the following questions:

- i. Describe the haustra and the taeniae coli and explain their role in the movements of the large intestine.

- ii. Discuss the structure of the rectum, anal canal, and anal sphincter muscles.
- iii. Distinguish complete congenital hernia from incomplete congenital hernia

## **7.0 REFERENCES AND OTHER RESOURCES**

Hutchinson, M., Mallat, J., Marieb, E.N., Wilhelm P.B. (2007). *A Brief Atlas of the Human Body*. San Francisco: Pearson Education Inc.

Katherine M. A. Rogers and William N. Scott (2011) *Nurses! Test Yourself in Anatomy and Physiology*

Kathryn A. Booth, Terri. D. Wyman (2008) *Anatomy, Physiology, and Pathophysiology for Allied Health*

Keith L Moore, Persuade T.V.N (2018), *The Developing Human Clinically Oriented Embryology 11th Edition* Lippincott Williams & Wilkins

Kent M. Van De Graff, R.Ward Rhees, Sidney Palmer (2010) *Schaum's Outline of human Anatomy and Physiology 3rd edition*.

Philip Tate (2012) *Seeley's Principles of Anatomy & Physiology 2nd ed.*

Sadler T.W (2012), *Langman's Medical Embryology 12th edition*.

*Seeley's Principles of Anatomy & Physiology, Second edition*  
Published by McGraw-Hill, a business unit of The McGraw-Hill Companies, Inc., 1221 Avenue of the Americas, New York, NY 10020. Copyright c 2012- Chapter 17&18

## **UNIT 4    OTHER ACCESSORY ORGANS OF DIGESTION**

### **CONTENT**

- 1.0 Introduction
- 2.0 Objectives
- 3.0 Main Content
  - 3.1 Developmental anatomy of the liver
  - 3.2 Gross anatomy of the liver
  - 3.3 Histology of the liver
  - 3.4 Developmental anatomy of the pancreas
  - 3.5 Gross anatomy of the pancreas
  - 3.6 Histology of the pancreas
- 4.0 Conclusion
- 5.0 Summary
- 6.0 Tutor Marked Assignments
- 7.0 References and other resources

### **1.0 INTRODUCTION**

Other accessory organs of digestion are those organs that are crucial to the process of digestion but are not usually categorized as organs of digestion.

They include the liver, the gall bladder and the pancreas.

### **2.0 OBJECTIVES**

At the end of this unit, you should be able to;

- Describe the location, structure, relations, and functions of the liver.
- Draw an annotated diagram of the Liver
- Describe the location of the gallbladder and trace the flow of bile through the systems of ducts into the duodenum.
- Describe the location, structure, and functions of the pancreas.

### **3.0 MAIN CONTENT**

#### **3.1 Developmental anatomy of the liver**

The liver arises in the form of a diverticulum or hollow outgrowth from the ventral surface of that portion of the gut which afterward becomes the descending part of the duodenum .This diverticulum is lined by

entoderm, and grows upward and forward into the septum transversum, a mass of mesoderm between the vitelline duct and the pericardial cavity, and there gives off two solid buds of cells which represent the right and the left lobes of the liver. The solid buds of cells grow into columns or cylinders, termed the hepatic cylinders, which branch and anastomose to form a close meshwork.

This network invades the vitelline and umbilical veins, and breaks up these vessels into a series of capillary-like vessels termed sinusoids (Minot), which ramify in the meshes of the cellular network and ultimately form the venous capillaries of the liver. By the continued growth and ramification of the hepatic cylinders the mass of the liver is gradually formed. The original diverticulum from the duodenum forms the common bile duct, and from this the cystic duct and gall-bladder arise as a solid outgrowth which later acquires a lumen. The opening of the common duct is at first in the ventral wall of the duodenum; later, owing to the rotation of the gut, the opening is carried to the left and then dorsalward to the position it occupies in the adult.

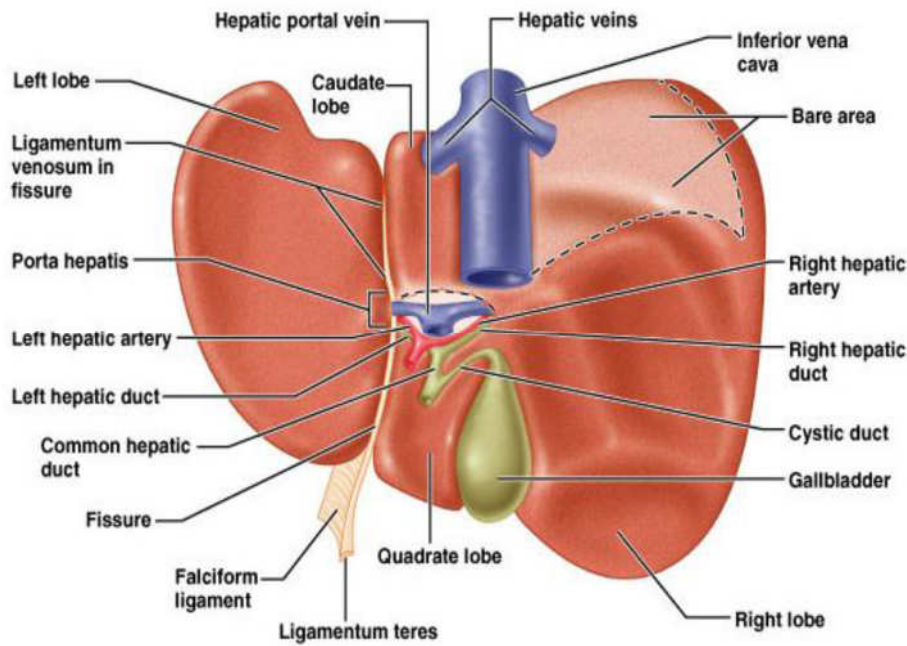
As the liver undergoes enlargement, both it and the ventral mesogastrium of the fore-gut are gradually differentiated from the septum transversum; and from the under surface of the latter the liver projects downward into the abdominal cavity.

By the growth of the liver the ventral mesogastrium is divided into two parts, of which the anterior forms the falciform and coronary ligaments, and the posterior the lesser omentum. About the third month the liver almost fills the abdominal cavity, and its left lobe is nearly as large as its right. From this period the relative development of the liver is less active, more especially that of the left lobe, which actually undergoes some degeneration and becomes smaller than the right; but up to the end of fetal life the liver remains relatively larger than in the adult.

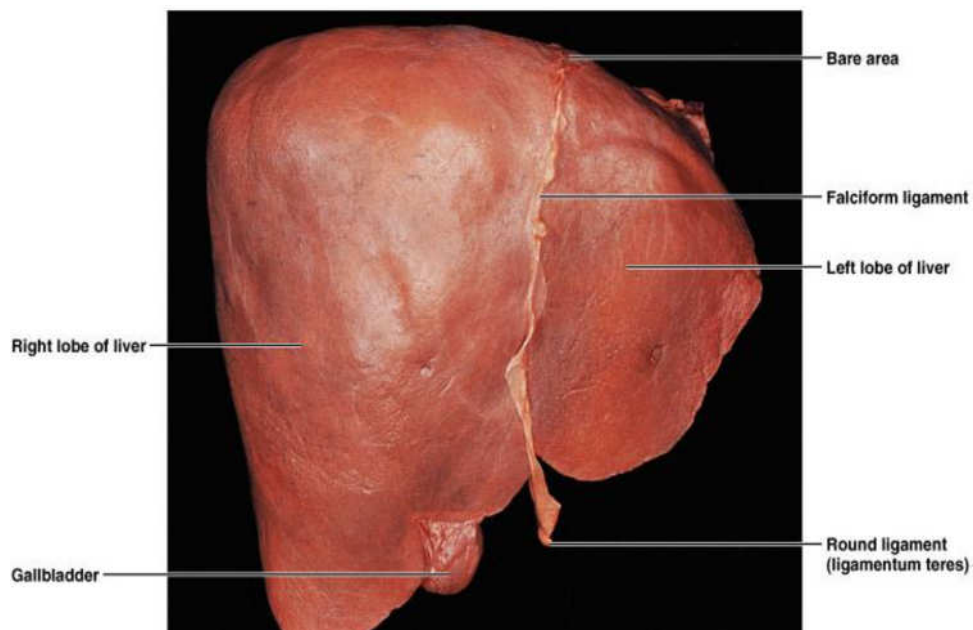
### **3.2 Gross anatomy of the liver**

Liver, the largest gland in the body, has both external and internal secretions, which are formed in the hepatic cells. Its external secretion, the bile, is collected after passing through the bile capillaries by the bile ducts, which join like the twigs to form two large ducts that unite to form the hepatic duct. The bile is either carried to the gall-bladder by the cystic duct or poured directly into the duodenum by the common bile duct where it aids in digestion. The internal secretions are concerned with the metabolism of both nitrogenous and carbohydrate materials absorbed from the intestine and carried to the liver by the portal vein.





**Fig. 4.1:**



**Fig. 4.2:** Structure of the liver

The carbohydrates are stored in the hepatic cells in the form of glycogen which is secreted in the form of sugar directly into the blood stream. Some of the cells lining the blood capillaries of the liver are concerned in the destruction of red blood corpuscles.

It is situated in the upper and right parts of the abdominal cavity, occupying almost the whole of the right hypochondrium, the greater part of the epigastrium, and not uncommonly extending into the left

hypochondrium as far as the mammillary line. In the male it weighs from 1.4 to 1.6 kilogram., in the female from 1.2 to 1.4 kilogram.

It is relatively much larger in the fetus than in the adult, constituting, in the former, about one-eighteenth, and in the latter about one thirty-sixth of the entire body weight. Its greatest transverse measurement is from 20 to 22.5 cm. Vertically, near its lateral or right surface, it measures about 15 to 17.5 cm., while its greatest antero-posterior diameter is on a level with the upper end of the right kidney, and is from 10 to 12.5 cm. Opposite the vertebral column its measurement from before backward is reduced to about 7.5 cm.

Its consistence is that of a soft solid; it is friable, easily lacerated and highly vascular; its color is a dark reddish brown, and its specific gravity is 1.05.

### Surfaces

The liver possesses three surfaces, viz, *superior, inferior and posterior*. A sharp, well-defined margin divides the inferior from the superior in front; the other margins are rounded. The superior surface is attached to the diaphragm and anterior abdominal wall by a triangular or falciform fold of peritoneum, the falciform ligament, in the free margin of which is a rounded cord, the ligamentum teres (*obliterated umbilical vein*). The line of attachment of the falciform ligament divides the liver into two parts, termed the right and left lobes, the right being much the larger. The inferior and posterior surfaces are divided into four lobes by five fossæ, which are arranged in the form of the letter H.

The left limb of the H marks on these surfaces the division of the liver into right and left lobes; it is known as the left sagittal fossa, and consists of two parts, viz., the fossa for the umbilical vein in front and the fossa for the ductus venosus behind. The right limb of the H is formed in front by the fossa for the gall-bladder, and behind by the fossa for the inferior vena cava; these two fossæ are separated from one another by a band of liver substance, termed the caudate process. The bar connecting the two limbs of the H is the porta (*transverse fissure*); in front of it is the quadrate lobe, behind it the caudate lobe.

**The superior surface** (*facies superior*) comprises a part of both lobes, and, as a whole, is convex, and fits under the vault of the diaphragm which in front separates it on the right from the sixth to the tenth ribs and their cartilages, and on the left from the seventh and eighth costal cartilages. Its middle part lies behind the xiphoid process, and, in the angle between the diverging ribs cartilage of opposite sides, is in contact

with the abdominal wall. Behind this the diaphragm separates the liver from the lower part of the lungs and pleura, the heart and pericardium and the right costal arches from the seventh to the eleventh inclusive. It is completely covered by peritoneum except along the line of attachment of the falciform ligament.

**The inferior surface** (*facies inferior; visceral surface*), is uneven, concave, directed downward, backward, and to the left, and is in relation with the stomach and duodenum, the right colic flexure, and the right kidney and suprarenal gland. The surface is almost completely invested by peritoneum; the only parts devoid of this covering are where the gall-bladder is attached to the liver, and at the porta hepatis where the two layers of the lesser omentum are separated from each other by the blood vessels and ducts of the liver. The inferior surface of the left lobe presents behind and to the left the gastric impression, moulded over the antero-superior surface of the stomach, and to the right of this a rounded eminence, the tuber omentale, which fits into the concavity of the lesser curvature of the stomach and lies in front of the anterior layer of the lesser omentum. The under surface of the right lobe is divided into two unequal portions by the fossa for the gall-bladder; the portion to the left, the smaller of the two, is the quadrate lobe, and is in relation with the pyloric end of the stomach, the superior portion of the duodenum, and the transverse colon.

The portion of the under surface of the right lobe to the right of the fossa for the gall-bladder presents two impressions, one situated behind the other, and separated by a ridge. The anterior of these two impressions, the colic impression, is shallow and is produced by the right colic flexure; the posterior, the renal impression, is deeper and is occupied by the upper part of the right kidney and lower part of the right suprarenal gland. Medial to the renal impression is a third and slightly marked impression, lying between it and the neck of the gall-bladder.

This is caused by the descending portion of the duodenum, and is known as the duodenal impression. Just in front of the inferior vena cava is a narrow strip of liver tissue, the caudate process, which connects the right inferior angle of the caudate lobe to the under surface of the right lobe. It forms the upper boundary of the epiploic foramen of the peritoneum.

**The posterior surface** (*facies posterior*) is rounded and broad behind the right lobe, but narrow on the left. Over a large part of its extent it is not covered by peritoneum; this uncovered portion is about 7.5 cm. broad at its widest part, and is in direct contact with the diaphragm. It is marked off from the upper surface by the line of reflection of the upper layer of the coronary ligament, and from the under surface by the line of reflection of the lower layer of the coronary ligament. The central part of the posterior surface presents a deep concavity which is moulded on

the vertebral column and crura of the diaphragm. To the right of this the inferior vena cava is lodged in its fossa between the uncovered area and the caudate lobe. Close to the right of this fossa and immediately above the renal impression is a small triangular depressed area, the suprarenal impression, the greater part of which is devoid of peritoneum; it lodges the right suprarenal gland.

To the left of the inferior vena cava is the caudate lobe, which lies between the fossa for the vena cava and the fossa for the ductus venosus. Its lower end projects and forms part of the posterior boundary of the porta; on the right, it is connected with the under surface of the right lobe of the liver by the caudate process, and on the left it presents an elevation, the papillary process. Its posterior surface rests upon the diaphragm, being separated from it merely by the upper part of the omental bursa.

To the left of the fossa for the ductus venosus is a groove in which lies the antrum cardiacum of the esophagus. The anterior border (*margo anterior*) is thin and sharp, and marked opposite the attachment of the falciform ligament by a deep notch, the umbilical notch, and opposite the cartilage of the ninth rib by a second notch for the fundus of the gall-bladder. In adult males this border generally corresponds with the lower margin of the thorax in the right mammillary line; but in women and children it usually projects below the ribs. The left extremity of the liver is thin and flattened from above downward.

### **Fossæ**

*The left sagittal fossa* (*fossa sagittalissinistra; longitudinal fissure*) is a deep groove, which extends from the notch on the anterior margin of the liver to the upper border of the posterior surface of the organ; it separates the right and left lobes. The porta joins it, at right angles, and divides it into two parts.

The anterior part, or fossa for the umbilical vein, lodges the umbilical vein in the fetus, and its remains (the ligamentum teres) in the adult; it lies between the quadrate lobe and the left lobe of the liver, and is often partially bridged over by a prolongation of the hepatic substance, the pons hepatis. The posterior part, or fossa for the ductus venosus, lies between the left lobe and the caudate lobe; it lodges in the fetus, the ductus venosus, and in the adult a slender fibrous cord, the ligamentum venosum, the obliterated remains of that vessel.

*The porta or transverse fissure* (*porta hepatis*) is a short but deep fissure, about 5 cm. long, extending transversely across the under surface of the left portion of the right lobe, nearer its posterior surface

than its anterior border. It joins nearly at right angles with the left sagittal fossa, and separates the quadrate lobe in front from the caudate lobe and process behind. It transmits the portal vein, the hepatic artery and nerves, and the hepatic duct and lymphatics. The hepatic duct lies in front and to the right, the hepatic artery to the left, and the portal vein behind and between the duct and artery.

**The fossa for the gall-bladder** (*fossa vesicæfelleæ*) is a shallow, oblong fossa, placed on the under surface of the right lobe, parallel with the left sagittal fossa. It extends from the anterior free margin of the liver, which is notched by it, to the right extremity of the porta.

**The fossa for the inferior vena cava** (*fossa venæcavæ*) is a short deep depression, occasionally a complete canal in consequence of the substance of the liver surrounding the vena cava. It extends obliquely upward on the posterior surface between the caudate lobe and the bare area of the liver, and is separated from the porta by the caudate process. On slitting open the inferior vena cava the orifices of the hepatic veins will be seen opening into this vessel at its upper part, after perforating the floor of this fossa.

## Lobes

**The right lobe** (*lobushepatisdexter*) is much larger than the left; the proportion between them being as six to one. It occupies the right hypochondrium, and is separated from the left lobe on its upper surface by the falciform ligament; on its under and posterior surfaces by the left sagittal fossa; and in front by the umbilical notch. It is of a somewhat quadrilateral form, its under and posterior surfaces being marked by three fossæ: the porta and the fossæ for the gall-bladder and inferior vena cava, which separate its left part into two smaller lobes; the quadrate and caudate lobes.

**The quadrate lobe** (*lobusquadratus*) is situated on the under surface of the right lobe, bounded in front by the anterior margin of the liver; behind by the porta; on the right, by the fossa for the gall-bladder; and on the left, by the fossa for the umbilical vein. It is oblong in shape, its antero-posterior diameter being greater than its transverse.

**The caudate lobe** (*lobuscaudatus*; *Spigelian lobe*) is situated upon the posterior surface of the right lobe of the liver, opposite the tenth and eleventh thoracic vertebræ. It is bounded, below, by the porta; on the right, by the fossa for the inferior vena cava; and, on the left, by the fossa for the ductus venosus. It looks backward, being nearly vertical in position; it is longer from above downward than from side to side, and is somewhat concave in the transverse direction.

The caudate process is a small elevation of the hepatic substance extending obliquely lateralward, from the lower extremity of the caudate lobe to the under surface of the right lobe. It is situated behind the porta, and separates the fossa for the gall bladder from the commencement of the fossa for the inferior vena cava.

**The left lobe** (*lobus hepatis sinister*) is smaller and more flattened than the right. It is situated in the epigastric and left hypochondriac regions. Its upper surface is slightly convex and is moulded on to the diaphragm; its under surface presents the gastric impression and omental tuberosity, already referred to Ligaments

### Ligaments

The liver is connected to the under surface of the diaphragm and to the anterior wall of the abdomen by five ligaments; four of these—**the falciform, the coronary, and the two lateral**—are peritoneal folds; the fifth, the **round ligament**, is a fibrous cord, the obliterated umbilical vein. The liver is also attached to the lesser curvature of the stomach by the hepatogastric and to the duodenum by the hepatoduodenal ligament .

**The falciform ligament** (*ligamentum falciforme hepatis*) is a broad and thin antero-posterior peritoneal fold, falciform in shape, its base being directed downward and backward, its apex upward and backward. It is situated in an antero-posterior plane, but lies obliquely so that one surface faces forward and is in contact with the peritoneum behind the right Rectus and the diaphragm, while the other is directed backward and is in contact with the left lobe of the liver. It is attached by its left margin to the under surface of the diaphragm, and the posterior surface of the sheath of the right Rectus as low down as the umbilicus; by its right margin it extends from the notch on the anterior margin of the liver, as far back as the posterior surface. It is composed of two layers of peritoneum closely united together. Its base or free edge contains between its layers the round ligament and the parumbilical veins.

**The coronary ligament** (*ligamentum coronarium hepatis*) consists of an upper and a lower layer. The *upper layer* is formed by the reflection of the peritoneum from the upper margin of the bare area of the liver to the under surface of the diaphragm, and is continuous with the right layer of the falciform ligament. The *lower layer* is reflected from the lower margin of the bare area on to the right kidney and suprarenal gland, and is termed the hepatorenal ligament.

**The triangular ligaments** (*lateral ligaments*) are two in number, right and left.

- **The right triangular ligament** (*ligamentum triangulare dextrum*) is situated at the right extremity of the bare area, and is a small fold which passes to the diaphragm, being formed by the apposition of the upper and lower layers of the coronary ligament.
- **The left triangular ligament** (*ligamentum triangulare sinistrum*) is a fold of some considerable size, which connects the posterior part of the upper surface of the left lobe to the diaphragm; its anterior layer is continuous with the left layer of the falciform ligament.

**The round ligament** (*ligamentum teres hepatis*) is a fibrous cord resulting from the obliteration of the umbilical vein. It ascends from the umbilicus, in the free margin of the falciform ligament, to the umbilical notch of the liver, from which it may be traced in its proper fossa on the inferior surface of the liver to the porta, where it becomes continuous with the *ligamentum venosum*.

### Fixation of the Liver

Several factors contribute to maintain the liver in place. The attachments of the liver to the diaphragm by the coronary and triangular ligaments and the intervening connective tissue of the uncovered area, together with the intimate connection of the inferior vena cava by the connective tissue and hepatic veins would hold up the posterior part of the liver. Some support is derived from the pressure of the abdominal viscera which completely fill the abdomen whose muscular walls are always in a state of tonic contraction.

The superior surface of the liver is perfectly fitted to the under surface of the diaphragm so that atmospheric pressure alone would be enough to hold it against the diaphragm. The latter in turn is held up by the negative pressure in the thorax. The lax falciform ligament certainly gives no support though it probably limits lateral displacement.

### Vessels and Nerves

The vessels connected with the liver are: *the hepatic artery, the portal vein, and the hepatic veins*.

The hepatic artery and portal vein, accompanied by numerous nerves, ascend to the porta, between the layers of the lesser omentum.

The *bile duct* and the lymphatic vessels descend from the porta between the layers of the same omentum. The relative positions of the three structures are as follows: the bile duct lies to the right, the hepatic artery

to the left, and the portal vein behind and between the other two. They are enveloped in a loose areolar tissue, the fibrous ***capsule of Glisson***, which accompanies the vessels in their course through the portal canals in the interior of the organ.

They have very little cellular investment, and what there is binds their parietes closely to the walls of the canals through which they run; so that, on section of the organ, they remain widely open and are solitary, and may be easily distinguished from the branches of the portal vein, which are more or less collapsed, and always accompanied by an artery and duct. The nerves of the liver, derived from the ***left vagus and sympathetic***, enter at the porta and accompany the vessels and ducts to the interlobular spaces.

### 3.3 Histology of the liver

The substance of the liver is composed of lobules, held together by an extremely fine areolar tissue, in which ramify the portal vein, hepatic ducts, hepatic artery, hepatic veins, lymphatics, and nerves; the whole being invested by a serous and a fibrous coat.

- **The serous coat** (*tunica serosa*) is derived from the peritoneum, and invests the greater part of the surface of the organ. It is intimately adherent to the fibrous coat.
- **The fibrous coat** (*capsula fibrosa*[*Glissoni*]; *areolar coat*) lies beneath the serous investment, and covers the entire surface of the organ. It is difficult of demonstration, excepting where the serous coat is deficient. At the porta it is continuous with the fibrous capsule of Glisson, and on the surface of the organ with the areolar tissue separating the lobules.

**The lobules** (*lobuli hepatis*) form the chief mass of the hepatic substance; they may be seen either on the surface of the organ, or by making a section through the gland, as small granular bodies, about the size of a millet-seed, measuring from 1 to 2.5 mm. in diameter. In the human subject their outlines are very irregular; but in some of the lower animals (for example, the pig) they are well-defined, and, when divided transversely, have polygonal outlines. The bases of the lobules are clustered around the smallest radicles (*sublobular*) of the hepatic veins, to which each is connected by means of a small branch which issues from the center of the lobule (*intra-lobular*). The remaining part of the surface of each lobule is imperfectly isolated from the surrounding lobules by a thin stratum of areolar tissue, in which is contained a plexus of vessels, the interlobular plexus, and ducts. In some animals, as the pig, the lobules are completely isolated from one another by the



interlobular areolar tissue. If one of the sublobular veins be laid open, the bases of the lobules may be seen through the thin wall of the vein on which they rest, arranged in a form resembling a tessellated pavement, the center of each polygonal space presenting a minute aperture, the mouth of an intralobular vein.

### **Microscopic Appearance of a Lobule**

Each lobule consists of a mass of cells, hepatic cells, arranged in irregular radiating columns between which are the blood channels (*sinusoids*). These convey the blood from the circumference to the center of the lobule, and end in the intralobular vein, which runs through its center, to open at its base into one of the sublobular veins.

Between the cells are also the minute bile capillaries. Therefore, in the lobule there are all the essentials of a secreting gland that is;

- cells, by which the secretion is formed;
- blood vessels, in close relation with the cells, containing the blood from which the secretion is derived;
- ducts, by which the secretion, when formed, is carried away.

**The hepatic cells** are polyhedral in form. They vary in size from 12 to 25 in diameter. They contain one or sometimes two distinct nuclei. The nucleus exhibits an intranuclear network and one or two refractile nucleoli. The cells usually contain granules; some of which are protoplasmic, while others consist of glycogen, fat, or an iron compound. In the lower vertebrates, *e.g.*, frog, the cells are arranged in tubes with the bile duct forming the lumen and blood vessels externally.

**The hepatic blood vessels**, the blood in the capillary plexus around the liver cells is brought to the liver principally by the **portal vein**, but also to a certain extent by the **hepatic artery**. The hepatic artery, entering the liver at the porta with the portal vein and hepatic duct, ramifies with these vessels through the portal canals. It gives off vaginal branches, which ramify in the fibrous capsule of Glisson, and appear to be destined chiefly for the nutrition of the coats of the vessels and ducts. It also gives off capsular branches, which reach the surface of the organ, ending in its fibrous coat in stellate plexuses.

Finally, it gives off interlobular branches, which form a plexus outside each lobule, to supply the walls of the interlobular veins and the accompanying bile ducts. From this plexus lobular branches enter the lobule and end in the net-work of sinusoids between the cells.

**The portal vein** also enters at the porta, and runs through the portal canals enclosed in Glisson's capsule, dividing in its course into branches, which finally break up into a plexus, the interlobular plexus, in the interlobular spaces. These branches receive the vaginal and capsular veins, corresponding to the vaginal and capsular branches of the hepatic artery. Thus it will be seen that all the blood carried to the liver by the portal vein and hepatic artery finds its way into the interlobular plexus. From this plexus the blood is carried into the lobule by fine branches which converge from the circumference to the center of the lobule, and are connected by transverse branches. The walls of these small vessels are incomplete so that the blood is brought into direct relationship with the liver cells. The lining endothelium consists of irregularly branched, disconnected cells (*stellate cells of Kupffer*).

Developmentally they are formed by the growth of the columns of liver cells into large blood spaces or sinuses, and hence they have received the name of —sinusoids. Arrived at the center of the lobule, the sinusoids empty themselves into one vein, of considerable size, which runs down the center of the lobule from apex to base, and is called the intralobular vein. At the base of the lobule this vein opens directly into the sublobular vein, with which the lobule is connected.

The sublobular veins unite to form larger and larger trunks, and end at last in the hepatic veins, these converge to form three large trunks which open into the inferior vena cava while that vessel is situated in its fossa on the posterior surface of the liver.

**The bile ducts** commence by little passages in the liver cells which communicate with canaliculi termed intercellular biliary passages (*bile capillaries*). These passages are merely little channels or spaces left between the contiguous surfaces of two cells, or in the angle where three or more liver cells meet and they are always separated from the blood capillaries by at least half the width of a liver cell. The channels thus formed radiate to the circumference of the lobule, and open into the interlobular bile ducts which run in Glisson's capsule, accompanying the portal vein and hepatic artery. These join with other ducts to form two main trunks, which leave the liver at the transverse fissure, and by their union form the hepatic duct.

**Structure of the Ducts.** The walls of the biliary ducts consist of a connective-tissue coat, in which are muscle cells, arranged both circularly and longitudinally, and an epithelial layer, consisting of short columnar cells resting on a distinct basement membrane.

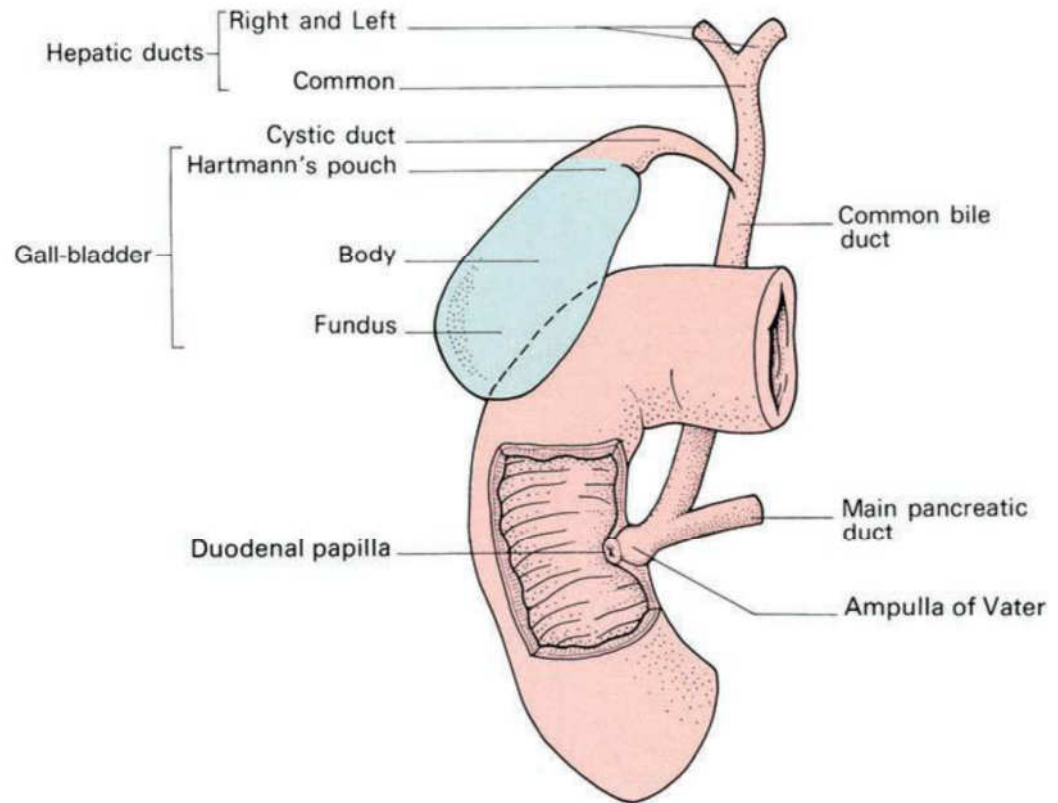
## Excretory Apparatus of the Liver

The excretory apparatus of the liver consists of

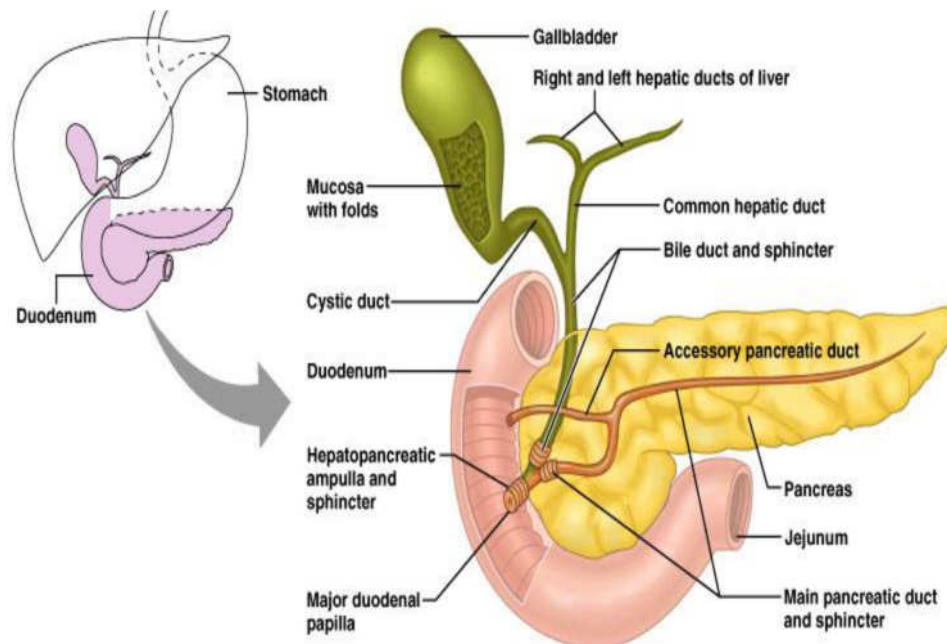
- *the hepatic duct*, formed by the junction of the two main ducts, which pass out of the liver at the porta;
- *the gall-bladder*, which serves as a reservoir for the bile;
- *the cystic duct*, or the duct of the gall-bladder; and
- *the common bile duct*, formed by the junction of the hepatic and cystic ducts.

**The Hepatic Duct** (*ductu shepaticus*).—Two main trunks of nearly equal size issue from the liver at the porta, one from the right, the other from the left lobe; these unite to form the hepatic duct, which passes downward and to the right for about 4 cm., between the layers of the lesser omentum, where it is joined at an acute angle by the cystic duct, and so forms the common bile duct. The hepatic duct is accompanied by the hepatic artery and portal vein.

**The Gall-bladder** (*vesicafellea*): a conical or pear-shaped musculomembranous sac, lodged in a fossa on the under surface of the right lobe of the liver, and extending from near the right extremity of the porta to the anterior border of the organ. It is from 7 to 10 cm. in length, 2.5 cm. in breadth at its widest part, and holds from 30 to 35 cc. It is divided into a fundus, body, and neck. The fundus, or broad extremity, is directed downward, forward, and to the right, and projects beyond the anterior border of the liver; the body and neck are directed upward and backward to the left. The upper surface of the gall-bladder is attached to the liver by connective tissue and vessels. The under surface is covered by peritoneum, which is reflected on to it from the surface of the liver. Occasionally the whole of the organ is invested by the serous membrane, and is then connected to the liver by a kind of mesentery.



**Fig. 4.3:** Gallbladder and its relations



**Fig. 4.4:**

### Relations of the gall bladder

The body is in relation, by its upper surface, with the liver; by its under surface, with the commencement of the transverse colon; and farther back usually with the upper end of the descending portion of the

duodenum, but sometimes with the superior portion of the duodenum or pyloric end of the stomach. The fundus is completely invested by peritoneum; it is in relation, in front, with the abdominal parietes, immediately below the ninth costal cartilage; behind with the transverse colon. The neck is narrow, and curves upon itself like the letter S; at its point of connection with the cystic duct it presents a well-marked constriction.

### Structure of the gall bladder

The gall-bladder consists of three coats: *serous*, *fibromuscular*, and *mucous*.

**The external or serous coat** (*tunica serosa vesicæfelleæ*) is derived from the peritoneum; it completely invests the fundus, but covers the body and neck only on their under surfaces.

**The fibromuscular coat** (*tunica muscularis vesicæfelleæ*), a thin but strong layer forming the frame-work of the sac, consists of dense fibrous tissue, which interlaces in all directions, and is mixed with plain muscular fibers, disposed chiefly in a longitudinal direction, a few running transversely.

**The internal or mucous coat** (*tunica mucosa vesicæfelleæ*) is loosely connected with the fibrous layer. It is generally of a yellowish-brown color, and is elevated into minute rugæ. Opposite the neck of the gall-bladder the mucous membrane projects inward in the form of oblique ridges or folds, forming a sort of spiral valve. The mucous membrane is continuous through the hepatic duct with the mucous membrane lining the ducts of the liver, and through the common bile duct with the mucous membrane of the duodenum. It is covered with columnar epithelium, and secretes mucin; in some animals it secretes a nucleoprotein instead of mucin.

**The Cystic Duct** (*ductus cysticus*). The cystic duct about 4 cm. long, runs backward, downward, and to the left from the neck of the gall-bladder, and joins the hepatic duct to form the common bile duct. The mucous membrane lining its interior is thrown into a series of crescentic folds, from five to twelve in number, similar to those found in the neck of the gall-bladder. They project into the duct in regular succession, and are directed obliquely around the tube, presenting much the appearance of a continuous spiral valve. When the duct is distended, the spaces between the folds are dilated, so as to give to its exterior a twisted appearance.

**The Common Bile Duct** (*ductus choledochus*). The common bile duct is formed by the junction of the cystic and hepatic ducts; it is about 7.5 cm. long, and of the diameter of a goose-quill. It descends along the right border of the lesser omentum behind the superior portion of the duodenum, in front of the portal vein, and to the right of the hepatic artery; it then runs in a groove near the right border of the posterior surface of the head of the pancreas; here it is situated in front of the inferior vena cava, and is occasionally completely imbedded in the pancreatic substance.

At its termination it lies for a short distance along the right side of the terminal part of the pancreatic duct and passes with it obliquely between the mucous and muscular coats. The two ducts unite and open by a common orifice upon the summit of the duodenal papilla, situated at the medial side of the descending portion of the duodenum, a little below its middle and about 7 to 10 cm. from the pylorus. The short tube formed by the union of the two ducts is dilated into an ampulla,

### **Structure of the ampulla of vater**

The coats of the large biliary ducts are an external or fibrous, and an internal or mucous. The fibrous coat is composed of strong fibroareolar tissue, with a certain amount of muscular tissue, arranged, for the most part, in a circular manner around the duct. The mucous coat is continuous with the lining membrane of the hepatic ducts and gall-bladder, and also with that of the duodenum; and, like the mucous membrane of these structures, its epithelium is of the columnar variety. It is provided with numerous mucous glands, which are lobulated and open by minute orifices scattered irregularly in the larger ducts.

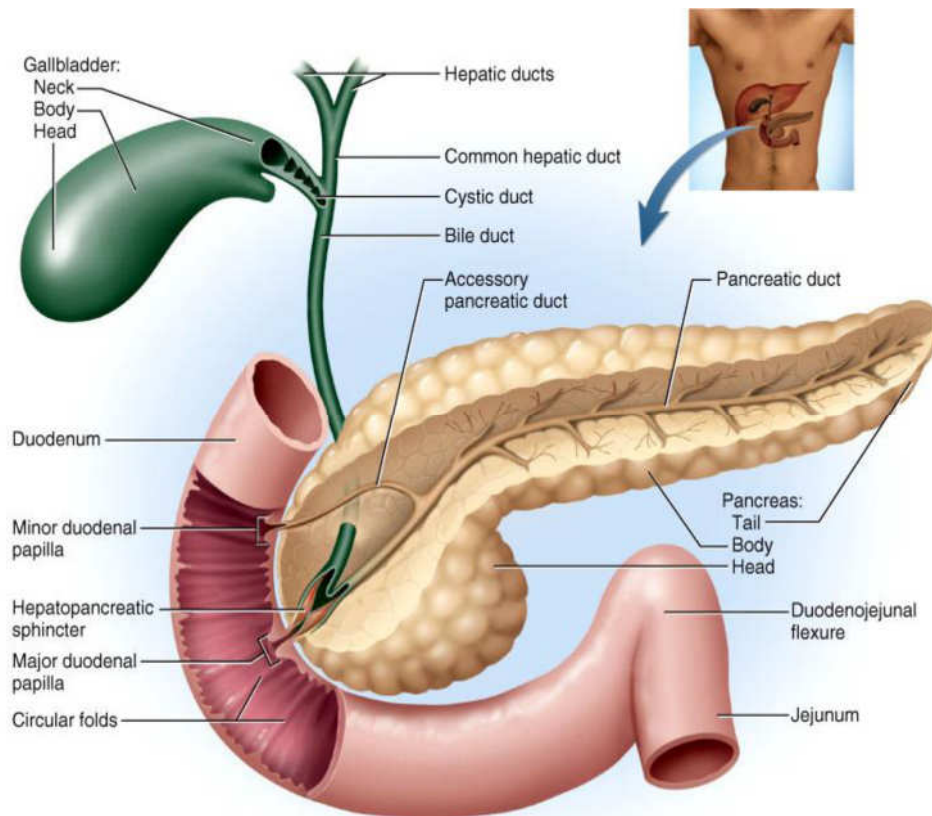
## **3.4 Developmental anatomy of the pancreas**

The pancreas is developed in two parts, a dorsal and a ventral. The former arises as a diverticulum from the dorsal aspect of the duodenum a short distance above the hepatic diverticulum, and, growing upward and backward into the dorsal mesogastrium, forms a part of the head and uncinete process and the whole of the body and tail of the pancreas.

The ventral part appears in the form of a diverticulum from the primitive bile-duct and forms the remainder of the head and uncinete process of the pancreas. About the sixth week the two parts of the pancreas meet and fuse and a communication is established between their ducts. After this has occurred the terminal part of the accessory duct, undergoes little or no enlargement, while the pancreatic duct increases in size and forms the main duct of the gland.

### 3.5 Gross anatomy of the pancreas

A compound racemose gland, analogous in its structures to the salivary glands, though softer and less compactly arranged than those organs. Its secretion, the pancreatic juice, carried by the pancreatic duct to the duodenum, is an important digestive fluid. The pancreas has an important internal secretion, probably elaborated by the cells of Langerhans, which is taken up by the blood stream and is concerned with sugar metabolism. It is long and irregularly prismatic in shape; its right extremity, being broad, is called the head, and is connected to the main portion of the organ, or body, by a slight constriction, the neck; while its left extremity gradually tapers to form the tail. It is situated transversely across the posterior wall of the abdomen, at the back of the epigastric and left hypochondriac regions. Its length varies from 12.5 to 15 cm, and its weight from 60 to 100 gm.



**Fig. 4.5:**

#### Relations

##### **The Head** (*caput pancreatis*)

This is flattened from before backward, and is lodged within the curve of the duodenum. Its upper border is overlapped by the superior part of the duodenum and its lower overlaps the horizontal part; its right and left borders overlap in front, and insinuate themselves behind, the

descending and ascending parts of the duodenum respectively. The angle of junction of the lower and left lateral borders forms a prolongation, termed the uncinata process. In the groove between the duodenum and the right lateral and lower borders in front are the anastomosing superior and inferior pancreaticoduodenal arteries; the common bile duct descends behind, close to the right border, to its termination in the descending part of the duodenum.

**Anterior Surface** The greater part of the right half of this surface is in contact with the transverse colon, only areolar tissue intervening. From its upper part the neck springs, its right limit being marked by a groove for the gastroduodenal artery. The lower part of the right half, below the transverse colon, is covered by peritoneum continuous with the inferior layer of the transverse mesocolon, and is in contact with the coils of the small intestine. The superior mesenteric artery passes down in front of the left half across the uncinata process; the superior mesenteric vein runs upward on the right side of the artery and, behind the neck, joins with the lienal vein to form the portal vein.

**The posterior surface** is in relation with the inferior vena cava, the common bile duct, the renal veins, the right crus of the diaphragm, and the aorta.

**The Neck** springs from the right upper portion of the front of the head. It is about 2.5 cm. long, and is directed at first upward and forward, and then upward and to the left to join the body; it is somewhat flattened from above downward and backward. Its antero-superior surface supports the pylorus; its postero-inferior surface is in relation with the commencement of the portal vein; on the right it is grooved by the gastroduodenal artery.

**The Body** (*corpus pancreatis*) is somewhat prismatic in shape, and has three surfaces: anterior, posterior, and inferior. The anterior surface (*facies anterior*) is somewhat concave; and is directed forward and upward: it is covered by the postero-inferior surface of the stomach which rests upon it, the two organs being separated by the omental bursa. Where it joins the neck there is a well-marked prominence, the tuber omentale, which abuts against the posterior surface of the lesser omentum.

**The posterior surface** (*facies posterior*) is devoid of peritoneum, and is in contact with the aorta, the lienal vein, the left kidney and its vessels, the left suprarenal gland, the origin of the superior mesenteric artery, and the crura of the diaphragm.



**The inferior surface** (*facies inferior*) is narrow on the right but broader on the left, and is covered by peritoneum; it lies upon the duodenojejunal flexure and on some coils of the jejunum; its left extremity rests on the left colic flexure.

**The superior border** (*margo superior*) is blunt and flat to the right; narrow and sharp to the left, near the tail. It commences on the right in the omental tuberosity, and is in relation with the celiac artery, from which the hepatic artery courses to the right just above the gland, while the lienal artery runs toward the left in a groove along this border.

**The anterior border** (*margo anterior*) separates the anterior from the inferior surface, and along this border the two layers of the transverse mesocolon diverge from one another; one passing upward over the anterior surface, the other backward over the inferior surface. The inferior border (*margo inferior*) separates the posterior from the inferior surface; the superior mesenteric vessels emerge under its right extremity.

**The Tail** (*cauda pancreatis*) is narrow; it extends to the left as far as the lower part of the gastric surface of the spleen, lying in the phrenicolienal ligament, and it is in contact with the left colic flexure. On the other hand, the extremity of the pancreas comes in contact with the spleen in such a way that the plane of its upper surface runs with little interruption upward and backward into the concave gastric surface of the spleen, which completes the bed behind and to the left, and, running upward, forms a partial cap for the wide end of the stomach. **The**

**Pancreatic Duct** (*ductus pancreaticus*[*Wirsungi*]; *duct of Wirsung*)

This extends transversely from left to right through the substance of the pancreas. It commences by the junction of the small ducts of the lobules situated in the tail of the pancreas, and, running from left to right through the body, it receives the ducts of the various lobules composing the gland. Considerably augmented in size, it reaches the neck, and turning downward, backward, and to the right, it comes into relation with the common bile duct, which lies to its right side; leaving the head of the gland, it passes very obliquely through the mucous and muscular coats of the duodenum, and ends by an orifice common to it and the common bile duct upon the summit of the duodenal papilla, situated at the medial side of the descending portion of the duodenum, 7.5 to 10 cm. below the pylorus. The pancreatic duct, near the duodenum, is about the size of an ordinary quill. Sometimes the pancreatic duct and the common bile duct open separately into the duodenum. Frequently there is an additional duct, which is given off from the pancreatic duct in the neck of the pancreas and opens into the duodenum about 2.5 cm. above

the duodenal papilla. It receives the ducts from the lower part of the head, and is known as the accessory pancreatic duct (*duct of Santorini*).

### **Vasculature and nerve supply of the pancreas**

**The arteries** of the pancreas are derived from the *lienal*, and the *pancreaticoduodenal* branches of the hepatic and superior mesenteric.

**Its veins** open into the lienal and superior mesenteric veins.

**Innervations** are filaments from the lienal plexus.

### **3.6 Histology of the pancreas**

Pancreas resembles the salivary glands. Difference being in certain particulars and is looser and softer in its texture. It is not enclosed in a distinct capsule, but is surrounded by areolar tissue, which dips into its interior, and connects together the various lobules of which it is composed. Each lobule is tubular and somewhat convoluted. The minute ducts connected with the alveoli are narrow and lined with squamous cells. The alveoli are almost completely filled with secreting cells, so that scarcely any lumen is visible. The true secreting cells are columnar in shape and present two zones: an outer one, clear and finely striated next the basement membrane, and an inner granular one next to the lumen.

The connective tissue between the alveoli presents in certain parts collections of cells, which are termed interalveolar cell islets (*islands of Langerhans*).

The cells of these stain lightly with hematoxylin or carmine, and are more or less polyhedral in shape, forming a net-work in which ramify many capillaries. There are two main types of cell in the islets, distinguished as A-cells and B-cells according to the special staining reactions of the granules they contain.

## **5.0 SUMMARY**

In this unit, you have learnt about the following:

- i. Developmental anatomy of the liver
- ii. Gross anatomy of the liver
- iii. Histology of the liver
- iv. Developmental anatomy of the pancreas
- v. Gross anatomy of the pancreas
- vi. Histology of the pancreas

## 6.0 TUTOR MARKED ASSIGNMENTS

### 6.1 Activity

- i. Describe the liver based on location? List the lobes of the liver and the supporting ligaments.
- ii. Describe the structure of liver lobules and trace the flow of blood and bile in the lobules.

### 6.2 Please answer the following questions

- i. Describe the location, structure, relations, and functions of the liver.
  - ii. Draw an annotated diagram of the Liver
  - iii. Describe the location of the gallbladder and trace the flow of bile through the systems of ducts into the duodenum.
  - iv. Describe the location, structure, and functions of the pancreas.
1. The hepatic sinusoids
    - a. receive blood from the hepatic artery.
    - b. receive blood from the hepatic portal vein.
    - c. empty into the central veins.
    - d. all of the above.
  2. Given these ducts:
    - a. common bile duct
    - b. common hepatic duct
    - c. cystic duct
    - d. hepatic ducts
  3. Choose the arrangement that lists the ducts in the order bile passes through them when moving from the bile canaliculi of the liver to the small intestine.
    - a. 3,4,2
    - b. 3,2,1
    - c. 3,4,1
    - d. 4,1,2
    - e. 4,2,1
  4. Which of these might occur if a person suffers from a severe case of hepatitis that impairs liver function?
    - a. Fat digestion is difficult.
    - b. By-products of hemoglobin accumulate in the blood.
    - c. Plasma proteins decrease in concentration.
    - d. Toxins in the blood increase.

- e. All of the above occur.
5. The gallbladder
- a. stores bile.
  - b. produces bile.
  - c. contracts and releases bile in response to secretin.
  - d. contracts and releases bile in response to sympathetic stimulation.
  - e. both b and c.

## 7.0 REFERENCES AND OTHER RESOURCES

Hutchinson, M., Mallat, J., Marieb, E.N., Wilhelm P.B. (2007). A Brief Atlas of the Human Body. San Francisco: Pearson Education Inc.

Katherine M. A. Rogers and William N. Scott (2011) Nurses! Test Yourself in Anatomy and Physiology

Kathryn A. Booth, Terri. D. Wyman (2008) Anatomy, Physiology, and Pathophysiology for Allied Health

Keith L Moore, Persuade T.V.N (2018), The Developing Human Clinically Oriented Embryology 11th Edition Lippincott Williams & Wilkins

Kent M. Van De Graff, R.Ward Rhee, Sidney Palmer (2010) Schaum's Outline of human Anatomy and Physiology 3rd edition.

Philip Tate (2012) Seeley's Principles of Anatomy & Physiology 2nd ed.

Sadler T.W (2012), Langman's Medical Embryology 12th edition.

Seeley's Principles of Anatomy & Physiology, Second edition Published by McGraw-Hill, a business unit of The McGraw-Hill Companies, Inc., 1221 Avenue of the Americas, New York, NY 10020. Copyright c 2012- Chapter 17&18